




12-2022

## **Evaluation of Ocelot and Bobcat General and Reproductive Health in South Texas and Assessment of Assisted Reproductive Techniques for Wild Felid Conservation**

Ashley Reeves  
areeves9@vols.utk.edu

Follow this and additional works at: [https://trace.tennessee.edu/utk\\_graddiss](https://trace.tennessee.edu/utk_graddiss)

 Part of the [Other Veterinary Medicine Commons](#), [Veterinary Infectious Diseases Commons](#), and the [Veterinary Physiology Commons](#)

---

### **Recommended Citation**

Reeves, Ashley, "Evaluation of Ocelot and Bobcat General and Reproductive Health in South Texas and Assessment of Assisted Reproductive Techniques for Wild Felid Conservation. " PhD diss., University of Tennessee, 2022.  
[https://trace.tennessee.edu/utk\\_graddiss/7633](https://trace.tennessee.edu/utk_graddiss/7633)

This Dissertation is brought to you for free and open access by the Graduate School at TRACE: Tennessee Research and Creative Exchange. It has been accepted for inclusion in Doctoral Dissertations by an authorized administrator of TRACE: Tennessee Research and Creative Exchange. For more information, please contact [trace@utk.edu](mailto:trace@utk.edu).

To the Graduate Council:

I am submitting herewith a dissertation written by Ashley Reeves entitled "Evaluation of Ocelot and Bobcat General and Reproductive Health in South Texas and Assessment of Assisted Reproductive Techniques for Wild Felid Conservation." I have examined the final electronic copy of this dissertation for form and content and recommend that it be accepted in partial fulfillment of the requirements for the degree of Doctor of Philosophy, with a major in Comparative and Experimental Medicine.

Debra L. Miller, Major Professor

We have read this dissertation and recommend its acceptance:

Brian K. Whitlock, Maria Spriggs, Michael E. Tewes, Clayton D. Hilton, William F. Swanson

Accepted for the Council:

Dixie L. Thompson

Vice Provost and Dean of the Graduate School

(Original signatures are on file with official student records.)

**Evaluation of Ocelot and Bobcat General and Reproductive Health in South  
Texas and Assessment of Assisted Reproductive Techniques for Wild Felid  
Conservation**

**A Dissertation Presented for the  
Doctor of Philosophy  
Degree  
The University of Tennessee, Knoxville**

**Ashley M. Reeves**

**December 2022**

Copyright © 2022 by Ashley M. Reeves.  
All rights reserved.

## Acknowledgements

I would like to thank my advisor Dr. Debra Miller for her continual support throughout veterinary school and my dissertation. She has been a constant resource, friend, and leader as a woman in wildlife and I look forward to continuing to work with her throughout my career. I would also like to thank my committee for taking time to share immense knowledge, setting high expectations, and supporting me as I grew throughout this process to be the researcher, veterinarian, and leader I am today; and specifically, a particular thank you to Dr. Bill Swanson who traveled numerous hours and spent infinite time training me and entertaining my endless questions, humor, and amazing music selections. A special thank you to Dr. Lindsay Vansandt and Amy Miller at the Lindner Center for Conservation and Research of Endangered Wildlife. While they did not serve on my committee, they consistently answered many emails and phone calls (sometimes even late at night or while in the field), taught me numerous laboratory techniques and ultimately are great friends and colleagues. I'd also like to thank all of our collaborators, field technicians, volunteers, and graduate students over the past three years with a special thanks to the East Foundation and the Feline Research Program at the Caesar Kleberg Wildlife Research Institute (Texas A&M University-Kingsville); and specifically, a special thanks to Dr. Clayton Hilton for all of his work to make this project possible. A special thanks to Berenise Valles, Yessenia Garza, Eve Schrader, Colleen Farrell, and Dr. Jerry and Carolyn Underbrink for making this journey one I will never forget and being my family away from home. I'd especially like to thank Landon Schofield for his constant support in the field and friendship throughout the last three years which kept me sane many times. I'd like to thank my parents and sister, Robert and Lisa Reeves and Jennifer Burlingame, for their constant encouragement to continue despite difficulties, dream big, and stay true to who I am. Finally, I'd like to thank my husband, Rodney Wilmoth, for being the most supportive when I am constantly on the move, bring work home with me, ask him to partake in many feline reproductive adventures, and for gifting me my dog Charlie who is my best friend and greatest companion when I'm away from home. Last, but definitely not least, I am thankful God granted me patience, rather than strength; as with strength, I may have choked somebody along the way.

## Abstract

Recent studies of wild felid populations in southern Texas have shown loss of genetic variability and inbreeding depression over time, increasing the risk of reduced reproductive and immune fitness leading to an overall decrease in reproductive success, increase in disease susceptibility, and further population demise. Assessment of general health, pathogen exposure, and reproductive health can provide documentation of the possible effects of inbreeding and inform the development of conservation strategies. Assisted reproductive technologies have been used in many other species and can address behavioral or physical incompatibilities among breeding pairs, connect distant populations by transporting frozen gametes, preserve genetic diversity within liquid nitrogen tanks and link wild and human-managed populations without the movement of individuals. The main goals of this study were to: (1) determine the general and reproductive health status and pathogen prevalence of free-ranging ocelot and bobcat populations in south Texas, given the concern for the impact of declining genetic diversity on population health, (2) compare the effectiveness of urethral catheterization (UC) and ultra-rapid freezing (URF) to traditional cryopreservation methods as a field-friendly semen collection and cryopreservation combination, and (3) assess the use of laparoscopic oviductal artificial insemination (LO-AI) in human-managed ocelot females with semen from wild Texas males to explore the feasibility of this approach to facilitate ocelot pregnancies. While our populations did not show declines in general health, reproductive health parameters of wild ocelots were inferior to human-managed ocelot populations and bobcats exhibited low overall semen quality similar to other *Lynx* species. We found that UC collected samples were consistently damaged by urine contamination for ocelots and that electroejaculation with straw freezing was superior. For bobcats, while UC and URF appeared adequate, electroejaculation would need to be further explored. No pregnancies (0/5) have been produced in ocelots by LO-AI using frozen-thawed semen thus far; however, eventual success with this technique will allow the use of minimal sperm numbers to promote gene flow among isolated populations and re-establish extirpated populations with genetically diverse individuals. Further assessment of bobcat sperm viability *in vivo* will be required to demonstrate the practicality of these methods for future conservation initiatives.

# Table of Contents

Introduction.....	1
References.....	4
<b>Chapter I: Assessment of general health status and pathogen prevalence in free-ranging ocelot (<i>Leopardus pardalis</i>) and bobcat (<i>Lynx rufus</i>) populations of south Texas .....</b>	<b>7</b>
Abstract.....	8
Introduction .....	9
Materials and Methods .....	12
Results .....	16
Discussion .....	24
References .....	30
Appendix 1 .....	46
<b>Chapter II: Urethral catheterization of free-ranging ocelots (<i>Leopardus pardalis</i>) and bobcats (<i>Lynx rufus</i>) in southern Texas for semen collection and characterization of normative seminal traits.....</b>	<b>48</b>
Abstract.....	49
Introduction .....	50
Materials and Methods .....	52
Results .....	57
Discussion .....	60
References .....	68
Appendix 2 .....	80
<b>Chapter III: Assessment of ultra-rapid freezing as a simplified, field-friendly technique for long-term storage of spermatozoa in ocelots (<i>Leopardus pardalis</i>) and bobcats (<i>Lynx rufus</i>) in southern Texas .....</b>	<b>82</b>
Abstract.....	83
Introduction .....	83
Materials and Methods .....	86

Results .....	91
Discussion .....	92
References .....	100
<b>Chapter IV: Laparoscopic oviductal artificial insemination with frozen semen for conservation management of endangered ocelots in southern Texas .....</b>	<b>107</b>
Abstract .....	108
Introduction .....	108
Materials and Methods .....	112
Results .....	117
Discussion .....	117
References .....	124
Conclusion .....	134
References.....	138
Vita.....	144



## List of Tables

Table 1.1: Biochemical reference intervals for free-ranging ocelots and bobcats in southern Texas .....	19
Table 1.2: Hematology reference intervals for free-ranging ocelots and bobcats in southern Texas .....	19
Table 1.3: Pathogen prevalence over time for ocelots and bobcats from 1985 to 2022 .....	20
Table 1.4: Significant differences in blood analytes based on test results for each species .....	20
Table 1.5: Endo- and ectoparasite identification from free-ranging ocelots and bobcats from south Texas from 2019-2022 .....	23
Table 2.1: Mean ( $\pm$ SEM) and median (minimum-maximum) values for seminal traits in two wild felid species .....	67
Table 3.1: Mean ( $\pm$ SEM) values for pre-freeze seminal traits in samples processed for cryopreservation.....	99
Table 3.2: Cleavage percentage 48 hours post-insemination of domestic cat oocytes (mature only) with non-domestic cat sperm cryopreserved by ultra-rapid freezing or straw freezing .....	99
Table 4.1: Pre-freeze and post-thaw seminal traits of Texas ocelots .....	123
Table 4.2: Laparoscopic oviductal artificial insemination (LO-AI) procedures and outcomes ..	123

## List of Figures

Figure 1.1: Intestinal parasite ova and arthropods detected in free-ranging ocelot and bobcat fecal samples from 2019- 2022 in southern Texas, USA .....	22
Figure 1.2: Ectoparasites detected in free-ranging ocelots and bobcats .....	24
Figure 2.1: Testicular parameters, penile morphology, and urethral catheterization .....	63
Figure 2.2: Normal and abnormal sperm morphology documented in ocelots and bobcats .....	63
Figure 2.3: Acrosomal staining and classification .....	68
Figure 2.4: Unilateral cryptorchidism and persistent penile frenulum in a bobcat.....	68
Figure 3.1: Classification of cumulus oocyte complexes (COCs).....	97
Figure 3.2: Classification of oocytes and embryos .....	98
Figure 3.3: Percentage of intact acrosomes, percent progressive motility, and forward progressive motion over time for bobcats and ocelots comparing two semen cryopreservation techniques... ..	100
Figure 4.1: Laparoscopic oviductal artificial insemination procedure .....	122
Figure 4.2: Fecal progesterone profiles of female ocelots .....	124

## Introduction

Ocelots (*Leopardus pardalis*) currently reside in the United States in two, small populations with a total of 60-80 cats surviving in the dense thorn scrub of southern Texas [1-3]. Historically, the ocelot's distribution in the United States consisted of Arizona, Arkansas, Louisiana, and Texas [4]; however, Texas ocelots have declined considerably throughout their range due to habitat fragmentation and loss, resulting in low population numbers, limited connectivity, and declines in genetic diversity compared to ocelot populations in Latin American countries [5-6]. In the 1980's, the US Fish and Wildlife Service and Texas Parks and Wildlife Department, listed the ocelot (*Leopardus pardalis*) as endangered, despite other ocelot subspecies being common in parts of Central and South America [5,7]. The nearest known ocelot populations relative to the two remaining populations in Texas exist to the south in the State of Tamaulipas, Mexico and are believed to be larger and less fragmented [1]. The strong habitat selection of ocelots for dense thorn shrub, and avoidance of areas with less than 75% canopy cover, is thought to reduce movement between relatively close habitat patches [8], which further decreases the chance for genetic exchange and increases the likelihood of inbreeding depression. Another medium sized felid, the bobcat (*Lynx rufus*), can be found extending from southern Canada to northern Mexico and throughout the US [9]. Although listed as a species of least concern according to the International Union for Conservation of Nature (IUCN) Red List of Threatened Species [10], loss of habitat is an increasing threat to some populations, making conservation initiatives for this species important for future survival in the wild.

Reduction in genetic variation among wild felids has the potential to decrease the average individual fitness in each population, a phenomenon termed "inbreeding depression" [11]. Inbreeding depression affects offspring fertility and offspring survival, potentially increasing susceptibility to pathogens such as viruses, bacteria, and parasites [12-15]. Furthermore, genetic drift can contribute to reduction in fitness through the fixation of detrimental alleles [16]. Genetic drift and inbreeding compromise fitness and interact with demographic irregularity to further reduce viability of populations [16-18]. Texas ocelot populations are especially at risk of inbreeding depression and genetic drift due to the separation into two distant breeding populations, which have had no documented dispersal between the two in the past 30 years [3]. Studies have illustrated a decrease in mitochondrial and microsatellite markers in Texas populations, especially in the population at Laguna Atascosa National Wildlife Refuge

(LANWR) [6] and have documented signs of inbreeding depression and decreased genetic variability in Texas ocelot populations [1,6,19]. Additionally, computer modeling indicates that the ocelot is at risk of extinction in the US within the next few decades due to low genetic diversity, restricted gene flow between populations, and limited connectivity to other ocelot populations due to habitat fragmentation [3].

The effects of inbreeding vary among species and may be due to different mean levels of inbreeding depression over time [16]. To combat inbreeding depression, dispersal between genetically different wild populations is critical. An alternative solution is translocation of individuals between populations and/or the use of assisted reproductive technologies to move genetic material rather than entire individuals. Introduction of individuals from different populations or captive bred populations has the potential to introduce pathogens to naïve populations.

Proposed Texas ocelot population recovery actions include protecting and restoring ocelot habitat, introducing genetic variation into the existing population, development of a captive breeding program to establish new ocelot populations, creating a biological resource bank, and developing assisted reproductive technologies (ART) for artificial insemination [20-21]. ART can be used in many species to address behavioral or physical incompatibilities among genetically suitable breeding pairs, connect regional populations by transporting frozen semen and embryos, preserve genetic diversity using liquid nitrogen tanks, and link wild and human-managed populations without removing animals from the wild [20]. ART is currently used for management of ocelot populations in zoos. Brazilian and generic ocelot populations in managed care have benefitted from the development of ART to optimize genetic exchange and demographic stability and contributed to scientific knowledge of the species.

The objectives of this study were similar in methodology but differed in purpose for each species. For ocelots, we aimed to 1) assess the general health and pathogen prevalence of the resident population in southern Texas at present and over time, 2) examine the feasibility of a new method of semen collection (urethral catheterization) to assess the reproductive health of free-ranging male ocelots in southern Texas as related to other genetically diverse populations, 3) compare two semen cryopreservation techniques to determine the best method for long-term storage of free-ranging ocelot spermatozoa in liquid nitrogen, and 4) evaluate the success of laparoscopic oviductal artificial insemination using frozen-thawed wild ocelot sperm for future

propagation of the species and introduction of novel genetics to imperiled populations. For bobcats, we aimed to 1) assess the general health and pathogen prevalence of the population at present and over time, 2) describe the reproductive health and normative seminal traits of free-ranging bobcats for the first time and compare findings to ocelots and other species of the *Lynx* genus, and 3) compare two sperm cryopreservation techniques to determine the best method for long-term storage should this population experience declines in the future like many other felid species.

The following dissertation is organized accordingly to answer our objectives. We first sought to determine and describe the general and reproductive health of these populations to understand the possible impact that declining genetic diversity may play on the general health and reproductive success of inbred populations. Following health assessments, we investigated the use of established assisted reproductive techniques to determine the best methods for semen collection and cryopreservation in free-ranging felids for the storage of genetic diversity, creation of a genetic resource bank, and future utilization of these samples for the conservation of wild felids. Lastly, we sought to assess the efficacy of cryopreserved samples for in vivo laparoscopic artificial insemination procedures in ocelots as a valuable tool to mitigate the genetic decline seen in wild populations and as a recovery option for imperiled US populations without the sole reliance on the translocation of individuals.

## References

- [1] J.E. Janečka, M.E. Tewes, L.L. Laack, L.I. Grassman Jr, A.M. Haines, R. Honeycutt. Small effective population sizes of two remnant ocelot populations (*Leopardus pardalis albescens*) in the United States. *Conserv Genet.* 9:4 (2008) 869-878. <https://doi.org/10.1007/s10592-007-9412-1>.
- [2] A.M. Haines, J.E. Janecka, M.E. Tewes, L.I. Grassman Jr, P. Morton. The importance of private lands for ocelot (*Leopardus pardalis*) conservation in the United States. *Oryx.* 40:1 (2006) 90-94. <https://doi.org/10.1017/S0030605306000044>
- [3] A.M. Haines, M.E. Tewes, L.L. Laack, W.E. Grant, J. Young. Evaluating recovery strategies for an ocelot (*Leopardus pardalis*) population in the united states. *Biol Conserv.* 126:4 (2005) 512-522. <https://doi.org/10.1016/j.biocon.2005.06.032>
- [4] J.L. Murray, G.L. Gardner. *Leopardus pardalis* mammal. *Species* 548 (1997) 10– 17.
- [5] A. Paviolo, P. Crawshaw, A. Caso, T. de Oliveira, C.A. Lopez-Gonzalez, M. Kelly, C. De Angelo, E. Payan. *Leopardus pardalis* (errata version published in 2016). *The IUCN Red List of Threatened Species* 2015: e.T11509A97212355. <https://dx.doi.org/10.2305/IUCN.UK.2015-4.RLTS.T11509A50653476.en>. Accessed on 06 January 2022.
- [6] J.E. Janečka, M.E. Tewes, L.L. Laack, A. Caso, L.I. Grassman Jr, A.M. Haines, D.B. Shindle, B.W. Davis, W.J. Murphy, R.L. Honeycutt. Reduced genetic diversity and isolation of remnant ocelot populations occupying a severely fragmented landscape in southern Texas. *Anim Conserv.* 14:6 (2011) 608-619. <https://doi-org.utk.idm.oclc.org/10.1111/j.1469-1795.2011.00475.x>
- [7] U.S. Fish and Wildlife Service. 2010. Draft Ocelot (*Leopardus pardalis*) Recovery Plan, First Revision. S. Fish and Wildlife Service, Southwest Region, Albuquerque, New Mexico.
- [8] J.S. Horne, A.M. Haines, M.E. Tewes, L.L. Laack. Habitat partitioning by sympatric ocelots and bobcats: implications for recovery of ocelots in southern Texas.(Report). *Southwestern Naturalist.* 54:2 (2009) 119-126. <https://doi-org.utk.idm.oclc.org/10.1894/PS-49.1>
- [9] S. Larivière, L.R. Walton. *Lynx rufus*. *Mammalian Species.* 563 (1997) 1-8.

- [10] M. Kelly, D. Morin, C.A. Lopez-Gonzalez. *Lynx rufus*. *The IUCN Red List of Threatened Species* 2016: e.T12521A50655874. <https://dx.doi.org/10.2305/IUCN.UK.2016-1.RLTS.T12521A50655874.en>. Accessed on 06 January 2022.
- [11] D. Charlesworth, J.H. Willis. The genetics of inbreeding depression. *Nature Reviews. Genet.* 10:11 (2009) 783–796. <https://doi.org/10.1038/nrg2664>
- [12] P.M. Brock, S.J. Goodman, A.J. Hall, M. Cruz, K. Acevedo-Whitehouse. Context-dependent associations between heterozygosity and immune variation in a wild carnivore. *BMC Evolutionary Biology*, 15:241 (2015) 242–242. <https://doi.org/10.1186/s12862-015-0519-6>
- [13] D.W. Coltman, J.G. Pilkington, J.A. Smith, J.M. Pemberton. Parasite-mediated selection against Inbred Soay sheep in a free-living island population. *Evolution*. 53:4 (1999) 1259-1267.
- [14] M. Hasselgren, K. Norén. Inbreeding in natural mammal populations: historical perspectives and future challenges. *Mammal Review*. 49:4 (2019) 369–383. <https://doi.org/10.1111/mam.12169>
- [15] D. Spielman, B.W. Brook, D.A. Briscoe, R. Frankham. Does inbreeding and loss of genetic diversity decrease disease resistance? *Conserv Genet.* 5:4 (2004) 439–448. <https://doi.org/10.1023/B:COGE.0000041030.76598.cd>
- [16] P.W. Hedrick, S.T. Kalinowski. Inbreeding depression in conservation biology. *Annu Rev Ecol Syst.* 31:1 (2000) 139-162. <https://doi.org/10.1146/annurev.ecolsys.31.1.139>
- [17] D.H. Reed. Relationship between population size and fitness. Relación entre tamaño poblacional y adaptabilidad. *Conserv Biol.* 19:2(2005) 563-568. <https://doi-org.utk.idm.oclc.org/10.1111/j.1523-1739.2005.00444.x>
- [18] D.H. Reed, A.C. Nicholas, G.E. Stratton. Genetic quality of individuals impacts population dynamics. *Anim Conserv.* 10:3 (2007) 275-283. <https://doi-org.utk.idm.oclc.org/10.1111/j.1469-1795.2007.00120.x>.
- [19] J.E. Janecka, M.E. Tewes, L. Laack, A. Caso, L.I. Grassman, R.L. Honeycutt. Loss of genetic diversity among ocelots in the United States during the 20th century linked to human induced population reductions. *Plos One*. 9:2 (2014) e89384. <http://dx.doi.org/10.1371/journal.pone.0089384>.

[20] W.F. Swanson. Application of assisted reproduction for population management in felids: the potential and reality for conservation of small cats. *Therio*. 66 (2006) 49–58.  
<https://doi.org/10.1016/j.theriogenology.2006.03.024>.

[21] E. Sprague. Ocelot recovery through forest restoration. American Forests.  
<https://www.americanforests.org/article/ocelot-recovery-through-forest-restoration/>.



**Chapter I: Assessment of general health status and pathogen prevalence in free-ranging ocelot (*Leopardus pardalis*) and bobcat (*Lynx rufus*) populations of south Texas**

## Abstract

Wild felid populations in southern Texas have shown signs of decreased genetic diversity and inbreeding depression over the last few decades. Declining immune fitness due to loss of genetic heterozygosity can allow for increased susceptibility to pathogens and diseases. Our primary objectives in this study were to determine the general health and pathogen prevalence of free-ranging ocelots and bobcats by evaluating hematologic values (complete blood counts/biochemical profiles), parasite loads (fecal exams, ectoparasite identification), and pathogen presence (viral/bacterial assays) to investigate the possible effect of decreased genetic diversity on wild felid populations of southern Texas and to provide baseline data for future comparisons. Blood smear analysis, and serum and whole blood testing for evidence of viral, vector-borne, and blood-borne pathogens were conducted on 80 felids (ocelots, n=31; bobcats, n=49) spanning 35 years (1985-1986, 2010-2012, 2019-2022). Hematologic and biochemical values did not vary based on sex and, while some values were similar to previous reports for ocelots and bobcats, values did not consistently agree with reports for human-managed or other free-ranging populations. Positive serological results were found for Feline Immunodeficiency Virus (FIV) (18/80; 22%), *Trypanosoma cruzi* (4/80; 5%), and *Toxoplasma gondii* (46/80; 57.5%). Positive PCR results were found for *Ehrlichia* spp. (2/80; 2.5%), *Hepatozoon* spp. (32/80; 40%), and *Leishmania* spp. (2/80; 2.5%) with a higher prevalence in males for most pathogens. Clinical signs of disease were not observed in any individual suggesting subclinical infection, recovery from prior episode of clinical disease, or lack of susceptibility to disease. The most common intestinal parasites were *Toxascaris leonina* (roundworm) and an unknown *Ancylostomid* spp. (hookworm), while the most common ectoparasites were ticks (*Dermacentor variabilis*) and fleas (*Pulex* spp). Increases in prevalence over time were observed for two pathogens (*Leishmania* spp. and *Ehrlichia* spp.), suggesting the emergence of these pathogens within these populations in recent years, increased susceptibility to these pathogens due to genetic decline, or a lack of statistical power in low sample numbers from previous years. These findings provide a better understanding of the population's general health and assist wildlife managers in planning strategies that aid in reducing or preventing transmission of infectious disease agents to these endangered populations.

## Introduction

Although ocelots are a species of “least concern” on the International Union for Conservation of Nature (IUCN) Red list, Texas ocelot (*Leopardus pardalis*) populations remain listed in the Environmental Conservation Online System (ECOS) under the Endangered Species Act (ESA) as endangered and have experienced dramatic declines and decreased genetic diversity due to isolation [1-4]. There are two geographically distinct breeding populations of ocelots in the United States that reside in southern Texas: Laguna Atascosa National Wildlife Refuge (LANWR) population and a population of ocelots residing on private ranches in Willacy and Kenedy counties [5-6]. The decrease in population numbers is thought to be due to mortality from vehicle collisions, natural disasters, reduced fitness, competitive suppression with other resident predators, and loss of habitat [2, 7-8]. These sources of mortality are thought to stem from habitat fragmentation due to urbanization, such as the building of highways [1, 9-10] and interspecific competition for resources with other large predators such as bobcats (*Lynx rufus*) and coyotes (*Canis latrans*) [11-13]. In turn, condensed ocelot population size has continually reduced genetic variation within those populations [10, 14]. A reduction in genetic variation has also been reported for bobcat populations in Texas, although there has not been a documented decline in their population size [9]. It is theorized that this is due to anthropogenic influences creating physical divides and splitting larger populations into multiple smaller ones, similar to ocelots [9-10].

The reduction in genetic variation among wild felids has the potential to decrease fitness at an individual level and within the population as a result of inbreeding depression [15]. Dispersal between genetically different populations is critical to combat inbreeding depression. Due to habitat fragmentation, natural dispersal between the two ocelot populations in Texas has not been documented in the last few decades and is unlikely in the future. Alternative solutions include translocation of individuals between populations and/or the use of assisted reproductive technologies to introduce novel genetics into imperiled populations. These actions demonstrate the importance of general health monitoring and pathogen testing in order to decrease the possibility of disease spread and further population demise. Additionally, assessment of health parameters over time can provide important information regarding the impact of declining genetic diversity on the health of remaining populations. Non-domestic felines have been

reported to be susceptible to all pathogens, such as viral, parasitic, and bacterial, that have the ability to infect domestic feline species [16].

Two viral pathogens of concern for transmission among and between feline species are Feline Leukemia Virus (FeLV) and Feline Immunodeficiency Virus (FIV). Feline Leukemia Virus is a gamma retrovirus [17] that can be transmitted vertically to kittens and horizontally between other adult cats [18]. While FeLV is rarely diagnosed in non-domestic feline species [19], most cases have been reported in human-managed individuals that have been exposed to infected domestic felines [20-21], and the only wild species known to have endemic FeLV in their populations is the European wildcat [22]. Additionally, FeLV has been found in other non-domestic free-ranging feline populations including mountain lions (*Puma concolor*) [23], Iberian lynx (*Lynx pardinus*) [24], and guigna (*Leopardus guigna*) [25].

Feline Immunodeficiency Virus is a lentivirus [26] that has variable prevalence in domestic and non-domestic cat populations across the world [19, 25-28]. The virus is primarily transmitted through bite wounds but can be spread in the absence of fighting in immunosuppressed individuals and has been experimentally transmitted from mother to kitten [18]. Most infectious strains of FIV are considered species-specific [29] and tend to be grouped due to geographic patterns rather than relation of the affected species [30]. Cross-species transmission has been reported [30-31], but is rare and most instances are documented in captive settings where risk of contact with other felids is higher [30].

A zoonotic parasite of concern is *Toxoplasma gondii*. Toxoplasmosis is the disease caused by infection with *T. gondii* [32-33]. The definitive hosts include all members of the family Felidae, and any warm-blooded animal can be an intermediate host, including humans [32-33]. Transmission of *T. gondii* can occur horizontally through ingestion of infected undercooked animal tissue, and contaminated water or food [34-35], and vertically, through transplacental and lactogenic infection [33-34].

Various vector-borne pathogens, such as those transmitted by ticks, triatomine bugs, and sand flies, have been identified in many mammalian species and although they may not cause significant disease in certain animals, many carry zoonotic concerns for the humans that work with them [36]. *Trypanosoma cruzi*, a pathogen endemic in the southern half of the US [37-38], is transmitted by the triatomine bug vector causing Chagas disease in various mammalian species. Two non-domestic cat species, ocelots and pumas (*Puma concolor*) have been reported

seropositive for *T. cruzi* [39-40] and infection rates were shown to increase with the number of vertebrate species present in the diet [41].

Several tick-borne pathogens have been documented in the United States or surrounding countries and many have the potential to infect not only feline species, but humans as well. A few pathogens of concern include *Ehrlichia* spp., *Rickettsia* spp., *Anaplasma* spp., *Hepatozoon* spp., *Babesia* spp., and *Leishmania* spp. Various tick vectors have been identified in the transmission of these pathogens to humans and animals worldwide [42-43] although some vectors still remain unknown [43]. Most of these vector-borne pathogens do not produce clinical disease in cats, the pathogenesis has not been described in feline species [36]. Opportunistic screening of wild animals for these pathogens can aid in detecting the introduction of a novel pathogen or the spread of emerging diseases. Furthermore, most tick-borne illnesses present with similar clinical signs, making testing crucial to discern the causative agent(s) of disease and especially important when translocating individuals from countries with endemic disease to a country with no known detection of such disease, pathogen, or vector of causative agents.

Leishmaniosis (leishmaniasis) is a chronic, protozoal disease of humans, canines, and other animals transmitted by the bite of an infected sand fly [44]. This disease is prevalent in Africa, Central and South America, the Middle East, Asia and the Mediterranean [44-46] and only occasionally reported in the United States [47-49]. While rare in domestic cats, debilitating skin disease has been described [44, 46, 50]. Factors predisposing individuals to susceptibility include immunosuppression secondary to FIV, FeLV, or other disorders/diseases causing immune decline [50]. In non-domestic felines, reports of infection and exposure have been documented in wild cats (*Felis silvestris*) in Spain [51-52] and sand cats (*Felis margarita*) in Saudi Arabia [53].

Ocelot and bobcat populations in southern Texas share habitat borders with local communities reported to have large numbers of free-ranging, feral domestic cats. This increases the concern for transmission of various pathogens among domestic cats, bobcats and ocelots which could negatively impact endangered ocelot populations. The goals of this study were to determine the general health of ocelot and bobcat populations in southern Texas by performing complete blood counts, serum biochemical analysis, and examining intestinal parasite and ectoparasite infections of individuals live-captured for research from 2019-2022. Additionally, we used archived blood samples from ocelots and bobcats captured in southern Texas from

1985- 2022 to conduct pathogen testing to document changes in prevalence over time given the documented decline over time in genetic diversity of the Texas ocelot populations.

## **Materials and Methods**

### *Animals and Sample collection*

Free-ranging felids were captured using modified Tomahawk traps (Tomahawk Live Trap Co., Tomahawk , Wisconsin, USA) on private ranches in Willacy and Kenedy counties in southern Texas and the Laguna Atascosa National Wildlife Refuge (LANWR). A separate hardware cloth extension measuring 51 cm X 38 cm X 51 cm was added to the trap to contain a live pigeon or small chicken that was provided water and feed ad libitum. Birds were used as visual lures and the cat was unable to capture the live pigeon or chicken. Traps were checked each morning following sunrise to ensure release of captured animals by early to mid-afternoon. All felids were immobilized and maintained at a light anesthetic plane of anesthesia using an injectable combination of ketamine hydrochloride (target dose: 5-8 mg/kg bodyweight; Wedgewood Pharmacy: Wildlife Pharmaceuticals, Inc. and ZooPharm, Swedesboro NJ) and medetomidine (target dose: 0.05-0.07 mg/kg bodyweight; Wedgewood Pharmacy: Wildlife Pharmaceuticals, Inc. and ZooPharm, Swedesboro NJ) given intramuscular via pole syringe. Fasting prior to the anesthetic event was not possible due to the free-ranging nature of the target species. Body condition score was recorded on a zero (emaciation) to five (obese) scale interpreted from guidelines put forth by the Felid Taxon Advisory Group and AZA Nutrition Advisory Group (<https://nagonline.net/3877/body-condition-scoring/>). Body temperature, heart rate, respiratory rate, pulse oximetry, jaw tone, and capillary refill time were monitored throughout the procedures. Venipuncture was completed via the jugular, cephalic, femoral and/or saphenous veins. Blood samples were divided into EDTA tubes for complete blood count assessment and non-additive red top serum tubes for chemistry analysis. Fecal samples were collected from the live box trap or by passing a lubricated fecal loop (approximately 1.91 cm in diameter) approximately 5.08 to 10.16 cm into the rectum, rotating and removing the loop. Fecal samples were divided into cryovials for storage and ~ 1 gram of feces placed in 30 ml of formalin for later fecal examination. All visible ectoparasites were collected with forceps and placed into alcohol for preservation and later identification. Sites of ectoparasite collection include the ears, perianal region, nape of the neck and full body visual scan was performed for

additional ectoparasites. Each felid received 10-20 mL per kg body weight of lactated ringer's solution subcutaneously between the shoulder blades during the procedures. Abdominal ultrasonography was performed for each female using the IBEX PRO® (E.I. Medical Imaging) for pregnancy status. At the conclusion of the procedure, we administered intramuscular atipamezole (dose: 5 mg of atipamezole per 1 mg of medetomidine ; Wedgewood Pharmacy: Wildlife Pharmaceuticals, Inc. and ZooPharm, Swedesboro NJ) to antagonize the effects of the medetomidine. All animal use was approved by and in accordance with the policies of the Institutional Animal Care and Use Committee (IACUC) at Texas A&M University- Kingsville (TAMUK), Caesar Kleberg Wildlife Research Institute (CKWRI), and the University of Tennessee- Knoxville and the study was permitted by the United States Fish and Wildlife Service (USFWS).

#### *Complete Blood Count and Biochemical Analysis*

Serum tubes were allowed to clot for a minimum of 20 minutes, centrifuged for 10 minutes at 1,968 g once returned to the laboratory, and the serum was removed for serum chemistry analysis. Chemistry analysis was completed using the IDEXX Catalyst One Chemistry Analyzer and a Chem 10 CLIP (IDEXX Laboratories, Inc., Westbrook, Maine USA). Complete blood count analysis was performed using the IDEXX Procyte DX Hematology Analyzer (IDEXX Laboratories, Inc., Westbrook, Maine USA) using whole blood in EDTA. Chemistry analysis and complete blood counts were completed on the day of or within 1-3 days of collection. Serum and whole blood remained refrigerated at 4°C until chemistry analysis and complete blood count could be performed. All reagents and controls were purchased from IDEXX Laboratories, Inc. Two blood smears were created per individual: one stained with Diff Quik (Jorgensen Laboratories, Inc. Loveland, CO, USA) and the other remained unstained. Differential counts were performed on stained blood smears under 1000X oil immersion using a biological compound microscope. Blood smears were assessed for platelet number by taking the average number of platelets in five microscopic fields and multiplying them by 15,000 and 20,000 for a platelet range estimate. The remainder of the serum and whole blood were frozen at -40 °C for pathogen testing.

## *Pathogen Testing*

Whole blood was used to test for feline leukemia virus and feline immunodeficiency virus using IDEXX Feline Leukemia Virus Antigen-Feline Immunodeficiency Virus Antibody Test Kit (IDEXX Laboratories, Inc., Westbrook, Maine USA). Testing was conducted and results interpreted following the guidelines within the Snap Combo package insert ([https://www.idexx.com/files/SNAP\\_COMBO\\_package\\_insert\\_032917.pdf](https://www.idexx.com/files/SNAP_COMBO_package_insert_032917.pdf)) as instructed by IDEXX Laboratories, Inc., Westbrook, Maine USA. Positive tests and a subset of negative tests were confirmed by FIV Western Blot (WB) testing at the National Veterinary Laboratory (NVL Laboratories, Inc.; Seattle, WA). *Toxoplasma gondii* titers were evaluated using the *T. gondii* MAT test kit (TgMAT Kit) for detection of anti-*Toxoplasma* IgG antibodies within serum [54-55]. Methods and results were performed and interpreted according to the recommended protocol for MAT test provided by the University of Tennessee (<https://volweb.utk.edu/~csu1/MATprotocol.pdf> ; [https://volweb.utk.edu/~csu1/TgMAT-Modified\\_Agglutination\\_Test.html](https://volweb.utk.edu/~csu1/TgMAT-Modified_Agglutination_Test.html)) and as such, a titer equal to or greater than 1:25 was considered to be a positive test result.

Blood smears were examined using light microscopy using a Wright-Giemsa stain kit (ThermoScientific, Inc.) at 400X, 500X, and 1000X oil immersion to suggest infection with *Hepatozoon* spp., *Babesia* spp., *Leishmania* spp., *Trypanosoma cruzi*, *Ehrlichia* spp., *Rickettsia* spp., and *Anaplasma* spp. Extraction of DNA was completed via the DNeasy Kit (Qiagen; Germantown, MD) was performed on whole blood samples, which then underwent conventional PCR for the detection of blood-borne pathogens. Following PCR, gel electrophoresis was performed using a 1.5% agarose gel and results were evaluated under ultraviolet light. All PCR positive samples were confirmed via Sanger genetic sequencing and the nucleotide BLAST function through GenBank. A negative DNA extraction control, negative PCR control, and positive PCR control were used for each pathogen tested via PCR. *Hepatozoon* spp. and *Babesia* spp. DNA were amplified using a nested PCR technique first described by Gubbels, et al. [56]. *Ehrlichia* spp. DNA was amplified using a nested PCR protocol described in Anderson, et al. [57] and Breitschwerdt, et al. [58]. Similarly, a nested PCR protocol described in Stothard & Fuerst [59] was used to amplify rickettsial DNA. A 16s rRNA targeted primer was used to detect *Anaplasma* spp. as described by Martin, et al. [60] via standard PCR. *Trypanosoma cruzi*



testing was conducted by the Texas A&M Veterinary Medical Diagnostic Laboratory (TVMDL; College Station, TX).

#### *Fecal and Ectoparasite Analysis [61-64]*

Each sample of scat stored in formalin (ocelots, n=17; bobcats, n=31) was analyzed using standard single centrifugal fecal flotation for identification of parasite ova and oocysts using Sheather's sugar solution (specific gravity 1.27). The contents of each formalin container were homogenized using a wooden tongue depressor. For each sample, five mL of the scat and formalin suspension was removed using a disposable syringe and placed into a disposable cup. Ten mL of Sheather's sugar solution was added to the cup and homogenized with a wooden tongue depressor. A 4x4 woven gauze was used to strain the mixture into a 15-mL conical polystyrene centrifuge tube. Sheather's sugar solution was added to the centrifuge tube using a disposable 7-mL transfer pipette until formation of a positive meniscus. A glass cover slip was pressed onto the top of the centrifuge tube and the tube was placed into a swing-out centrifuge (C5 Centrifuge, LW Scientific, Lawrenceville, GA). Samples were centrifuged at 208 g for 6 minutes and then left to stand for 10 minutes. Cover slips were removed and placed individually onto labeled glass microscope slides. Each sample was processed with its own materials and disposable nitrile gloves to prevent cross-contamination. Presence of parasite ova was determined by light microscopy on 100x magnification and confirmed on 400x magnification. Ectoparasites were transferred for long-term storage into glass screw-cap vials with 70% ethanol. They were placed onto a Ward's PetriSlide with microspatulas, sorted, most hair/tissue removed and viewed with a stereo microscope at 20x and 40x magnification.

#### *Statistical Analyses*

Robust methodology was used (suggested for small sample sizes) [65-66] to develop the 95% reference limit with 90% confidence intervals around the limits using the "referenceIntervals" package in R for blood profile parameters. Zero values were replaced with 0.001. Outlier detection method was Tukey (Horn). Differences in differential blood cell counts and laboratory reported values were compared using the paired sample t-tests. Mann-U Whitney tests were run to test for the effect of sex and disease on blood profile parameters for both species. Non-parametric correlations were performed to look at the relationship of number of comorbidities to blood profile parameters. Descriptive statistics (counts and percentages) are

presented for the presence of disease by species, sex, and year. All comparative analyses were run in SPSS 28 with an  $\alpha$  of 0.05.

## Results

### *Hematological and Biochemical Reference Intervals*

Whole blood and serum samples collected from 2019 to 2022 were analyzed for complete blood count and biochemical analysis from adult wild feline species from two genera (*Lynx*: bobcat n=36; 23 male, 13 female and *Leopardus*: ocelot n=22; 10 male, 12 female). Hematological and biochemical reference parameters are presented in **Table 1.1** and **Table 1.2** for ocelots and bobcats. Alkaline phosphatase (ALKP) was unable to be analyzed for either species due to a technical error and therefore, we were unable to report reference limits for this value. There was not a significant effect of sex on blood cell parameters for the complete blood cell counts or chemistry analytes for either species ( $p \geq 0.05$ ). When assessing the differences in white blood cell assessment between values reported by the ProCyte® analyzer and the manual differential count, significant differences were found in the percent of neutrophils ( $p < 0.001$ ), neutrophil concentration ( $p < 0.001$ ), lymphocyte concentration ( $p < 0.001$ ), percent lymphocytes ( $p = 0.007$ ) and platelet concentration ( $p < 0.001$ ); where the ProCyte® counted 4.6 (%) more neutrophils,  $0.96 (10^3/\mu\text{l})$  more neutrophils, 0.36 (%) more lymphocytes,  $0.004 (10^3/\mu\text{l})$  more lymphocytes, and  $114.3 (10^3/\mu\text{l})$  fewer platelets than the differential assessments.

Comparative values for free-ranging ocelots and captive ocelots, bobcats, and domestic cats can be found in **Appendix 1** for reference [70-74]. For ocelots, alanine transaminase (ALT) and total protein had wider ranges of values in this study, but were similar to previous reports for free-ranging and captive ocelot populations. Globulins and creatinine values fell within previously reported values but were not alike one population alone. Blood urea nitrogen (BUN) values reported in this study were different than values reported previously with wider ranges overall and a larger maximum value. For ocelot hematologic values, some ranges were similar to human-managed populations (HCT, WBC concentration), free-ranging populations (hemoglobin, eosinophils), or fell within the reported ranges for both populations (RBC concentration, MCV, MCH, MCHC, neutrophils, platelet concentration). Of note were the differences in particular white blood cell concentrations where lymphocytes and monocytes were

less than reported values, and sometimes reached as low as two to three times less. On the contrary, basophil values were greater than previous reports for this species.

For bobcats, some values (BUN, ALT, glucose) reported in our study were greater than reported values for this species and domestic cats, similar to domestic cats (creatinine, globulins), or fell slightly greater (total protein) than reported bobcat values. For bobcat hematological values, some values were similar to domestic cats (hematocrit, RBC concentration, hemoglobin, MCV), human-managed bobcats (monocytes, basophils, eosinophils) or were similar to both bobcats and domestic cats (MCHC, MCH), while our reported ranges often had wider overall reference intervals. White blood cell concentration and neutrophil concentration were greater than reported values in captive populations.

### *Pathogen Analysis*

Blood smear examination did not reveal parasitic inclusions for any pathogens tested. Bobcat (n= 49; 25 male, 16 female, 8 unknown sex) and ocelot (n=31; 14 male, 14 female, 3 unknown sex) whole blood and serum samples collected and stored frozen (-40°C) from 1985-1986, 2010-2012, and 2019-2022 were included for pathogen testing. The prevalence of pathogens over time for both species are presented in **Table 1.3**. FeLV, *Rickettsia* spp., and *Babesia* spp. were not detected in either species from 1985-2022. Pathogen prevalence for our population (including both ocelots and bobcats), were FIV (18/80; 22%), *Ehrlichia* spp. (2/80; 2.5%), *Hepatozoon* spp. (32/80; 40%), *Leishmania* spp. (2/80; 2.5%), *Trypanosoma cruzi* (4/80; 5%), and *Toxoplasma gondii* (46/80; 57.5%). Pathogen prevalence for ocelots were FIV (7/31; 22.6%), *Hepatozoon* spp. (7/31; 22.6%), *Leishmania* spp. (2/31; 6.5%), and *Toxoplasma gondii* (13/31; 41.9%). For ocelots in which sex was known (male, n=14; female, n=14), males were more likely to have a positive test for FIV (35.7% males; 6.3 % females), and *T. gondii* (42.9% males; 37.5% females), whereas females had a greater prevalence of *Leishmania* spp. (0% males; 14.3% females) and *Hepatozoon* spp. (21.4% males; 28.6% females). Pathogen prevalence for bobcats were FIV (10/49; 20.4%), *Hepatozoon* spp. (25/49; 51%), *Ehrlichia* spp. (2/49; 4.1%), *Trypanosoma cruzi* (4/49; 8.2%), and *Toxoplasma gondii* (33/49; 67.3%). For bobcats in which sex was known (male, n=25; female, n=16), males were more likely to have a positive test for FIV (28% males; 18.8% females), *Ehrlichia* spp. (8% males; 0% females), *Hepatozoon* spp. (64% males; 50% females), *Trypanosoma cruzi* (12%; female 0%), and *T. gondii* (68% males;

62.5% females). Species of pathogens identified by Sanger genetic sequencing were *H. felis*, *luiperdije*, *silvestris*, and *ursi*; *E. ruminatum*; and *L. donovani*. Western blot testing for FIV confirmed 56% (10/18) of positive tests and 87% (13/15) of negative tests. Additionally, for positive FIV snap tests, western blot reported 11% (2/18) were negative and 33% (6/18) were either indeterminate for domestic feline FIV, detected a similar lentivirus to puma lentivirus, or detected an additional unknown lentivirus. Statistical differences in blood analytes based on test results are presented in **Table 1.4**. With the presence of comorbidities ( $\geq 2$  positive pathogen tests), MCH ( $p=0.009$ ) declined and monocyte concentration ( $p=0.028$ ) increased for bobcats; and eosinophil concentration ( $p=0.047$ ) decreased for ocelots.

### *Intestinal Parasite and Ectoparasite Identification*

Intestinal parasite analysis was completed for 17 ocelots (females,  $n=12$ ; males,  $n=5$ ) and 31 bobcats (females,  $n=9$ ; males,  $n=22$ ). Intestinal parasites identified within ocelot and bobcat population's included Helminths (subgroups: Ascarid, Trichostronglyid, Capillarid, Cestode, Ancylostomatidae), Protozoa (subgroup: Apicomplexa), and Arthropoda (subgroup: mite) [**Figure 1.1**]. Prevalence of parasites and parasite identification by sex and species (ocelot vs bobcat) are presented in **Table 1.5**. Helminths were identified in 100% of ocelots and 94% of bobcats. Protozoan parasites were identified in 59% of ocelots and 55% of bobcats. Arthropods were identified in the feces in 18% of ocelots and 35% of bobcats.

Ectoparasites identified in ocelots and bobcats are presented in **Table 1.5** and **Figure 1.2**. Bobcats had a greater presence of ticks and fleas when compared to ocelots. *Dermacentor variabilis* was identified in both with similar tick load (ticks per cat) by species for bobcats (male, 3-8; female, 1-9) and ocelots (male, 2-4; female, 1-2). *Amblyomma* spp. were identified in both species with similar tick load for bobcats (male, 1-2; female, 1-4) and ocelots (male, 1; female, 1). *Rhipicephalus* spp. was identified from a single ocelot female. Two species of fleas were identified within our populations, *Echidnophaga gallinacea* and *Pulex* spp. *Echidnophaga gallinacea* ( $n=8$  adults) was only identified in bobcat females with a range of 2-6 fleas per cat. *Pulex* spp. were identified in both species with males having a slightly greater flea load per cat (ocelots: male, 1-30; female, 2-23; bobcats: male, 1-44; female, 1-38).

**Table 1.1: Biochemical reference intervals for free-ranging ocelots and bobcats in southern Texas.**

Parameter	Ocelots			Bobcats		
	n	LRL of RI*	URL of RI*	n	LRL of RI*	URL of RI*
<i>Urea nitrogen (mg/dL)</i>	24	13.4 (8.7-18.4)	46.8 (40.3-51.7)	36	18.1 (14.9-20.9)	46.2 (42.5-49.2)
<i>Creatinine (mg/dL)</i>	24	0.50 (0.25-0.67)	1.8 (1.5-1.9)	32	0.83 (0.74-0.92)	1.6 (1.5-1.7)
<i>BUN:CREA</i>	24	0.69 (0-8.69)	53.7 (43.6-63.4)	36	10.5 (6.8-14.8)	43.9 (40.2-47.5)
<i>ALT (U/L)</i>	24	31.2 (17.3-46.1)	139.9 (122.8-154.1)	34	14.7 (0-35.7)	159.2 (132.9-181.4)
<i>Glucose (mg/dL)</i>	21	102.4 (83.8-121.4)	228.3 (205.9-247.0)	36	41.2 (20.8-66.7)	253.7 (227.6-278.8)
<i>Total protein (g/dL)</i>	24	6.9 (6.5-7.1)	9.2 (8.9-9.6)	36	6.6 (6.4-6.9)	8.7 (8.4-8.9)
<i>Albumin (g/dL)</i>	24	2.5 (2.4-2.6)	3.3 (3.2-3.4)	36	2.5 (2.3-2.6)	3.4 (3.3-3.6)
<i>Globulin (g/dL)</i>	24	4.0 (3.8-4.3)	6.3 (5.9-6.6)	36	3.7 (3.4-3.9)	5.8 (5.6-6.1)
<i>ALB:GLOB</i>	24	0.39 (0.34-0.43)	0.74 (0.7-0.78)	36	0.38 (0.34-0.43)	0.86 (0.79-0.92)

Abbreviations: RI, reference interval; LRL, lower reference limit; URL, upper reference limit; ALT, alanine transaminase. \*90% confidence interval around the 95% LRL and URL are shown in parentheses in these columns

**Table 1.2: Hematology reference intervals for free-ranging ocelots and bobcats in southern Texas.**

Parameter	Ocelots			Bobcats		
	n	LRL of RI*	URL of RI*	n	LRL of RI*	URL of RI*
<i>HCT (%)</i>	24	20.2 (11.2-29.7)	59.3 (50.0-68.1)	36	24.3 (21.6-27.3)	51.3 (47.6-54.7)
<i>RBC conc. (10<sup>6</sup>/μL)</i>	23	5.9 (5.4-6.5)	9.2 (8.5-9.7)	36	5.3 (4.8-5.8)	9.6 (9.0-10.1)
<i>Hemoglobin (g/dL)</i>	20	10.3 (9.8-11.0)	13.9 (13.4-14.5)	36	7.9 (7.2-8.5)	14.3 (13.4-5.0)
<i>MCV (fL)</i>	24	38.9 (35.0-42.6)	65.7 (61.5-69.8)	36	38.3 (35.7-41.1)	64.3 (60.9-67.6)
<i>MCHC (g/dL)</i>	24	23.4 (21.7-25.7)	37.6 (35.7-39.4)	36	23.2 (21.9-24.8)	35.6 (34.2-36.9)
<i>MCH (pg)</i>	24	14.1 (13.7-14.6)	17.7 (17.2-18.2)	36	13.5 (13.2-13.9)	16.6 (16.3-16.9)
<i>RDW</i>	24	21.5 (20.8-22.2)	26.8 (25.8-27.6)	36	19.9 (19.0-20.8)	28.3 (27.1-29.4)
<i>Reticulocytes</i>	24	0 (0-6.1)	158.7 (129.7-182.7)	36	0 (0-0)	181.8 (149.8-210.4)
<i>WBC conc. (10<sup>3</sup>/μL)</i>	21	8.1 (6.8-10.2)	20.8 (18.3-23.3)	36	7.9 (5.6-10.6)	31.1 (28.6-33.5)
<i>Neutrophil (10<sup>3</sup>/μL)</i>	24	4.9 (3.2-6.9)	20.3 (17.6-22.5)	36	5.3 (3.1-7.9)	27.1 (24.7-29.1)
<i>Lymphocyte (10<sup>3</sup>/μL)</i>	24	0.11 (0-0.87)	2.9 (2.1-3.6)	36	0 (0-0.28)	4.48 (3.76-5.2)
<i>Monocyte (10<sup>3</sup>/μL)</i>	24	0 (0-0.05)	0.41 (0.34-0.47)	36	0 (0-0)	0.77 (0.61-0.91)
<i>Eosinophil (10<sup>3</sup>/μL)</i>		NA (0-0)	NA (0.1-0.8)	36	0 (0-0)	0.57 (0.18-0.83)
<i>Basophil (10<sup>3</sup>/μL)</i>	24	0 (0-0)	0.95 (0.28-1.6)	36	0 (0-0)	0.69 (0.51-0.85)
<i>Platelet conc. (10<sup>3</sup>/μL)</i>	21	219.3 (157.9-279.4)	581.9 (527.3-629.5)	27	109.3 (56.4-163.9)	574.2 (508.6-629.0)
<i>MPV (mg/dL)</i>	24	11.4 (10.6-12.2)	16.3 (15.7-16.9)	36	10.3 (9.5-11.2)	17.5 (16.6-18.3)
<i>PCT</i>	24	0.15 (0.03-0.29)	0.94 (0.82-1.04)	36	0 (0-0.07)	0.79 (0.39-0.88)

Abbreviations: RI, reference interval; LRL, lower reference limit; URL, upper reference limit; HCT, hematocrit; RBC, red blood cell; MCV, mean cell volume; MCHC, mean cell hemoglobin concentration; MCH, mean cell hemoglobin; RDW, red cell distribution width; WBC, white blood cell; conc., concentration; MPV, mean platelet volume; PCT, plateletcrit. \*90% confidence interval around the 95% LRL and URL are shown in parentheses in these columns

**Table 1.3 Pathogen prevalence over time for ocelots and bobcats from 1985 to 2022.**

Percentage of positive individuals within each year out of sampled individuals.

	1985	1986	2010	2011	2012	2019	2020	2021	2022
Ocelots	*n=3	n=0	n=1	n=2	n=3	n=2	n=6	n=6	n=10
FIV	66.7	0	0	50	0	0	16.7	33.3	20
<i>Hepatozoon</i> spp.	0	0	0	50	33.3	0	16.7	66.7	10
<i>T. gondii</i>	33.3	0	0	50	66.7	50	50	50	20
<i>Leishmania</i> spp.	0	0	0	0	0	0	0	33.3	0
	1985	1986	2010	2011	2012	2019	2020	2021	2022
Bobcats	n=2	n=6	n=1	n=1	n=3	n=2	n=9	n=15	n=10
FIV	0	0	0	0	66.7	0	0	40	20
<i>Hepatozoon</i> spp.	0	16.7	100	100	66.7	0	44.4	60	70
<i>T. gondii</i>	50	83.3	100	100	100	100	66.7	53.3	60
<i>Ehrlichia</i> spp.	0	0	0	0	0	0	22.2	0	0
<i>T. cruzi</i>	0	16.7	0	0	0	0	11.1	6.7	10

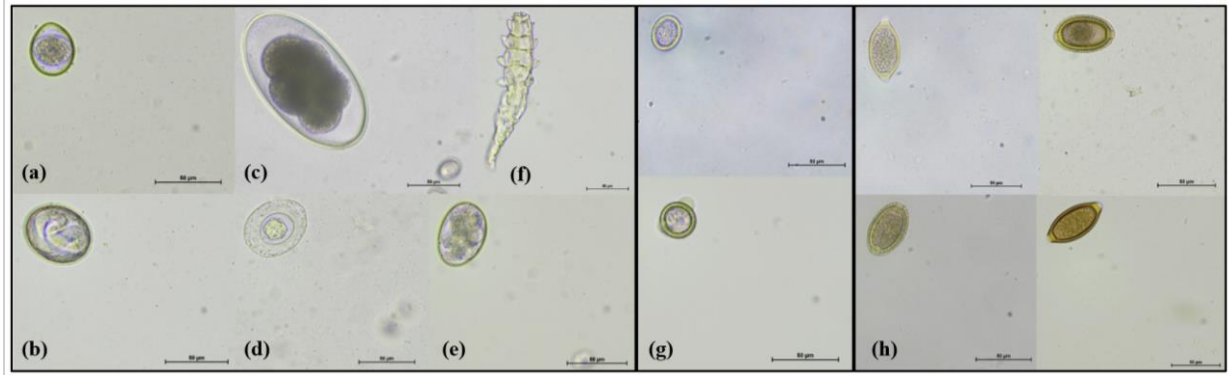
\*n=number of individuals tested during that year

**Table 1.4: Significant differences in blood analytes based on test results for each species.**

<b>Bobcats</b>				
Disease	Analyte	+ Test Result	-Test Result	p-value
FIV	BUN (mg/dL)	37.50 ± 1.83	30.64 ± 1.22	0.009
<i>Ehrlichia</i> spp.	HCT (%)	27.45 ± 0.55	39.05 ± 1.05	0.003
	MCV (fL)	42.65 ± 2.45	52.23 ± 1.04	0.038
	MCHC (g/dL)	34.45 ± 0.95	29.18 ± 0.48	0.019
	Reticulocyte (x10 <sup>3</sup> /μL)	15.2 ± 2.7	88.61 ± 8.25	0.003
	Eosinophil (x10 <sup>3</sup> /μL)	0.35 ± 0.03	0.11 ± 0.05	0.029
	Basophil (x10 <sup>3</sup> /μL)	0.02 ± 0.02	0.38 ± 0.08	0.003
	<i>Hepatozoon</i> spp.	MPV (mg/dL)	13.23 ± 0.38	14.91 ± 0.33
<i>T. gondii</i>	MCH (pg)	14.85 ± 0.15	15.42 ± 0.19	0.038
	Lymphocyte (x10 <sup>3</sup> /μL)	2.85 ± 0.26	1.64 ± 0.14	0.001
<b>Ocelots</b>				
FIV	Lymphocyte (x10 <sup>3</sup> /μL)	1.26 ± 0.06	1.72 ± 0.16	0.036
<i>T. gondii</i>	WBC (x10 <sup>3</sup> /μL)	12.70 ± 0.78	16.41 ± 0.97	0.018
	Neutrophil (x10 <sup>3</sup> /μL)	10.46 ± 0.74	14.31 ± 0.91	0.008
<i>Leishmania</i> spp.	Total Protein	8.85 ± 0.25	7.98 ± 0.11	0.043

Mean± SEM; FIV, Feline Immunodeficiency Virus; spp., species; BUN, blood urea nitrogen; HCT, hematocrit;

MCV, mean cell volume; MCHC, mean cell hemoglobin concentration; MPV, mean platelet volume; MCH, mean cell hemoglobin; WBC, white blood cell concentration




**Figure 1.2: Intestinal parasite ova and arthropods detected in free-ranging ocelot and bobcat fecal samples from 2019-2022 in southern Texas, USA. Protozoa (a) Apicomplexan: *Cystoisospora felis* (41 µm x 36 µm) ; Helminths (b) Ascarid: *Toxascaris leonina* (57 µm x 46 µm), (c) Trichostrongylid: *Nematodirus* spp. (140 µm x 72 µm), (d) Cestode: *Hymenolepis* spp. (56 µm x 48 µm), (e) Ancylostomid: *Ancylostoma* spp. (56 µm x 40 µm); and Arthropods (f) Mite: *Demodex* spp. (187 µm x 32 µm); (g) Unidentified Taeniid-type ova (27-35 µm x 27-29µm); (h) Unidentified Capillarid ova (48-65 µm x 31-34 µm). Magnification (a-h): 400X. Scale bars: (a-h) 50 µm.**

**Table 1.5: Endo- and ectoparasite identification from free-ranging ocelots and bobcats from south Texas from 2019-2022.** The number of positive individuals is shown for each parasite with prevalence (%) given in parentheses. Intestinal parasites, as detected during fecal centrifugation examination, are listed by group, subgroup, genus and species if known. Ectoparasites, detected and collected during physical examination, are listed by group, genus and species if known.

Parasites detected	Parasite ID	Ocelots		Bobcats	
		♀ (n=12)	♂ (n=5)	♀ (n=9)	♂ (n=22)
<i>Helminth</i>					
Ascarid	<i>Toxascaris leonina</i>	12 (100)	5 (100)	2 (22)	10 (45)
Trichostrongylid	<i>Nematodirus</i> spp.	1 (8)			
	UNK	1 (8)			
Capillarid	UNK	7 (58)	1 (20)	2 (22)	3 (14)
Cestode	<i>Hymenolepis</i> spp.	1 (8)	2 (40)		
	Taeniid-type				2 (9)
	UNK			3 (33)	5 (23)
Ancylostomid	<i>Ancylostoma</i> spp.	1 (8)		9 (100)	17 (77)
<i>Protozoa</i>					
Apicomplexan	<i>Cytoisospora felis</i>	9 (75)		1 (11)	3 (14)
	UNK	1 (8)	2 (40)	6 (67)	8 (36)
<i>Arthropod</i>					
Mites	<i>Demodex</i> spp.	2 (17)		2 (22)	8 (36)
	UNK	1 (8)			
Ectoparasites Detected	Lifestage (Sex Ratio)	Ocelots		Bobcats	
		♀ (n=8)	♂ (n=10)	♀ (n=12)	♂ (n=15)
<i>Tick</i>					
<i>Dermacentor variabilis</i>	128 adults (75 ♂: 53 ♀)	4 (50)	5 (50)	12 (100)	14 (93.3)
<i>Amblyomma</i> spp.	<i>maculatum</i>				1 (6.7)
	<i>cajennense</i>			2 (16.7)	1 (6.7)
<i>americanum</i>	1 adult (♂)			1 (8.3)	
UNK	12 adults (4 ♂: 8 ♀) 1 larval (UNK)	1 (12.5)	2 (20)	2 (16.7)	4 (26.7)
<i>Rhipicephalus</i> spp.	2 adults (♀)	1 (12.5)			
<i>Flea</i>					
<i>Pulex</i> spp.	389 adults (145 ♂: 244 ♀)	4 (50)	9 (90)	10 (83.3)	11 (73.3)
<i>Echidnophaga gallinacea</i>	8 adults (1 ♂: 7 ♀)			2 (16.7)	

UNK= unknown genus and species; spp. = unknown species; ♀= female; ♂= male





**Figure 1.2: Ectoparasites detected in free-ranging ocelots and bobcats. Ticks:** (a) *Dermacentor variabilis* (♀; ♂); *Amblyomma* spp: (b) *maculatum* (♂); (c) *cajennense* (♂; ♀); (d) *americanum* (♂); (e) *Rhipicephalus* spp. (♀). **Fleas:** (f) *Pulex* spp.; (g) *Echidnophaga gallinacea*. Photographs obtained at 20x magnification under a dissecting scope by Tiffany Pope. ♀= female; ♂= male

## Discussion

There are no prior published reports of serum chemistry and hematologic reference intervals for free-ranging ocelots in the US and few blood reference values for free-ranging bobcats in other regions of the US [72-76]. This is the first general health assessment and report of blood ranges for ocelots and bobcats residing in southern Texas. Previous reports document reference interval differences based on sex, pregnancy status, and lactation for many domestic and non-domestic species, including felids [67-68; 77-78]; however, there was no sex difference in reference interval ranges for either species within our study, likely due to a small population size and the limited number of pregnant or lactating females. Additionally, age-related differences have been documented between young and adult animals for several species [67, 79-82], but age differences were unable to be examined during our study as tooth extraction for cementum annuli aging and the processing of individuals less than one year of age were not permitted. Some values were similar to human-managed individuals, free-ranging individuals, both or did not agree with either suggesting caution, not only in comparisons across species, but within species residing in different geographic regions. These findings demonstrate the importance of species-specific reference intervals as the values we established for these populations were not similar to any single population.

The main differences noted for our populations of ocelots and bobcats were elevations of blood urea nitrogen, total protein, basophils, glucose, and neutrophils compared to prior reports. Blood urea nitrogen is produced in the liver, excreted by the kidneys and can be elevated due to dehydration, kidney dysfunction or injury, high protein diets, and various infectious, toxic or inflammatory pathways [83-84]. Additionally, increases in total proteins, basophils, and neutrophils can indicate infection, inflammation, or stress responses, and increases in total protein can also be noted in dehydrated animals [83-86]. The combination of a naturally high protein diet, dehydration due to drought-like conditions seen in this study area, and the lack of access to water while in the trap suggest the changes seen in BUN and total protein to be transient and not indicative of a disease state. Additionally, the increases in basophils and neutrophils could relate to parasitic, bacterial or viral infections.

Another difference noted for our populations were the lower numbers of white blood cells, specifically lymphocytes and monocytes compared to other populations. Lymphocytes are responsible for humoral and cellular immunity and decreases in these values can be due to a

response to glucocorticoid secretion during stressful events and inflammatory or infectious processes [83, 86]. Monocytes are responsible for antigen presentation and the production of cytokines with decreases either normally present in animals or associated with bone marrow disease [83, 86-89]. Decreases in the numbers of these cells are likely related to capture stress, declines in the production of these cells due to decreases in immune fitness, and/or a disease state decreasing white blood cell production at the level of the bone marrow.

Differential counts were performed for each individual to assess the population of white blood cells and red blood cells for shape, size, and reactivity, and perform a manual platelet count for comparison to what is reported by the ProCyte® analyzer. The ProCyte® analyzer counts cells based on the size of the cell and other cell characteristics, such as the presence or absence of a nucleus, to classify them into the correct population [Data on file at IDEXX Laboratories, Inc. 2013]. When multiple small platelets are clumped, they can be counted as one, falsely reporting low platelet numbers [83, 90-91]. Common causes of decreased platelets include clumping, decreased production, increased consumption or destruction, or various infectious pathways, especially tick-borne pathogens [83, 90-91]. When comparing what the ProCyte® analyzer reported for platelets to our differential count, the analyzer was counting significantly fewer platelets than the manual count due to platelet clumping, which is frequently seen in felids [83, 90-91]. This shows the importance of a manual platelet count to accurately represent an individual's platelet number and decrease concern for clotting abilities or disease [83, 90-91].

Males from both species had a higher likelihood of a positive test for all pathogens that were identified, with the exception of *Leishmania* spp. in ocelots where females had a higher prevalence. For ocelots that tested positive for *Leishmania* spp., a mild decline in total protein was noted; however, this value did not fall below the reported ranges for our populations. For tick-borne pathogens we attribute this difference to more fastidious grooming habits of females, smaller home ranges leading to fewer interaction with ectoparasites, cross-grooming with female kittens that may remain within the same home range for a longer time period and to the occasional demonstration of less solitary behavior by traveling in groups. For these pathogens (*Ehrlichia* spp. and *Hepatozoon* spp.), there was a trend of decreased hematocrit and mean platelet volume in bobcats, respectively. Most tick-borne illnesses in domestic cats present with similar clinical signs such as joint swelling, fever, anorexia, and dehydration [92-95] with

accompanying blood profile abnormalities, such as mild reductions in white blood cell counts, red blood cell counts, low platelet numbers and declines in liver values [92-96]. Our trend of blood profile abnormalities was similar to these previous reports; however, these values did not fall outside of blood profile reference ranges for either species.

Currently, *T. gondii* has high antibody prevalence in bobcat and ocelots populations throughout other locations along their range [97-100], similar to our reports of high prevalence in southern Texas. In members of the family Felidae, toxoplasmosis can cause a range of disease presentations from no clinical signs in healthy individuals [101] to more severe clinical signs and even death, in individuals with concurrent immunosuppression [15, 101-103]. Although we observed no clinical signs of *T. gondii* infection and while white blood cell concentrations (lymphocytes and neutrophils) differed based on presence, these values did not fall outside of reference intervals reported for these species. Evidence of this parasite at high levels in our populations necessitates the importance of personal protective equipment when handling feline feces to prevent transmission to female wildlife personnel, and more specifically those expecting a child [33], in which the congenital defects and severity of disease can be devastating [104-105].

Similarly, males of both species had higher likelihoods of a positive test for FIV. We suspect male behaviors play a key role in the transmission of FIV during territorial disputes or competition for the attention of a female whereby FIV is transmitted by bite wounds from infected saliva allowing the virus to enter the blood stream [18]. Females, while still positive a percentage of the time, are less likely to engage in territorial behaviors and may possibly contract this pathogen from males during mating with biting of the nape of the neck, from mother to kitten [18], and/or protection of offspring leading to physical disputes. Additionally, the possibility of transmission among ocelots, bobcats, and feral cats within this region is of great concern as cross-species transmission has been documented [30-31, 106-108]. FIV screening was performed with the IDEXX Snap-test and confirmed with the western blot test. The western blot test confirmed a higher proportion of negative results suggesting a higher specificity and a lower sensitivity of the snap test. Additionally, the western blot test detected the presence of various lentiviruses in which further sequencing is needed to identify the origin of these viruses in our populations.

The detection and presence of a pathogen does not always necessitate clinical presence of disease. FIV typically causes a decline, rebound, and again decline of CD4 and CD8 T-lymphocytes, leading to a decline in cell mediated immunity with the individual becoming five times more likely to develop neoplasia compared to non-infected cats [18], and increases the susceptibility to pathogens that would not normally cause disease in healthy individuals. Historically, this disease is thought of as benign in wild populations [108]; however, the depletion of cell-mediated immunity increases the risk of contracting secondary infections causing clinical disease and possible death, that in normal individuals would not necessarily pose a threat [109]. Changes seen in chemistry analytes from positive individuals were an increased BUN for bobcats and a decrease in lymphocytes for ocelots. While increases in BUN are likely to stem from dehydration, rather than FIV infection, decreases in lymphocytes could be related to decreased immune fitness related to infection with this pathogen. Additionally, our populations did not demonstrate any clinical disease associated with this pathogen [110-111]. However, these results could be skewed due to premature death due to disease and/or lack of capture of clinically ill individuals within this population.

Many intestinal parasites were frequently noted in both species; however, suboptimal body condition was not noted in any individuals throughout this study. The most common parasite reported for ocelots was an ascarid (roundworm), *Toxascaris leonina*; and for bobcats was an ancylostomid (hookworm) of unknown species. Overall, ocelots had more protozoa but both species had similar findings for intestinal parasite ova. A low frequency of arthropods was detected in the feces of ocelots and bobcats, with bobcats having a slightly higher presence. *Demodex* (species *cati* and *gatoi*) are known to live naturally on feline host species causing little clinical disease [112-113], but can cause disease with the presence of comorbidities [112]. Feline demodicosis is more commonly found in younger cats, causing severe itching, hair loss, crusting and fluid-filled sores, and can be associated with the presence of other pathogens [112]. *Demodex* mites are generally host-specific and are identified in many wild species to date [114], including multiple rodent species [115-119]. These populations have likely adapted to the elevated presence of intestinal parasites and may be incidental hosts for some parasites ingested from prey items, through contaminated soil or water, or natural grooming habits.

Overall, bobcats had a higher presence of ectoparasites compared to ocelots, with a slight increase in load observed in males of both felid species. Higher loads in bobcats could be due to

a lack of efficient removal due to longer hair coats, and for males, a lack of cross-grooming behaviors sometimes observed in females. The most common tick species identified was *Dermacentor variabilis* (also known as the American dog tick or wood tick) known to be distributed across the eastern US and down to southern Texas [120]. This tick is known to transmit the causative agent (*Rickettsia rickettsii*) of Rocky Mountain spotted fever in humans [RMSF; 121], one of many ticks known to cause tick paralysis worldwide [122-126], and can be a vector for *Cytauxzoon felis* [127], *Francisella tularensis* [128], and *Ehrlichia* species [129-130] in domestic cats. Another tick (*Amblyomma americanum*) also identified less abundantly in our bobcat population is additionally known to cause tick paralysis [123, 125-126], tularemia [128] and serve as a vector for *Ehrlichia* species [129] and *Cytauxzoon felis* [122, 131-133].

While ticks were noted in abundance within our populations and positive tests for a few tick-borne pathogens of which these ticks are known vectors (*Ehrlichia* spp., this study and *Cytauxzoon felis*, Kern et al. unpublished data) are reported, clinical disease was not observed for either of these pathogens. These findings further indicate an early disease process, the possible evolution of these populations to live concurrently with chronic pathogen exposure and presence over time, and/or the lack of representation of clinical animals due to death or lack of capture. The identification of pathogen presence within our reported tick species would need to be further examined.

The most common flea species identified in our population was of the *Pulex* genus. Many fleas are known to infest domestic and wild canids and felids in North America, including *Ctenocephalides felis* (cat flea), *Ctenocephalides canis* (dog flea), *Pulex simulans* (flea of small mammals) and *Echinophaga gallinacea* (sticktight flea) [134]. Due to the high numbers of javelina in southern Texas, we suspect the *Pulex* species identified in this study to be *Pulex porcinus*, but further examination would be needed to confirm this suspicion. While cat fleas can serve as vectors of *Rickettsial* species, *Bartonella* spp., and as an intermediate host for filarids and cestode parasites in felines [134], it is unclear if the javelina flea can serve these roles in felines as well. Additionally, we observed a low presence of *E. gallinacea* in our population; however, sticktight fleas are not known to transmit pathogens to their hosts [135].

Although some changes in hematologic and biochemical parameters were found when an individual was positive for a pathogen, and although changes were noted, none of those parameters fell outside of the ranges reported for this population challenging the clinical

significance of such changes. Additionally, clinical signs (skin lesions, cardiac murmurs, pale mucous membranes, petechia, or other physical examination abnormalities) associated with disease were not observed in our study population suggesting either a sub-clinical stage of infection, a lack of clinical impact on these populations, and/or a lack of ill individuals represented in our study numbers due to death or lack of capture. Over time there was an increase in prevalence for two pathogens, *Lieshmania* spp. and *Ehrlichia* spp., with both pathogens being undetected in ocelot and bobcat populations prior to 2019, respectively [Figure 1.1]. Increases in these pathogens could suggest an increase in susceptibility or a lack of power in sample numbers for previous years decreasing the likelihood of detection. There were minimal statistically significant or clinically relevant effects on blood values with the presence of coinfections in these populations. The hematologic and biochemical reference intervals presented can be used in future efforts to monitor and evaluate health and disease long-term for these species in southern Texas. Additionally, as we did not see signs of immune demise as it relates to genetic decline, there may not be a detectable relationship currently, but with continued inbreeding events, a negative relationship may arise.

## References

- [1] J.E. Janecka, M.E. Tewes, L. Laack, A. Caso, L.I. Grassman, R.L. Honeycutt. Loss of Genetic Diversity among Ocelots in the United States during the 20th Century Linked to Human Induced Population Reductions. *Plos One*. 9:2 (2014) e89384. <https://doi.org/10.1371/journal.pone.0089384>
- [2] J.E. Janečka, M.E. Tewes, L.L. Laack, A. Caso, L.I. Grassman Jr, A.M. Haines, D.B. Shindle, B.W. Davis, J. Murphy, R.L. Honeycutt. Reduced genetic diversity and isolation of remnant ocelot populations occupying a severely fragmented landscape in southern Texas. *Anim Conserv*. 14:6 (2011) 608-619. <https://doi.org/10.1111/j.1469-1795.2011.00475.x>
- [3] A. Paviolo, P. Crawshaw, A. Caso, T. de Oliveira, C.A. Lopez-Gonzalez, M. Kelly, C. De Angelo, E. Payan. *Leopardus pardalis*. The IUCN Red List of Threatened Species. (2016). <https://www.iucnredlist.org/species/11509/97212355#threats>.
- [4] Fish and Wildlife Service. *Endangered and Threatened Wildlife and Plants; Initiation of 5-Year Status Reviews of 38 Species in the Southwest Region (Arizona, New Mexico, Oklahoma, and Texas)*, 83 Fed. Reg. 25034. (2018).
- [5] A.M. Haines, J.E. Janecka, M.E. Tewes, L.I. Grassman Jr., P. Mortion. The importance of private lands for ocelot *Leopardus pardalis* conservation in the United States. *Oryx*. 40:1 (2006) 90-94. <https://doi.org/10.1017/S0030605306000044>
- [6] J. Janečka, M.E. Tewes, L.L. Laack, L.I. Grassman Jr. Small effective population sizes of two remnant ocelot populations ( *Leopardus pardalis albescens* ) in the United States. *Conserv Genet*. 9:4 (2008) 869-878. <http://dx.doi.org/10.1007/s10592-007-9412-1>
- [7] A.M. Haines, M.E. Tewes, L.L. Laack, W.E. Grant. Evaluating recovery strategies for an ocelot ( *Leopardus pardalis* ) population in the united states. *Biol Conserv*. 126:4 (2005) 512-522. <http://dx.doi.org/10.1016/j.biocon.2005.06.032>
- [8] J.S. Horne, A.M. Haines, M.E. Tewes, L.L. Laack. Habitat partitioning by sympatric ocelots and bobcats: implications for recovery of ocelots in southern Texas. *The Southwestern Naturalist*. 54:2 (2009) 119-126. <http://www.bioone.org/doi/full/10.1894/PS-49.1>



- [9] A.T. Cain, V.R. Tuovila, D.G. Hewitt, M.E. Tewes. Effects of a highway and mitigation projects on bobcats in southern Texas. *Biological Conservation*. 114:2 (2003) 189–197. [https://doi.org/10.1016/S0006-3207\(03\)00023-5](https://doi.org/10.1016/S0006-3207(03)00023-5)
- [10] J.E. Janecka, M.E. Tewes, I.A. Davis, A.M. Haines, A. Caso, T.L. Blankenship, R.L. Honeycutt. Genetic differences in the response to landscape fragmentation by a habitat generalist, the bobcat, and a habitat specialist, the ocelot. *Conserv Genet*. 17:5 (2016) 1093–1108. <https://doi.org/10.1007/s10592-016-0846-1>
- [11] S.D. Booth-Binczik, R.D. Bradley, C.W. Thompson, L.C. Bender, J.W. Huntley, J.A. Harvey, L.L. Laack, J.L. Mays. Food Habits of Ocelots and Potential for Competition With Bobcats In Southern Texas. *The Southwestern Naturalist*. 58:4 (2013) 403–410. <https://doi.org/10.1894/0038-4909-58.4.403>
- [12] J.V. Lombardi, D.I. MacKenzie, M.E. Tewes, H.L. Perotto-Baldivieso, J.M. Mata, T.A. Campbell. Co-occurrence of bobcats, coyotes, and ocelots in Texas. *Ecol Evol*. 10:11 (2020) 4903–4917. <https://doi.org/10.1002/ece3.6242>
- [13] J.D. Roth, D.L. Murray, T.D. Steury. Spatial dynamics of sympatric canids: Modeling the impact of coyotes on red wolf recovery. *Ecol Modell*. 214:2 (2008) 391–403. <https://doi.org/10.1016/j.ecolmodel.2008.03.011>
- [14] C.W. Walker. *Patterns of genetic variation in ocelot (Leopardus pardalis) populations for south Texas and northern Mexico*. ProQuest Dissertations Publishing. (1997). <https://www.proquest.com/docview/304403103?pq-origsite=primo>
- [15] D. Charlesworth, J.H. Willis. The genetics of inbreeding depression. *Nat Rev Genet*. 10:11 (2009) 783–796. <https://doi.org/10.1038/nrg2664>
- [16] N. Lamberski. Felidae. In: *Fowler's Zoo and Wild Animal Medicine*. 8 (2015) 467-476. <https://doi.org/10.1016/B978-1-4557-7397-8.00047-5>
- [17] R. Tandon, V. Cattori, B. Willi, H. Lutz, R. Hofmann-Lehmann. Quantification of endogenous and exogenous feline leukemia virus sequences by real-time PCR assays. *Vet Immunol Immunopathol*. 123:1-2 (2008) 129–133. <https://doi.org/10.1016/j.vetimm.2008.01.027>

- [18] S. Little, J. Levy, K. Hartmann, R. Hofmann-Lehmann, M. Hosie, G. Olah, K. Denis. 2020 AAFP Feline Retrovirus Testing and Management Guidelines. *J Feline Med Surg*. 22:1 (2020) 5–30. <https://doi.org/10.1177/1098612x19895940>
- [19] T. Gomerčić, M. Perharić, J. Kusak, V. Slijepčević, V. Starešina, V. Stevanović, V.M. Perko, I. Topličanec, M. Sindičić. A retroviral survey of endangered Eurasian lynx (*Lynx lynx*) from Croatia. *Veterinarski arhiv* 91:1 (2021) 65-71. <https://doi.org/10.24099/vet.arhiv.0857>
- [20] M.W. Cunningham, M.A. Brown, D.B. Shindle, S.P. Terrell, K.A. Hayes, B.C. Ferree, R.T. McBride, E.L. Blankenship, D. Jansen, S.B. Citino, M.E. Roelke, R.A. Kiltie, J.L. Troyer, S.J. O'Brien. Epizootiology and management of feline leukemia virus in the Florida puma. *J Wildl Dis*. 44 (2008) 537-552. DOI: 10.7589/0090-3558-44.3.537
- [21] S. Kennedy-Stoskopf. Emerging viral infections in large cats. In: Zoo and Wild Animal Medicine (Fowler, M. E., R. E. Miller, Eds.), W. B. Saunders, Philadelphia. (1999) 401-410
- [22] C.M. Leutenegger, R. Hofmann-Lehmann, C. Riols, M. Liberek, G. Worel, P. Lups, D. Fehr, M. Hartmann, P. Weilenmann, H. Lutz. Viral infections in free-living populations of the European wildcat. *J Wildl Dis*. 35 (1999) 678–686. <https://doi.org/10.7589/0090-3558-35.4.678>
- [23] M.W. Cunningham, M.A. Brown, S.P. Terrell, E.D. Land, D.B. Shindle, S.B. Citino, A. Roca, W.E. Johnson, S.J. O'Brien. Epizootiology and management of feline leukemia virus in free-ranging Florida panthers: Preliminary results. In Joint conference of the American Association of Zoo Veterinarians. American Association of Wildlife Veterinarians, and the Wildlife Disease Association, San Diego, California. (2004) 28 August–3 September: 419.
- [24] M.L. Meli, V. Cattori, F. Martínez, G. López, A. Vargas, F. Palomares, J.V. López-Bao, R. Hofmann-Lehmann, H. Lutz. Feline leukemia virus infection: a threat for the survival of the critically endangered Iberian lynx (*Lynx pardinus*). *Vet Immunol Immunopathol*. 134:1-2 (2010) 61-67. <https://doi.org/10.1016%2Fj.vetimm.2009.10.010>
- [25] I. Sacristán, F. Acuña, E. Aguilar, S. García, M.J. López, J. Cabello, E. Hildalgo-Hermoso, J. Sanderson, K.A. Terio, V. Barrs, J. Beatty, W.E. Johnson, J. Millán, E. Poulin, C. Napolitano. Cross-species transmission of retroviruses among domestic and wild felids in human-occupied landscapes in Chile. *Evol Appl*. 14 (2021) 1070– 1082. <https://doi.org/10.1111%2Feva.13181>

- [26] M. Ammersbach, D. Bienzle. Methods for assessing feline immunodeficiency virus infection, infectivity and purification. *Vet Immunol and Immunopathol.* 143:3 (2011) 202–214. <https://doi.org/10.1016/j.vetimm.2011.06.004>
- [27] C. Filoni, C.H. Adania, E.L. Durigon, J.L. Catão-Dias. Serosurvey for feline leukemia virus and lentiviruses in captive small neotropic felids in São Paulo state, Brazil. *J Zoo Wildl Med.* 34:1 (2003) 65-68. [https://doi.org/10.1638/1042-7260\(2003\)34\[0065:sfflva\]2.0.co;2](https://doi.org/10.1638/1042-7260(2003)34[0065:sfflva]2.0.co;2)
- [28] S.P. Franklin, R.W. Kays, R. Moreno, J.A. TerWee, J.L. Troyer, S. VandeWoude. Ocelots on Barro Colorado Island Are Infected with Feline Immunodeficiency Virus but Not Other Common Feline and Canine Viruses. *J Wildl Dis.* 44:3 (2008) 760–765. <https://doi.org/10.7589/0090-3558-44.3.760>
- [29] Z. Zhang, Q. Gu, D. Marino, K.L. Lee, I.K. Kong, D. Häussinger, C. Münk. Feline APOBEC3s, Barriers to Cross-Species Transmission of FIV? *Viruses.* 10:4 (2018) 186. <https://doi.org/10.3390%2Fv10040186>
- [30] J.L. Troyer, S. VandeWoude, J. Pecon-Slattery, C. McIntosh, S. Franklin, A. Antunes, W. Johnson, S.J. O'Brien. FIV cross-species transmission: an evolutionary prospective. *Vet Immunol Immunopathol.* 123:1-2 (2008) 159-166. <https://doi.org/10.1016%2Fj.vetimm.2008.01.023>
- [31] S. VandeWoude, J. Troyer, M. Poss. Restrictions to cross-species transmission of lentiviral infection gleaned from studies of FIV. *Vet Immunol Immunopathol.* 134 (2010) 25–32. <https://doi.org/10.1016/j.vetimm.2009.10.005>
- [32] M. Attias, D. Teixeira, M. Benchimol, R. Vommaro, P. Crepaldi, W. De Souza. The life-cycle of *Toxoplasma gondii* reviewed using animations. *Parasites Vectors.* 13:1 (2020) 588–588. <https://doi.org/10.1186/s13071-020-04445-z>
- [33] F. Robert-Gangneux, M. Darde. Epidemiology of and Diagnostic Strategies for Toxoplasmosis. *Clin Microbiol Rev.* 25:2 (2012) 264–296. <https://doi.org/10.1128/CMR.05013-11>
- [34] D. Hill, J. Dubey. *Toxoplasma gondii*: transmission, diagnosis and prevention. *Clin Microbiol Infect.* 8:10 (2002) 634–640. <https://doi.org/10.1046/j.1469-0691.2002.00485.x>

- [35] E.S. Al-Malki. Toxoplasmosis: stages of the protozoan life cycle and risk assessment in humans and animals for an enhanced awareness and an improved socio-economic status. *Saudi J Biol Sci.* 28:1 (2021) 962–969. <https://doi.org/10.1016/j.sjbs.2020.11.007>
- [36] M.G. Pennisi, A. Radford, S. Tasker, S. Belák, D.D. Addie, C. Boucraut-Baralon, H. Egberink, T. Frymus, T. Gruffydd-Jones, K. Hartmann, M.C. Horzinek, M.J. Hosie, A. Lloret, H. Lutz, F. Marsilio, E. Thiry, U. Truyen, K. Möstl. *Anaplasma*, *Ehrlichia*, and *Rickettsia* species infections in cats: European guidelines from the ABCD on prevention and management. *J Feline Med Surg.* 19:5 (2017) 542-548. <https://doi.org/10.1177%2F1098612X17706462>
- [37] R. Curtis-Robles, S.A. Hamer, S. Lane, M.Z. Levy, G.L. Hamer. Bionomics and spatial distribution of triatomine vectors of *Trypanosoma cruzi* in Texas and other southern states. USA. *Am J Trop Med Hyg.* 98 (2018) 113-121. <https://doi.org/10.4269/ajtmh.17-0526>
- [38] I.B. Zecca, C.L. Hodo, S. Slack, L. Auckland, S. Rodgers, K.C. Killets, A.B. Saunders, S.A. Hamer. Prevalence of *Trypanosoma cruzi* infection and associated histologic findings in domestic cats (*Felis catus*). *Vet Parasitol.* 278 (2020) 109014. <https://doi.org/10.1016/j.vetpar.2019.109014>
- [39] H.M. Herrera, F.L. Rocha, C.V. Lisboa, V. Rademaker, G.M. Mourao, A.M. Jansen. Food web connections and the transmission cycles of *Trypanosoma cruzi* and *Trypanosoma evansi* (Kinetoplastida, Trypanosomatidae) in the Pantanal region, Brazil. *Trans R Soc Trop Med Hyg.* 105 (2011) 380-387.
- [40] F.L. Rocha, A.L. Roque, R.C. Arrais, J.P. Santos, V.D. Lima, S.C. Chagas Xavier, J. Cordeir-Estrela, P.S. D’Andrea, A.M. Jansen. *Trypanosoma cruzi* TcI and TcII transmission among wild carnivores, small mammals and dogs in a conservation unit and surrounding areas, Brazil. *Parasitol.* 140 (2013) 160-170. <https://doi.org/10.1017/s0031182012001539>
- [41] F.L. Rocha, A.L.R. Roque, J. Saab de Lima, C.C. Cheida, F.G. Lemos, F. Cavalcanti de Azevedo, R.C. Arrais, D. Bilac, H.M. Herrera, G. Mourao, A.M. Jansen. *Trypanosoma cruzi* infection in neotropical wild carnivores (mammalia : carnivora): at the top of the *T. cruzi* transmission chain. *Plos One.* 8:7 (2013) e67463.

- [42] R.W. Allison, S.E. Little. Diagnosis of Rickettsial diseases in dogs and cats. *Vet Clin Pathol.* 42 (2013) 127-144. <https://doi.org/10.1111/vcp.12040>
- [43] A. Lloret. Hepatozoonosis in European Advisory Board on Cat Diseases (ABCD). (2020) <http://www.abcdcatsvets.org/hepatozoonosis/>
- [44] G. Baneth, Y. Nachum-Biala, A. Zuberi, N. Zipori-Barki, L. Orshan, G. Kleinerman, A. Shmueli-Goldin, M. Bellaiche, M. Leszkowicz-Mazuz, H. Salant, D. Tasur-Landau. Leishmania infection in cats and dogs housed together in an animal shelter reveals a higher parasite load in infected dogs despite a greater seroprevalence among cats *Parasit. Vectors.* 13 (2020) 115. <https://doi.org/10.1186/s13071-020-3989-3>
- [45] E. Spada, E. Perego, F. Vitale, F. Bruno, G. Castelli, G. Tarantola, L. Baggiani, S. Magistrelli, D. Proverbio. Feline Leishmania spp. Infection in a Non-Endemic Area of Northern Italy. *Anim (Basel).* 10:5 (2020) 817. <https://doi.org/10.3390%2Fani10050817>
- [46] I.P. Metzdorf, M.S. da Costa Lima, M. de Fatima Cepa Matos, A.F. de Souza Filho, R.A. de Souza Tsujisaki, K.G. Franco, J.T. Shapiro, F. de Almeida Borges. Molecular characterization of *Leishmania infantum* in domestic cats in a region of Brazil endemic for human and canine visceral leishmaniasis. *Acta Tropica.* 166 (2017) 121-125. <https://doi.org/10.1016/j.actatropica.2016.11.013>
- [47] M.T. Craig, C.L. Barton, S.H. Mercer, B.E. Droleskey, P. Jones. Dermal leishmaniasis in a Texas cat. *Am J Trop Med Hyg.* 35 (1986)1100- 1102. <https://doi.org/10.4269/ajtmh.1986.35.1100>
- [48] K.E. Trainor, B.F. Porter, K.S. Logan, R.J. Hoffman, K.F. Snowden. Eight cases of feline cutaneous leishmaniasis in Texas. *Vet Pathol.* 47 (2010) 1076-1081. <https://doi.org/10.1177/0300985810382094>
- [49] H.M. Minard, A.K. Daniel, R.R. Pool, K.F. Snowden, G.J. Levine. Pathology in practice. *J Am Vet Med Assoc.* 251 (2017) 57-59. <https://doi.org/10.2460/javma.251.1.57>
- [50] C. Petersen. Feline Leishmaniosis in Merck Vet Manual; <https://www.merckvetmanual.com/generalized-conditions/leishmaniosis/feline-leishmaniosis> ). (2020) Accessed June 2022.

[51] L. Del Río, L. Chitimia, A. Cubas, I. Victoriano, P. De la Rúa, X. Gerrikagoitia, M. Barral, C.I. Muñoz-García, E. Goyena, D. García-Martínez, R. Fisa, C. Riera, L. Murcia, M. Segovia, E. Berriatua. Evidence for widespread *Leishmania infantum* infection among wild carnivores in *L. infantum* periendemic northern Spain. *Prev Vet Med.* 113 (2014) 430-435.

<https://doi.org/10.1016/j.prevetmed.2013.12.001>

[52] J. Risueño, M. Ortuño, P. Pérez-Cutillas, E. Goyena, C. Maia, S. Cortes, L. Campino, L.J. Bernal, C. Muñoz, I. Arcenillas, F.J. Martínez-Rondán, M. González, F. Collantes, J. Ortiz, C. Martínez-Carrasco, E. Berriatua. Epidemiological and genetic studies suggest a common *Leishmania infantum* transmission cycle in wildlife, dogs and humans associated to vector abundance in Southeast Spain. *Vet Parasitol.* 259 (2018) 61-67.

<https://doi.org/10.1016/j.vetpar.2018.05.012>

[53] T. Morsy, M.A. Aldakhil, A. el-Bahrawy. Natural *Leishmania* infection in sand cats captured in Riyadh district, Saudi Arabia. *J Egypt Soc Parasitol.* 29 (1999) 69-74.

[54] G. Desmonts, J.S. Remington. Direct agglutination test for diagnosis of *Toxoplasma* infection: method for increasing sensitivity and specificity. *J Clin Microbiol.* 11:6 (1980) 562-568. <https://doi.org/10.1128%2Fjcm.11.6.562-568.1980>

[55] J.P. Dubey, G. Desmonts. Serological responses of equids fed *Toxoplasma gondii* oocysts. *Equine Vet J.* 19:4 (1987) 337-339. <https://doi.org/10.1111/j.2042-3306.1987.tb01426.x>

[56] J.M. Gubbels, A.P.de Vos, M. van der Weide, J. Viseras, L.M. Schouls, E. de Vries, F. Jongejan. Simultaneous detection of bovine *Theileria* and *Babesia* species by reverse line blot hybridization. *J Clin Microbiol.* 37:6 (1999). <https://doi.org/10.1128/JCM.37.6.1782-1789.1999>

[57] B.E. Anderson, C.E. Greene, D.C. Jones, J.E. Dawson. *Ehrlichia ewingii* sp. nov., the etiologic agent of canine granulocytic ehrlichiosis. *Internat J Syst Evol Microbiol.* 42:2 (1992). <https://doi.org/10.1099/00207713-42-2-299>

[58] E.B. Breitschwerdt, B.C. Hegarty, S.I. Hancock. Sequential evaluation of dogs naturally infected with *Ehrlichia canis*, *Ehrlichia chaffeensis*, *Ehrlichia equi*, *Ehrlichia ewingii*, or *Bartonella vinsonii*. *J Clin Microbiol.* 36:9 (1998) 2645-2651.

<https://doi.org/10.1128/jcm.36.9.2645-2651.1998>

- [59] D. Stothard, P. Fuerst. Evolutionary analysis of the spotted fever and typhus group rickettsiae using 16S rRNA gene sequences. *Syst Appl Microbiol.* 18 (1995) 52-61.  
[https://doi.org/10.1016/S0723-2020\(11\)80448-0](https://doi.org/10.1016/S0723-2020(11)80448-0)
- [60] A.R. Martin, G.K. Brown, R.H. Dunstan, T.K. Roberts. *Anaplasma platys*: an improved PCR for its detection in dogs. *Exper Parasitol.* 109:3 (2005) 176-180.  
<https://doi.org/10.1016/j.exppara.2004.11.007>
- [61] M.W. Dryden, P.A. Payne, R. Ridley, V. Smith. Comparison of Common Fecal Flotation Techniques for the Recovery of Parasite Eggs and Oocysts. *Vet Ther.* 6 (2005) 15-28.
- [62] C.M. Hendrix, E. Robinson. Diagnostic parasitology for veterinary technicians. 4th Ed. Elsevier, St. Louis, Missouri. (2012) 392.
- [63] A.M. Zajac, G.A. Conboy. Veterinary Clinical Parasitology. 8th Ed. Wiley-Blackwell, Ames, Iowa. (2012) 356.
- [64] W.J. Foreyt. Veterinary Parasitology Reference Manual. 5th Ed. Blackwell Publishing, Ames, Iowa. (2001)235.
- [65] K.R. Friedrichs, K.E. Harr, K.P. Freeman, B. Szladovits, R.M. Walton, K.F. Barnhart, J. Blanco-Chavez. ASVCP reference interval guidelines: determination of de novo reference intervals in veterinary species and other related topics. *Vet Clin Pathol.* 41:4 (2012) 441-453.  
DOI:10.1111/vcp.12006
- [66] Clinical and Laboratory Standards Institute. Defining, Establishing, and Verifying Reference Intervals in the Clinical Laboratory; Approved Guidelines. 3rd ed. Wayne, PA:CLSI. (2008).
- [67] D.L. Miller, B.D. Leopold, M.J. Gray, B.J. Woody. Blood parameters of clinically normal captive bobcats (*Felis rufus*). *J Zoo Wildl Med.* 30:2 (1999) 242-247. PMID: 10484139
- [68] C.E. Widmer, E.R. Matushima, F.C.C. de Azevedo. Clinical Evaluation, Hematology, and Serum Chemistry of Ocelots (*Leopardus pardalis*) in the Atlantic Forest of Brazil. *J Wildl Dis.* 52:4 (2016) 916-621. <https://doi.org/10.7589/2015-09-225>

- [69] S.E. Aiello, M.A. Moses, editors. The Merck veterinary manual online. Hematologic reference ranges. Merck, Sharp, and Dohme Corp. New York, New York. (2012). [http://www.merckvetmanual.com/mvm/appendixes/reference\\_guides/hematologic\\_reference\\_ranges.html](http://www.merckvetmanual.com/mvm/appendixes/reference_guides/hematologic_reference_ranges.html). Accessed December 2021.
- [70] S.E. Aiello, M.A. Moses, editors. The Merck veterinary manual online. Serum biochemical reference ranges. Merck, Sharp, and Dohme Corp. New York, New York. (2012). [http://www.merckvetmanual.com/mvm/appendixes/reference\\_guides/serum\\_biochemical\\_reference\\_ranges.html](http://www.merckvetmanual.com/mvm/appendixes/reference_guides/serum_biochemical_reference_ranges.html). Accessed December 2021.
- [71] ISIS (International Species Information System). Ocelot (*Leopardus pardalis*) physiological reference ranges (both sexes, all ages). ISIS, Apple Valley, Minnesota. (2002).
- [72] G.A. Heidt, R.A. Rucker, M.L. Kennedy, M.E. Baeyens. Hematology, intestinal parasites, and selected disease antibodies from a population of bobcats (*Felis rufus*) in central Arkansas. J Wildl Dis. 24 (1988) 180-183. DOI: 10.7589/0090-3558-24.1.180
- [73] T.K. Fuller, K.D. Kerr, P.D. Karns. Hematology and serum chemistry of bobcats in northcentral Minnesota. J Wildl Dis. 21 (1985) 29-32. DOI: 10.7589/0090-3558-21.1.29.
- [74] A.A. Kocan, E.F. Blouin, B.L. Glenn. Hematologic and serum chemical values for free-ranging bobcats, *Felis rufus* (Schreber), with reference to animals with natural infection of *Cytauxzoon felis* Kier, 1979. J Wildl Dis. 21 (1985) 190-192.
- [75] S.T. Knick, E.C. Hellgren, U.S. Seal. Hematologic, biochemical, and endocrine characteristics of bobcats during a prey decline in southeastern Idaho. Canadian J Zool. 71 (1993). <https://doi.org/10.1139/z93-200>
- [76] L.E.K. Serieys, J. Foley, S. Owens, L. Woods, E.E. Boydston, L.M. Lyren, R.H. Poppenga, D.L. Clifford, N. Stephenson, J. Rudd, S.P.D. Riley. Serum chemistry, hematologic, and post-mortem findings in free-ranging bobcats (*lynx rufus*) with notoedric mange. J Parasitol. 99 (2013) 989-996. DOI: 10.1645/12-175.1
- [77] P. Moretti, S. Paltrinieri, E. Trevisi, M. Probo, A. Ferrari, A. Minuti, A. Giordano. Reference intervals for hematological and biochemical parameters, acute phase proteins and



markers of oxidation in Holstein dairy cows around 3 and 30 days after calving. *Res Vet Sci.* 114 (2017) 322-331. <https://doi.org/10.1016/j.rvsc.2017.06.012>

[78] J. Mariella, A. Pirrone, F. Gentilini, C. Castagnetti. Hematologic and biochemical profiles in standardbred mares during peripartum. *Therio.* 81:4 (2014) 526-34.  
<https://doi.org/10.1016/j.theriogenology.2013.11.001>

[79] H. Brommer, M.M. Sloet van Oldruitenborgh-Oosterbaan, B. Kessels. Haematological and blood biochemical characteristics of Dutch warmblood foals managed under three different rearing conditions from birth to 5 months of age. *Vet Q.* 23:2 (2001) 92-5.  
<https://doi.org/10.1080/01652176.2001.9695090>

[80] H.C. Brun-Hansen, A.H. Kampen, A. Lund. Hematologic values in calves during the first 6 months of life. *Vet Clin Pathol.* 35:2 (2006) 182-7. <https://doi.org/10.1111/j.1939-165x.2006.tb00111.x>

[81] E. Rosset, B. Rannou, G. Casseleux, K. Chalvet-Monfray, S. Buff. Age-related changes in biochemical and hematologic variables in Borzoi and Beagle puppies from birth to 8 weeks. *Vet Clin Pathol.* 41:2 (2012) 272-82. <https://doi.org/10.1111/j.1939-165x.2012.00415.x>

[82] J.K. Levy, P.C. Crawford, L.L. Werner. Effect of age on reference intervals of serum biochemical values in kittens. *J Amer Vet Med Assoc.* 228:7 (2007).  
<https://doi.org/10.2460/javma.228.7.1033>

[83] S.L. Stockham, M.A. Scott. *Fundamentals of Veterinary Clinical Pathology*, 2nd ed. Ames, IA: Blackwell. (2008).

[84] M.D. Willard, H. Tvedten, eds. *Small Animal Clinical Diagnosis by Laboratory Methods*, 4th ed. St. Louis, MO: Saunders. (2004).

[85] J.J. Kaneko, J.W. Harvey, M.L. Bruss. *Clinical Biochemistry of Domestic Animals*, 6th ed. San Diego, CA: Academic Press. (2008).

[86] K.S. [Latimer, E.A. Mahaffey, K.W. Prasse, eds. \*Duncan and Prasse's Veterinary Laboratory Medicine: Clinical Pathology\*, 4th ed. Ames, IA: Blackwell. \(2003\).](#)

- [87] B.F. Feldman, J.G. Zinkl, N.C. Jain, eds. Schalm's Veterinary Hematology, 5th ed. Philadelphia, PA: Lippincott Williams and Wilkins. (2000).
- [88] W.J. Reagan, A.R. Irizarry Rovira, D.B. DeNicola. Veterinary Hematology Atlas of Common Domestic and Non-Domestic Species, 2nd ed. Ames, IA: Wiley-Blackwell. (2008).
- [89] J.W. Harvey. Atlas of Veterinary Hematology: Blood and Bone Marrow of Domestic Animals. Philadelphia, PA: WB Saunders. (2001).
- [90] S.J. Ettinger, E.C. Feldman, eds. Textbook of Veterinary Internal Medicine, 6th ed. St. Louis, MO: Elsevier Saunders. (2005).
- [91] M.A. Thrall, D.C. Baker, T.W. Campbell, D.B. DeNicola. Veterinary Hematology and Clinical Chemistry: Text and Clinical Case Presentation. Ames, IA: Blackwell. (2006).
- [92] A. Bjöersdorff, L. Svendenius, J.H. Owens, R.F. Massung. Feline granulocytic ehrlichiosis – a report of a new clinical entity and characterization of the infectious agent. *J Small Anim Pract.* 40 (1999) 20-24. <https://doi.org/10.1111/j.1748-5827.1999.tb03249.x>
- [93] M.R. Lappin, E.B. Breitschwerdt, W.A. Jensen, B. Dunnigan, J.Y. Rha, C.R. Williams, M. Brewer, M. Fall. Molecular and serological evidence of *Anaplasma phagocytophilum* infection in cats in North America. *J Am Vet Med Assoc.* 225 (2004) 893-896. <https://doi.org/10.2460/javma.2004.225.893>
- [94] C. Savidge, P. Ewing, J. Andrews, D. Aucoin, M.R. Lappin, S. Moroff. *Anaplasma phagocytophilum* infection of domestic cats: 16 cases from northeastern USA. *J Feline Med Surg.* 18:2 (2015) 85-91. <https://doi.org/10.1177/1098612x15571148>
- [95] G. Baneth, A. Sheiner, O. Eyal, S. Hahn, J.P. Beaufils, Y. Anug, D. Talmi-Frank. Redescription of *Hepatozoon felis* (Apicomplexa: Hepatozoidae) based on phylogenetic analysis, tissue and blood from morphology, and possibly transplacental transmission. *Parasit Vectors.* 6:102 (2013). <https://doi.org/10.1186/1756-3305-6-102>
- [96] J.E. Foley, C.M. Leutenegger, J.S. Dumler, N.C. Pedersen, J.E. Madigan. Evidence for modulated immune response to *Anaplasma phagocytophila* sensu lato in cats with FIV-induced

immunosuppression. *Comp Immunol Microbiol Infect Dis.* 26 (2003) 103-113.

[https://doi.org/10.1016/s0147-9571\(02\)00023-1](https://doi.org/10.1016/s0147-9571(02)00023-1)

[97] S.K. Verma, L. Minicucci, D. Murphy, M. Carstensen, C. Humpal, P. Wolf, R. Calero-Bernal, C.K. Cerqueira-Cézar, O.C. Kwok, C. Su, D. Hill, J.P. Dubey. Antibody Detection and Molecular Characterization of *Toxoplasma gondii* from Bobcats (*Lynx rufus*), Domestic Cats (*Felis catus*), and Wildlife from Minnesota, USA. *J Eukary Microbiol.* 63:5 (2016) 567–571.

<https://doi.org/10.1111/jeu.12301>

[98] S.K. Verma, A.R. Sweeny, M.J. Lovallo, R. Calero-Bernal, O.C. Kwok, T. Jiang, C. Su, M.E. Grigg, J.P. Dubey. Seroprevalence, isolation and co-infection of multiple *Toxoplasma gondii* strains in individual bobcats (*Lynx rufus*) from Mississippi, USA. *Internat J Parasitol.* 47:5 (2017) 297–303.

<https://doi.org/10.1016/j.ijpara.2016.12.007>

[99] E.M. Mucker, J.P. Dubey, M.L. Lovallo, J.G. Humphreys. Seroprevalence of Antibodies to *Toxoplasma gondii* in the Pennsylvania Bobcat (*Lynx rufus rufus*). *J of Wildl Dis.* 42:1 (2006) 188–191.

<https://doi.org/10.7589/0090-3558-42.1.188>

[100] E. Rendón-Franco, A. Caso-Aguilar, N.G. Jiménez-Sánchez, D.M.B. Hernandez-Jauregui, A.L. Sandoval-Sánchez, H.M. Zepeda-López. Prevalence of anti-*Toxoplasma gondii* antibody in free-ranging ocelots (*Leopardus pardalis*) from Tamaulipas, Mexico. *J Wildl Dis.* 48:3 (2012) 829–831.

<https://doi.org/10.7589/0090-3558-48.3.829>

[101] J. Brister, L. Shell. Vincylopedia of Diseases: Toxoplasmosis. *Vincylopedia of Diseases.*

<https://www.vin.com/Members/Associate/Associate.plx?from=GetDzInfo&DiseaseId=814&pid=607>. (2019). Accessed June 2021.

[102] D. Spielman, B.W. Brook, D.A. Briscoe, R. Frankham. Does Inbreeding and Loss of Genetic Diversity Decrease Disease Resistance? *Conserv Genet.* 5:4 (2004) 439–448.

<https://doi.org/10.1023/B:COGE.0000041030.76598.cd>

[103] J. Dubey, W. Quinn, D. Weinandy. Fatal neonatal toxoplasmosis in a bobcat (*Lynx rufus*).

*J Wildl Dis.* 23:2 (1987) 324–327. <https://doi.org/10.7589/0090-3558-23.2.324>

- [104] G. Desmonts, J. Couvreur. Congenital toxoplasmosis. A prospective study of 378 pregnancies. *The New England J Med.* 290:20 (1974) 1110–1116.  
<https://doi.org/10.1056/NEJM197405162902003>
- [105] D. Dunn, M. Wallon, F. Peyron, E. Petersen, C. Peckham, R. Gilbert. Mother-to-child transmission of toxoplasmosis: risk estimates for clinical counselling. *Lancet* (London, England). 353: 9167 (1999) 1829–1833. [https://doi.org/10.1016/S0140-6736\(98\)08220-8](https://doi.org/10.1016/S0140-6736(98)08220-8)
- [106] S.P. Franklin, J.L. Troyer, J.A. Terwee, L.M. Lyren, W.M. Boyce, S.P.D. Riley, M.E. Roelke, K.R. Crooks, S. VandeWoude. Frequent transmission of immunodeficiency viruses among bobcats and pumas. *J Virol.* 81 (2007) 10961-10969
- [107] Y. Nishimura, Y. Goto, K. Yoneda, Y. Endo, T. Mizuno, M. Hamachi, H. Maruyama, H. Kinoshita, S. Koga, M. Komori, S. Fushuku, K. Ushinohama, M. Akuzawa, T. Watari, A. Hasegawa, H. Tsujimoto. Interspecies transmission of feline immunodeficiency virus from the domestic cat to the Tsushima cat (*Felis bengalensis euphilura*) in the wild. *J Virol.* 73:9 (1999) 7916-7921. <https://doi.org/10.1128/jvi.73.9.7916-7921.1999>
- [108] M.A. Carpenter, S.J. O'Brien. Coadaptation and immunodeficiency virus: lessons from the Felidae. *Curr Opin Genet Dev.* 5 (1995) 739-745. [https://doi.org/10.1016/0959-437X\(95\)80006-Q](https://doi.org/10.1016/0959-437X(95)80006-Q)
- [109] M.J. Burkhard, G.A. Dean. Transmission and immunopathogenesis of FIV in cats as a model for HIV. *Curr HIV Res.* 1 (2003) 15–29. <https://doi.org/10.2174/1570162033352101>
- [110] M.E. Roelke, M.A. Brown, J.L. Troyer, H. Winterbach, C. Winterbach, G. Hemson, D. Smith, R.C. Johnson, J. Pecon-Slattery, A.L. Roca, K.A. Alexander, L. Klein, P., Martelli, L. Krishnasamy, S.J. O'Brien. Pathological manifestations of feline immunodeficiency virus (FIV) infection in wild African lions. *Virol.* 390 (2009) 1–12.  
<https://doi.org/10.1016/j.virol.2009.04.011>
- [111] M.E. Roelke, J. Pecon-Slattery, S. Taylor, S. Citino, E. Brown, C. Packer, S. Vandewoude, S.J. O'Brien. T-lymphocyte profiles in FIV-infected wild lions and pumas reveal CD4 depletion. *J Wildl Dis.* 42 (2006) 234–248; <https://doi.org/10.7589/0090-3558-42.2.234>

- [112] M.W. Dryden. Mite infestation (mange, acariasis, scabies) of cats. In Merck Veterinary Manual. (2018). <https://www.merckvetmanual.com/cat-owners/skin-disorders-of-cats/mite-infestation-mange,-acariasis,-scabies-of-cats>
- [113] S. Hirst. Studies on acari; no.1, the genus Demodex, Owen London (United Kingdom): The British Museum. (1919). <http://dx.doi.org/10.5962/bhl.title.23700>
- [114] N. Sastre, O. Francino, J.N. Curti, T.C. Armenta, D.L. Fraser, R.M. Kelly, E. Hunt, K. Silbermayr, C. Zewe, A. Sanchez, L. Ferrer. Detection, prevalence and phylogenetic relationships of *Demodex* spp and further skin prostigmata mites (Acari, Arachnida) in wild and domestic mammals. *PLoS One*. 11:11 (2016) 1–20. <https://pubmed.ncbi.nlm.nih.gov/27802314>
- [115] J.N. Izdebska. A new demodecidae species (Acari) from the yellow-necked mouse *Apodemus flavicollis* (Rodentia: Muridae)—description with data on parasitism. *J Parasitol*. 98:6 (2012) 1101–1104. <https://doi.org/10.1645/GE-3018.1>
- [116] J.N. Izdebska, S. Fryderyk. New data on the occurrence of *Demodex lacrimalis* (Acari, Demodecidae) of the wood mouse *Apodemus sylvaticus* (Rodentia, Muridae). *Annales Universitatis Mariae Curie-Sklodowska. Sectio C: Biologia* 67:1 (2012) 7–11. <http://dx.doi.org/10.2478/v10067-012-0008-x>
- [117] J.N. Izdebska, P. Kozina, A. Gólcz. The occurrence of *Demodex* spp. (Acari, Demodecidae) in the bank vole *Myodes glareolus* (Rodentia, Cricetidae) with data on its topographical preferences. *Ann Parasitol*. 59:3 (2013) 129–133. PMID: 24881283
- [118] J.N. Izdebska, L. Rolbiecki. Demodectic mites of the brown rat *Rattus norvegicus* (Berkenhout, 1769) (Rodentia, Muridae) with a new finding of *Demodex ratticola* Bukva, 1995 (Acari, Demodecidae). *Ann Parasitol*. 58:2 (2012) 71–74. PMID: 25165758
- [119] J.N. Izdebska, L. Rolbiecki. A new species of *Demodex* (Acari: Demodecidae) with data on topical specificity and topography of demodectic mites in the striped field mouse *Apodemus agrarius* (Rodentia: Muridae). *J Med Entomol*. 50:6 (2013) 1202–1207. <https://doi.org/10.1603/me13044>
- [120] R. Matheson. Medical Entomology, 2nd Edition. Comstock Publishing Company, Inc. Ithaca, NY. (1950).

- [121] J. Piesman, K.L. Gage. Ticks and mites and the agents they transmit. The Biology of Disease Vectors. Beaty BJ, Marquardt WC (editors). University Press of Colorado. Newot, CO. (1996) 160-174.
- [122] D.D. Bowman, R.C. Lynn, M.L. Eberhard. Georgis' parasitology for veterinarians. 8th ed. St Louis: Saunders. (2003) 1– 114.
- [123] R. Atwell. Merck veterinary manual. Overview of tick paralysis. Available at: [www.merckvetmanual.com/nervoussystem/tick-paralysis/overview-of-tick-paralysis](http://www.merckvetmanual.com/nervoussystem/tick-paralysis/overview-of-tick-paralysis). (2018). Accessed Dec 10, 2018.
- [124] M.E. Persky, Y.S. Jafarey, S.E. Christoff, D.D. Maddox, S.A. Stowell, T.M. Norton. Tick paralysis in a free-ranging bobcat (*Lynx rufus*). *JAVMA*. 256:3 (2020) 362-364. <https://doi.org/10.2460/javma.256.3.362>
- [125] M.P. Luttrell, L.H. Creekmore, J.W. Mertins. Avian tick paralysis caused by *Ixodes brunneus* in the southeastern United States. *J Wildl Dis*. 32 (1996) 133–136. <https://doi.org/10.7589/0090-3558-32.1.133>
- [126] D. Konjević, Z. Janicki, K. Severin, M. Stanko, T. Zivicnjak, A. Slavica, V. Staresina. An outbreak of tick paralysis in free-ranging mouflon (*Ovis ammon musimon*). *J Zoo Wildl Med*. 38:4 (2007) 585–587. <https://doi.org/10.1638/2007-0022r.1>
- [127] E.F. Blouin, A.A. Kocan, B.L. Glenn, K.M. Kocan, J.A. Hair. Transmission of *Cytauxzoon felis* Kier, 1979 from bobcats, *Felis rufus* (Schreber), to domestic cats by *Dermacentor variabilis*. *J Wildl Dis*. 20:3 (1984) 241-242. <https://doi.org/10.7589/0090-3558-20.3.241>
- [128] C.E. Greene. Tularensis. In Greene CE (ed): Infectious Diseases of the Dog and Cat, 4th ed. St. Louis: Elsevier Saunders. (2012) 476-484.
- [129] M.R. Lappin, E.B. Breitschwerdt. *Ehrlichia* spp infection (feline monocytotropic ehrlichiosis). In Green CE (ed): Infectious Diseases of the Dog and Cat, 4th ed. St. Louis: Elsevier Saunders. (2012) 238-241.
- [130] S.E. Little. Ehrlichiosis and anaplasmosis in dogs and cats. *Vet Clin North Am Small Anim Pract*. 40:6 (2010) 1121-1140. <https://doi.org/10.1016/j.cvsm.2010.07.004>

- [131] M.V. Reichard, J.H. Meinkoth, A.C. Edwards, .T.A. Snider, K.M. Kocan, E.F. Blouin, S.E. Little. Transmission of *Cytauxzoon felis* to a domestic cat by *Amblyomma americanum*. *Vet Parasitol.* 161:1-2 (2009) 110-115. <https://doi.org/10.1016/j.vetpar.2008.12.016>
- [132] M.V. Reichard, A.C. Edwards, J.H. Meinkoth, T.A. Snider, K.R. Meinkoth, R.E. Heinz, S.E. Little. Confirmation of *Amblyomma americanum* (Acari: *Ixodidae*) as a vector for *Cytauxzoon felis* (Piroplasmorida: *Theileriidae*) to domestic cats. *J Med Entomol.* 47:5 (2010) 890-896. <https://doi.org/10.1603/me10013>
- [133] Y. Nagamori, M.V. Reichard. Parasitology expertise from the NCVP: feline tick-borne diseases. *Today's Vet Pract.* 5 (2015) 69–74.
- [134] M.W. Dryden. Fleas in dogs and cats. In Merck Veterinary Manual. 2021. Accessed August 2022. <https://www.merckvetmanual.com/integumentary-system/fleas-and-flea-allergy-dermatitis/fleas-in-dogs-and-cats>
- [135] P.G. Koehler, R.M. Pereira, P.E. Kaufman. Sticktight flea, *Echidnophaga gallinacea*. *Entomol Nematol.* (2018). Accessed August 2022. <https://edis.ifas.ufl.edu/publication/MG236>

## Appendix 1

**Table 1-A. Previously published hematologic and serum biochemical values of ocelots and domestic cats.**

Parameter	Free-Ranging Ocelots <sup>a</sup>			Captive Ocelots <sup>b</sup>			Domestic Cats <sup>d,e</sup>
	n	Range	Mean ±SD	n	Range	Mean ±SD	Range
Urea nitrogen (mg/dL)	8	24.6-37.3	31.7 ± 4.4	131	5.4-22.9	11.4 ± 3.2	6.8-12.1
Creatinine (mg/dL)	8	0.6-1.1	0.9 ± 0.2	128	0.7-2.8	1.6 ± 0.44	0.8-1.9
ALT (U/L)	8	33-117	65 ± 28.8	129	19-269	66 ± 41	25-97
Glucose (mg/dL)							
Total protein (g/dL)	8	7.4-11.3	9.2 ± 1.3	120	5.6-10	7.4 ± 0.7	6.0-7.9
Albumin (g/dL)	8	2.2-2.8	2.5 ± 2.16	108	2.2-4.6	3.3 ± 0.4	2.8-3.9
Globulin (g/dL)	8	5.0-9.1	6.7 ± 1.3	107	2.4-6.7	4.1 ± 0.7	2.6-5.1
HCT (%)	8	30-40	35 ± 3	136	30-50	38 ± 5	30-45
RBC conc. (10 <sup>6</sup> /μL)	7	5.5-7.1	6.4 ± 0.5	107	5.1-10.8	7.4 ± 1.1	5.0-10.0
Hemoglobin (g/dL)	7	9.5-13.1	11.4 ± 1.15	114	9.4-17.1	12.5 ± 1.7	9.8-15.4
MCV (fL)	8	42.3-60	52.3 ± 6.6	106	42.9-62.8	51.2 ± 4.3	39-55
MCHC (g/dL)	7	31.2-36.4	33.3 ± 1.9	113	23.8-39.6	33.2 ± 2.3	30-36
MCH (pg)	8	13.4-22.4	18.4 ± 3.0	105	12.7-21.8	17.0 ± 1.7	13-17
WBC conc. (10 <sup>3</sup> /μL)	8	12.1-19.8	17.7 ± 2.6	134	4.62-23.3	10.2 ± 3.5	5.5-19.5
Neutrophil (10 <sup>3</sup> /μL)	8	7.4-15.9	12.0 ± 2.9	121	0.11-20.7	6.96 ± 2.86	2.5-12.5
Lymphocyte (10 <sup>3</sup> /μL)	8	1.5-8.7	4.3 ± 2.4	126	0.46-7.61	2.48 ± 1.57	1.5-7.0
Monocyte (10 <sup>3</sup> /μL)	8	0.5-1.6	0.9 ± 0.35	102	0.05-2.62	0.28 ± 0.3	0.0-0.9
Eosinophil (10 <sup>3</sup> /μL)	7	0.0-0.9	0.1 ± 0.31	100	0.00-3.63	0.42 ± 0.48	0.0-0.8
Basophil (10 <sup>3</sup> /μL)	8	0.0	0.0	7	0.00-0.37	0.16 ± 0.13	0.0-0.2
Platelet conc. (10 <sup>3</sup> /μL)	8	280-694	396.7 ± 147.1	38	88-581	293.0 ± 105.0	300-800

Abbreviations: SD, standard deviation; SE, standard error; ALT, alanine transaminase; HCT, hematocrit; RBC, red blood cell; MCV, mean cell volume; MCHC, mean cell hemoglobin concentration; MCH, mean cell hemoglobin; RDW, red cell distribution width; WBC, white blood cell; conc., concentration. <sup>a</sup> [71]; <sup>b</sup> [74]; <sup>d,e</sup> [72-73]



**Table 1-B. Previously published hematologic and serum biochemical values of bobcats.**

Parameter	Free-Ranging Bobcats <sup>a</sup>		Free-Ranging Bobcats <sup>b</sup>		Captive Bobcats <sup>c</sup>			Free-Ranging Bobcat <sup>d</sup>	
	n	Mean ±SD	n	Mean ±SD	n	x	SE	n	Mean±SD
Urea nitrogen (mg/dL)	11	39 ± 10.1	11	31.4 ± 9.4	67	29.15	9.03	25	34.4 ± 7.9
Creatinine (mg/dL)	11	2.0 ± 1.1	11	0.7 ± 0.5	66	2.85	2.65	20	0.90 ± 0.31
ALT (U/L)	11	71 ± 35.1	11		45	26.7	10.13		
Glucose (mg/dL)	11	212.4 ± 82.6	11	101.8 ± 70.1	67	134.4	26.6	25	157.2 ± 54.4
Total protein (g/dL)	11	7.3 ± 0.3	11	7.1 ± 0.2	63	5.94	0.68	25	6.68 ± 0.73
Albumin (g/dL)	11	3.4 ± 0.3	11	3.6 ± 0.2	61	2.42	0.26	24	3.59 ± 0.58
Globulin (g/dL)	9	3.9 ± 0.3	11	4.4 ± 0.7	61	3.47	0.46	24	3.19 ± 0.78
HCT (%)	11	10.1 ± 3.7	11	36.6 ± 4.5	128	36.44	5.6	25	38.72 ± 4.37
RBC conc. (10 <sup>6</sup> /μL)			11	6.1 ± 4.5	172	8.03	1.1	17	7.98 ± 1.46
Hemoglobin (g/dL)			11	13.1 ± 1.6	135	11.75	1.5	25	13.3 ± 1.57
MCV (fL)			11	59.5 ± 4.1	110	44.42	4.5	17	49.35 ± 10.49
MCHC (g/dL)			11	21.5 ± 4.0	119	32.36	2.1	25	34.52 ± 2.43
MCH (pg)			11	36.1 ± 3.2	119	14.28	0.73	15	17.4 ± 4.07
WBC conc. (10 <sup>3</sup> /μL)	11	13.9 ± 4.0	11	10.6 ± 6.5	172	11.88	4.5	15	15.81 ± 5.04
Neutrophil (10 <sup>3</sup> /μL)	11	11.6 ± 4.3	11	8.27 ± 4.16	124	7.44	11.9	6	14.04 ± 1.02
Lymphocyte (10 <sup>3</sup> /μL)	11	1.5 ± 0.8	11	2.16 ± 8.12	123	3.58	11.6		
Monocyte (10 <sup>3</sup> /μL)	11	0.4 ± 0.2	11	0.69 ± 1.06	105	0.27	1.6		
Eosinophil (10 <sup>3</sup> /μL)	11	0.4 ± 0.2	11	3.07 ± 6.96	144	0.67	4.0		
Basophil (10 <sup>3</sup> /μL)	11	0.0 ± 0.0	11	0.26 ± 0.29	44	0.09	0.41		
Platelet conc. (10 <sup>3</sup> /μL)	11	402.8 ± 74							

Abbreviations: SD, standard deviation; SE, standard error; ALT, alanine transaminase; HCT, hematocrit; RBC, red blood cell; MCV, mean cell volume; MCHC, mean cell hemoglobin concentration; MCH, mean cell hemoglobin; RDW, red cell distribution width; WBC, white blood cell; conc., concentration. <sup>a</sup> [78]; <sup>b</sup> [75]; <sup>c</sup> [70]; <sup>d</sup>[76]

**Chapter II: Urethral catheterization of free-ranging ocelots (*Leopardus pardalis*) and bobcats (*Lynx rufus*) in southern Texas for semen collection and characterization of normative seminal traits**

## Abstract

Recent studies of wild felid populations have shown loss of genetic variability over time, including southern Texas, where signs of decreased genetic diversity and inbreeding depression have been documented. Inbreeding depression may cause reduced semen quality of male felids, ultimately affecting reproductive success. Assisted reproductive technologies, such as semen collection and analysis, can enable detailed assessments of reproductive traits for individuals and populations. Traditionally, semen has been collected via electroejaculation (EEJ) for most feline species; however, a new method was recently developed using alpha-2 agonists to induce direct sperm release into the urethra, allowing collection by catheterization and decreasing the need for specialized equipment and training. The goal of this study was to assess the effectiveness of urethral catheterization (UC) and characterize normative seminal traits of wild ocelot and bobcat populations in southern Texas. Catheterization was conducted 20 to 40 minutes after anesthetic induction with a combination of intramuscular ketamine and medetomidine (alpha-2 agonist) and reproductive traits characterized. If semen collection was unsuccessful or the sample not viable, EEJ was performed for ocelots only. Semen collection was attempted with 31 adult felids (n=9 ocelots; n=22 bobcats). Sperm recovery was successful by UC in seven of nine ocelots (78%) and 14 of 22 bobcats (66%); and by EEJ for four of five ocelots (80%). Ocelot sperm quality for UC and EEJ collected samples (23.3 (0.66-269.5), 53.55 (0-152.5)  $\times 10^6$  sperm per ejaculate;  $40.33 \pm 10.98$  (SEM),  $58.1 \pm 12.8$  % normal morphology;  $40.75 \pm 13.31$ ,  $73.3 \pm 5.0$  % acrosome integrity;  $50 \pm 15.28$ ,  $83.8 \pm 2.4$  % motility) did not differ by season ( $p > 0.05$ ), but were decreased compared to a more genetically diverse population managed under human care. Bobcat seminal quality (0.33 (0.003-36.8)  $\times 10^6$  sperm per ejaculate;  $23.31 \pm 3.94$  % normal morphology;  $40.54 \pm 4.36$  % acrosome integrity;  $14.8 \pm 5.1$  % motility), was similar to other reports in the lynx genus and total sperm concentration (Winter (W):  $1 (0-56) \times 10^6$  sperm/ml; Spring (S):  $31.5 (0.125-125.5) \times 10^6$  sperm/ml;  $p=0.014$ ) and total sperm per ejaculate (W:  $0.067 (0-3.08) \times 10^6$ ; S:  $0.374 (0.003-36.8) \times 10^6$ ;  $p=0.043$ ) were higher during the spring months. Catheterization was effective for the collection of semen samples and description of seminal traits for both species, however EEJ remained superior for the collection of greater quality sperm when employed and with the presence of urine contamination for ocelots.

## Introduction

Recent studies of wild felid populations have shown loss of genetic variability over time, including in southern Texas, where signs of decreased genetic diversity and inbreeding depression have been documented in ocelot (*Leopardus pardalis*) populations [1-3]. Genetic drift and inbreeding compromise fitness and interact with demographic irregularity to further reduce viability of populations [4-6]. The small population size in Texas coupled with its isolation has increased the effects of drift and inbreeding leading to low genetic diversity when compared to genetically diverse populations [2]. Although bobcats (*Lynx rufus*) in Texas have greater genetic diversity than ocelot populations in the same region, small populations of bobcats along the Lower Rio Grande Valley demonstrated declines in their genetic variation as well [7]. Bobcats range extends from southern Canada to northern Mexico and throughout the US [8], and although listed as a species of least concern according to the IUCN Red List of Threatened Species [9], the primary threat to their declining population numbers is loss of habitat, similar to ocelots. Like many wild felids before them, bobcats could one day face dramatic population declines and inbreeding depression, making conservation initiatives for their species important for future persistence in the wild.

Inbreeding depression may cause reduced semen quality of male felids, ultimately decreasing reproductive success. Reproductive examination and semen analysis allows description of reproductive traits to assess the possible impact of inbreeding depression on various aspects of semen quality and viability. Seminal traits in felines are characterized by testicular volume, ejaculate concentration and volume, sperm motility and forward progression, penile and sperm morphology, acrosome status, and serum testosterone concentrations. Reduced seminal qualities including structurally defective spermatozoa [10-13], reduced ejaculate sperm concentration [12], loss of total motile sperm [14] and higher acrosomal defects rendering sperm deficient in fertilization potential [14-16] have been observed in other wild felid populations with reduced genetic variation. A decrease in semen quality could prevent successful conception, ultimately limiting further population growth. Assisted reproductive technology (ART), specifically semen collection and analysis, can enable detailed assessments of reproductive traits for individuals and populations, but may require technique modification for practical field use [17].

Semen collection and assessment in felids is an important step in breeding programs and the development of alternate techniques has been described over the last few years [18-19;20]. To date, the most common methods for sperm collection in the tomcat are electroejaculation (EEJ) [16, 21] or artificial vagina (AV) [22-23]. Although the training for AV use was successful in a cheetah [24], this method is not practical in free-ranging felids due to lack of trainability, absence of a queen [25], and most importantly, felid demeanor. Electroejaculation has been performed successfully and repeatedly in domestic cats and virtually all non-domestic felid species [26-29] maintained under human care in zoos, ranging in body size from the tiger (*Panthera tigris*) down to the black-footed cat (*Felis nigripes*) [29] and in free-ranging males, including cheetahs (*Acinonyx jubatus*) [30]. Currently, EEJ is the method of choice in untamed or free ranging species [31-34]; however, it is less practical in the field than UC as it requires species specific rectal probes for effective application, additional costs, expertise, and permission from ethical-scientific committees [28,35]. The development of additional, cost-effective techniques requiring fewer materials and less expertise would benefit the objectives of ocelot conservation and provide baseline reproductive information for free-ranging bobcats for utilization in the future. One technique that has been successful in other species is the use of specific pharmaceuticals for sperm release and subsequent semen collection.

The use of pharmacologic agents for ejaculation and semen collection has been successful in other species such as the horse [36-38], domestic felids [25], domestic canids [39], and white rhinoceros [40]. One group of pharmaceuticals, alpha-2 adrenergic agonists ( $\alpha_2$  agonists), are reported to influence erection [40-41], the ejaculatory reflex [41] and act on the smooth muscle at the level of the vas deferens [42] by contraction, forcing semen into the pelvic urethra [28]. When conducting field-based studies on non-domestic felids, immobilization can be achieved using many combinations of pharmaceuticals, especially  $\alpha_2$  agonists. Medetomidine, a potent  $\alpha_2$  agonist, is used commonly in non-domestic felids for immobilization. While medetomidine is a highly selective  $\alpha_2$  agonist [43], dexmedetomidine has even greater specificity for  $\alpha_2$  receptors [44] and requires a lower dosage per body weight, but may be cost prohibitive. Medetomidine provides a more cost-effective option and is shown in previous studies [25, 28] to yield good quality semen despite its lower selectivity when compared to dexmedetomidine.

An alternative method for semen collection involving urethral catheterization (UC) of male cats following treatment with medetomidine sedation was recently developed and reported to be successful in domestic felids [25]. This technique has allowed the recovery of high sperm numbers in domestic cats [25], jungle cats [45], Amur leopard cats [46], lions [47], and other non-domestic felids [48-49; unpublished data]. Semen collected by urethral catheterization was characterized by a lower volume, higher sperm concentration, and lower pH compared to collection by EEJ due to the lack of seminal fluids. Spermatozoa characteristics of frozen-thawed semen samples did not differ between the two methods of collection [25]. Urethral catheterization under medetomidine sedation, if proven effective across species, could provide a cost-effective and simplified technique that could be valuable for imperiled felid conservation globally.

Our objectives were to assess the feasibility of UC under an immobilization protocol that utilizes medetomidine as a technique for semen collection in the field setting and evaluate seminal traits of free-ranging Texas ocelots and bobcats for the first time. Further, we aimed to assess the impact of decreased genetic diversity and inbreeding on reproductive fitness of the ocelot populations in southern Texas as compared to a genetically diverse ocelot population managed in North American Zoos. Ocelots in North American Zoos are heavily managed as a part of the species survival plan in which pairings are made by genetic recommendations to maintain genetic diversity creating sustainable populations within human care. As there is no known information regarding male bobcat seminal traits, we sought to characterize these traits and assess these reproductive procedures for future use should the population experience a decline like many other imperiled feline species.

## **Materials and Methods**

### *Animals*

Adult male wild cats (n=31), representing 2 species from 2 genera (*Leopardus*: ocelot, n=9; *Lynx*: bobcat, n=22) were used in this study. Free-ranging felids were captured using modified Tomahawk traps (Tomahawk Live Trap Co., Tomahawk, Wisconsin, USA) on private ranches in Willacy and Kenedy counties in southern Texas and the Laguna Atascosa National Wildlife Refuge (LANWR). A hardware cloth extension measuring 51 cm X 38 cm X 51 cm was added to the trap to contain a live pigeon or small chicken that was provided water and feed

*ad libitum*. Traps were checked each morning following sunrise to ensure processing and release of captured animals by early to mid-afternoon. All animal use was approved by and in accordance with the policies of the Institutional Animal Care and Use Committee (IACUC) at Texas A&M University– Kingsville (TAMUK), Caesar Kleberg Wildlife Research Institute (CKWRI), and the University of Tennessee- Knoxville and the study was permitted by the United States Fish and Wildlife Service (USFWS).

#### *Semen collection and trait assessment*

Male ocelots and bobcats were immobilized and maintained at a light anesthetic plane for semen collection procedures. The anesthetic protocol consisted of an injectable combination of ketamine hydrochloride (target dosage: ocelot, 4 to 8 mg/kg bodyweight; bobcat, 2.5 to 5 mg/kg bodyweight; Wedgewood Pharmacy: Wildlife Pharmaceuticals, Inc. and ZooPharm, Swedesboro NJ) and medetomidine hydrochloride (target dosage: ocelot, 0.05 mg/kg bodyweight; bobcat, 0.06 mg/kg bodyweight; Wedgewood Pharmacy: Wildlife Pharmaceuticals, Inc. and ZooPharm, Swedesboro NJ) given intramuscular (i.m.) via pole syringe or hand injection followed by partial reversal with atipamezole (i.m.) (target dosage: 5 mg of atipamezole for every 1 mg of medetomidine given; Wedgewood Pharmacy: Wildlife Pharmaceuticals, Inc. and ZooPharm, Swedesboro NJ). Fasting prior to the anesthetic event was not possible due to free-ranging nature. Body temperature, heart rate, respiratory rate, pulse oximetry, jaw tone, and capillary refill time were monitored throughout the procedure.

Both testicles were palpated by hand for firmness and recorded on a 1-3 scale: 1) hard 2) normal and 3) flaccid. The length and width of each testicle was measured in millimeters using calipers [Figure 2.1], the volume of each testis calculated using the following elliptical equation: length (L) X width (W)<sup>2</sup> X 0.524 (LTVOL; RTVOL) and each volume added together for the total testicular volume (TTVOL, cm<sup>3</sup>). Relative testes weight (RTWT) was calculated as total testes volume (cm<sup>3</sup>) per kg of body weight. Approximately 20 to 40 minutes post anesthetic injection, the penis was extruded with manual manipulation and sterile gloves, debris removed with a water-soaked gauze and the penis examined for the presence or absence of penile spines [Figure 2.1] and hygiene. A 3.5 or 5 French (1.2 or 1.7 mm diameter, respectively) modified urinary catheter was advanced approximately 13-15 cm into the urethra [Figure 2.1], left in place for 30 seconds and slowly removed [25]. If collection of an ejaculate was unsuccessful or

not viable by UC, one to three series of electroejaculation (EEJ) (2-5 V; 10 stimulations per series) was performed using a standardized technique [50] with slight modifications [51-52] for ocelots.

Semen samples were assessed using a standardized technique [29] with slight modifications. The recovered catheter sample was transferred into an Eppendorf vial using a one mL syringe and a small amount of air. Seminal volume (VOL) was measured using a micro pipettor and assessed initially for the presence or absence of spermatozoa. Urine contamination was determined by pH ( $\leq 6.5$ ), discoloration, and/or a low motility ( $< 10\%$ ) and forward progression (1/5) of sperm. For spermic samples, motility (percent progressively motile, PPM; 0-100%) and rate of forward progressive motility (FPM; scale of 0-5, with 0 being non-motile and 5 being rapid forward progression) were evaluated microscopically using raw aliquots from each sample [53-54]. A subset of raw semen (1 - 3 $\mu$ L) was fixed in 49  $\mu$ l of 0.3% glutaraldehyde and assessed with phase microscopy at 400X magnification (100-200 sperm/sample) to determine percentage of spermatozoa with normal morphology (MORPH) [**Figure 2.2**]. Sperm morphology was documented on a Zeiss Axioskop Fluorescent microscope equipped with an AxioCam 202 monocular camera using positive phase contrast 40X objective or 100X objective with oil. A subset of raw semen was placed into water at a 1:400 dilution to determine sperm concentration (CONC) using a hemocytometer method. Total sperm per ejaculate (TSE) was calculated by multiplying the VOL and CONC. An aliquot (4  $\mu$ l) of raw semen was spread onto a microscope slide, dried at room temperature, stained with fluorescein isothiocyanate-peanut agglutinin (Sigma-Aldrich Corporation, St. Louis, MO), and assessed with fluorescent microscopy (100-200 sperm/sample) to determine percentage of intact acrosomes (ACRO) [55]. Acrosome status was classified as intact, partially intact or not intact [**Figure 2.3**]; and was assessed using fluorescence (excitation 465-495/emission  $> 515$ ) on a Zeiss Axioskop Fluorescent microscope equipped with AxioCam ERc5s. All images were obtained and processed using Zen 3.1 (blue edition; Carl Zeiss Microscopy GmbH, Germany).

#### *Fecal and Serum Testosterone Analysis*

#### Fecal and Serum Sample Collection and Processing [56]

Fecal and serum samples were collected from wild individuals that were anesthetized for semen collection and physical exam. Samples were collected and placed into cryovials with



animal ID and date and stored at -20 °C until processing. Fecal samples were lyophilized via a freeze dryer (Virtis, Gardener, NY, USA) in their cryovials, pulverized into a fine powder, and then weighed (250± 5mg) into labeled 15 ml polypropylene conical tubes. Each of the samples was then extracted by adding 2.5 ml of 90% ethanol (1:10 w:v) overnight on a mechanical rocker (≥12 h). Extracted samples were then centrifuged (1000g, 15 min), supernatants were pipetted off and samples stored in 2.0 ml cryovials at -20 °C until analysis. Serum samples were thawed, diluted in diethyl ether at 1:5, vortexed for 30 seconds, and placed in a -80 °C freezer for 10 min. The ether was then poured off into separate tubes, those tubes placed under a vacuum in a fume hood until dry (~ 1h), and then allowed to sit overnight. The samples were then reconstituted at a 1:1 dilution with EIA buffer (45.2 mM NaH<sub>2</sub>PO<sub>4</sub>, 61.0 mM Na<sub>2</sub>HPO<sub>4</sub>, 148 mM NaCl, 0.1% BSA, 0.0001% Proclin 150, 863.5 mM Tween 20) and stored in 2.0 ml cryovials at -20 °C until analysis.

### Enzyme Immunoassays

The Arbor Assays testosterone mini-kit (ISWE001, Arbor Assays, Ann Arbor, MI) was used to determine androgen levels (this kit included both antibody and horseradish peroxidase(HRP)). Cross reactivities for antitestosterone were testosterone 100%, dihydrotestosterone 35.4%, progesterone 0.024%, corticosterone <0.004, cortisol <0.004, cortisone <0.004, and 17β-estradiol <0.004 (Arbor Assays Testosterone Mini-Kit insert #ISWE001).

### Fecal Testosterone Analysis

For ocelot fecal analysis, small aliquots of sample were run in the assay from 1:80 – 1:250 dilution as determined by the parallelism for fecal testosterone in ocelots (1:16 – 1:512, R<sub>2</sub> = 0.999). There was a significant recovery (average of 74.4%) of exogenous testosterone added to ocelot fecal extracts ( $y = 0.99 + 0.149x$ , R<sub>2</sub> = 0.998). An inter-assay coefficient of variation (CV) of equal to or less than 10% was observed, with an intra-assay CV of 12.3%. For bobcat fecal analysis, small aliquots of sample were run in the assay from 1:25 - 1:50 as determined by the parallelism for fecal testosterone in bobcats (1:4 – 1:512, R<sub>2</sub> = 0.999). There was significant recovery (average of 76.84%) of exogenous testosterone added to bobcat fecal extracts ( $y = 1.16x + 0.22$ , R<sub>2</sub> = 0.999). An inter-assay CV of equal to or less than 10% and an intra-assay CV of 12.3% was observed.

## Serum Testosterone Analysis

Small aliquots of serum (50  $\mu$ l) were run neat in the testosterone assay as determined by the parallelism for serum testosterone in ocelots (neat – 1:4,  $R^2 = 0.999$ ). There was significant recovery (average of 78.75%) of exogenous testosterone added to ocelot serum extracts ( $y = 1.0x+0.139$ ,  $R^2 = 0.998$ ), and (average of 76.25%) for bobcats ( $y = 1.0x+0.13$ ,  $R^2 = 0.999$ ). The testosterone assay was incubated for 2 hours, plates were then run through a plate washer (AquaMax 2000, Molecular Devices, San Jose, CA, USA) with wash buffer (85.9 mM  $\text{Na}_2\text{HPO}_4 \cdot 7\text{H}_2\text{O}$ , 13.9 mM  $\text{NaH}_2\text{PO}_4 \cdot \text{H}_2\text{O}$ , 150.06 mM NaCl, 12.73 mM EDTA, 0.09% Proclin 150, 1.06% Tween 20), and 3,3',5,5'-tetramethylbenzidine (TMB, Sigma-Aldrich, St. Louis, MO, USA) was added to each well. After ~10 minutes of development, a solution of 3% hydrochloric acid (HCl) was added to each well to stop the reaction and the plate was then evaluated for optical density on a plate reader (VersaMax Absorbance microplate reader, Molecular Devices, San Jose, CA, USA) at 450 nm. Samples and standards were analyzed in duplicate. An inter-assay CV of equal to or less than 12.5% and an intra-assay CV of 12.3% was observed.

## *Statistical Analyses*

Normality was assessed using the Shapiro-Wilk test at a 95% confidence interval. If a normal distribution was reported, the mean values  $\pm$  SEM was reported in the results. If there was a non-normal distribution, the median (minimum-maximum) values were reported in the results. Mean anesthetic dosages, total testicular volumes, total testicular volumes to weight ratio, and mean ejaculate characteristics were calculated for both species. Non-parametric comparisons between species (for total testicular volumes, STEST, FTEST) was assessed using the Mann-Whitney U test for statistical significance. Parametric comparisons between species were assessed using independent samples t-tests (total testicular volume-to-weight ratios, percent normal morphology). Non-parametric correlations between medetomidine dosages and ejaculate output were assessed with the Spearman's rho correlation coefficient. Parametric correlations were assessed using Pearson correlation coefficient. Independent sample t-tests were used to compare if urine contamination affected the percentage of normal morphology. The effect of treatment (collection method) on various seminal traits was assessed using mixed model analysis (ANOVA) with a diagonal covariance structure and cat as a random factor. Seasonal effects

were assessed by using the Kruskal-Wallis test across months and Mann-Whitney test across season. All analyses were performed in SPSS 28 with an  $\alpha= 0.05$ .

## Results

### *Animals*

Mean  $\pm$  SEM anesthetic doses were as follows for each species: ocelot,  $9.19 \pm 1.01$  (range 4.93-15.83) mg/kg ketamine,  $0.062 \pm 0.006$  (range 0.031-0.1) mg/kg medetomidine, and  $0.30 \pm 0.042$  (range 0.00-0.505) mg/kg atipamezole; bobcat,  $4.72 \pm 0.52$  (range 2.63-11.98) mg/kg ketamine,  $0.07 \pm 0.002$  (range 0.052-0.095) mg/kg medetomidine, and  $0.036 \pm 0.027$  (range 0.00-0.722) mg/kg atipamezole. Urethral catheterization resulted in recovery of sperm samples from seven ocelots in nine attempts (78%) and 14 bobcats in 22 attempts (64%). Urine contamination occurred in 6 ocelot samples (86%) and 6 bobcat samples (43%). Of urine contaminated samples, two ocelot samples (33%) and zero bobcat samples (0%) remained viable (i.e., retained  $\geq 30\%$  motility). Electroejaculation resulted in recovery of sperm samples with four ocelots in five attempts (80%) with urine contamination of two samples (50%). Of urine contaminated samples using EEJ in ocelots, two ocelot samples (100%) remained viable (i.e., retained  $\geq 30\%$  motility).

### *Seminal traits*

The total testicular volume (TTVOL) varied significantly between species (ocelots,  $20.9 \text{ cm}^3$  (range 1.85-22.66) ; bobcats,  $2.37 \text{ cm}^3$  (range 0.47-5.25);  $p<0.001$ ). The total testicular volume to weight ratio varied significantly between species (ocelots,  $1.51 \pm 0.21 \text{ cm}^3/\text{kg}$ ; bobcats,  $0.29 \pm 0.03 \text{ cm}^3/\text{kg}$ ;  $p<0.001$ ). For samples collected by EEJ in ocelots, there was no correlation between total testicular volume and the volume of ejaculate ( $\rho= 0.389$ ,  $p=0.52$ ), sperm concentration ( $\rho= 0.546$ ,  $p=0.34$ ), and total sperm in the ejaculate ( $\rho= 0.664$ ,  $p=0.22$ ). For samples collected by UC, there was no correlation between total testicular volume and the volume of ejaculate (bobcat,  $\rho= 0.165$ ,  $p=0.51$ ; ocelot,  $\rho= 0.583$ ,  $p=0.10$ ), sperm concentration (bobcat,  $\rho= 0.210$ ,  $p=0.40$ ; ocelot,  $\rho= 0.214$ ,  $p=0.61$ ), and total sperm per ejaculate (bobcat,  $\rho= 0.316$ ,  $p=0.20$ ; ocelot,  $\rho= 0.238$ ,  $p=0.57$ ).

Penile spines were present for seven of nine (78%) ocelots and zero of 22 (0%) bobcats. The two male ocelots that did not have penile spines were estimated to be under the age of 2 and

therefore reproductively immature. Seminal results from all males are included in **Table 2.1**. Urine contamination of the sperm sample collected by UC did not significantly affect the percentage of normal morphology (RAW  $27.8 \pm 4.6$ , Urine Cont.  $29.4 \pm 5.0$ ;  $p = 0.83$ ), therefore urine contaminated samples were included in morphologic analysis. For ocelots, there was no significant difference in percent normal morphology (MORPH) ( $p=0.09$ ), secondary morphologic abnormalities ( $p=0.49$ ), and total morphologic abnormalities ( $p=0.09$ ) between sperm samples collected by either method, however, there was a significant difference in percentage of primary morphologic abnormalities between the two collection methods (UC =  $47.75 \pm 6.7$ ; EEJ =  $9 \pm 2.7$ ;  $p < 0.001$ ). For both species, the placement of sperm into FOCM-Hepes medium did not significantly improve the percentage of normal morphology of the sperm (RAW =  $27.8 \pm 4.6$ , FOCM =  $30.4 \pm 4.1$ ;  $p=0.68$ ), primary abnormalities ( $p=0.96$ ), secondary abnormalities ( $p=0.75$ ), and total abnormalities ( $p=0.54$ ) and there was not a significant difference between species for the percentage of normal morphology ( $p=0.12$ ). The most common sperm morphologic abnormality for ocelots, 57% (4/7) of males had a tightly coiled tail when collection method was UC and a 75% of males (3/4) had bent tails when collection method was EEJ. When urine contamination was present, the most common abnormality for ocelots was a bent tail regardless of collection method. For bobcats, the most common sperm morphological abnormality was a tightly coiled tail (93% of males) regardless of urine contamination.

There was no effect of urine contamination on percent motility ( $p=0.10$ ), however there was a significant effect of urine on forward progressive motility ( $p=0.01$ ; without urine 3 (0-4); with urine 0 (0-3.5)). There was no effect of urine contamination on percent motility ( $p=0.26$ ) and forward progressive motility ( $p=0.12$ ) for ocelots; however, there was a significant effect of urine contamination on percent motility ( $p=0.014$ ; without urine 5.5 (0-40); with urine 0 (0-10)) and forward progressive motility ( $p=0.013$ ; without urine 3 (0-4); with urine 0 (0-3)) for bobcats. There was a significant difference between collection method (UC vs EEJ) for percent normal morphology in ocelots ( $p=0.032$ ; **Table 2.1**).

There was not a dose effect of medetomidine on the total volume of ejaculate (ocelot:  $\rho = -0.067$ ,  $p = 0.87$ ; bobcat:  $\rho = -0.064$ ,  $p = 0.80$ ), total concentration of sperm (ocelot:  $\rho = 0.048$ ,  $p = 0.91$ ; bobcat:  $\rho = -0.142$ ,  $p = 0.57$ ), or total sperm per ejaculate (ocelot:  $\rho = 0.190$ ,  $p = 0.65$ ; bobcat:  $\rho = -0.243$ ,  $p = 0.33$ ) for either species. When assessing for seasonality,

differences were examined at the month level (Dec through Apr) and at the seasonal level (Winter (December-February) and Spring (March-April)). For ocelots, there was no effect of month or season on the total volume of ejaculate collected (M:  $p=0.13$ ; S:  $p=0.19$ ), total concentration of sperm (M:  $p=0.42$ ; S:  $p=0.39$ ), or total sperm per ejaculate (M:  $p=0.44$ ; S:  $p=0.39$ ). For bobcats, there was an effect of month (M) and season (S) on total volume of ejaculate collected by UC method (M:  $p=0.019$ ; S:  $p=0.001$ ) and an effect of season on total concentration of sperm ( $p=0.014$ ) and total sperm per ejaculate ( $p=0.043$ ), however there was no effect of month on the total concentration of sperm ( $p=0.08$ ) or total sperm per ejaculate ( $p=0.19$ ). Total volume was higher in the winter (W) than spring (S) (W: 170 (38-320)  $\mu$ l; S: 29.3 (10-60)  $\mu$ l), however total sperm concentration (W: 1 (0-56)  $\times 10^6$  sperm/ml; S: 31.5 (0.125-125.5)  $\times 10^6$  sperm/ml) and total sperm per ejaculate (W: 0.067 (0-3.08)  $\times 10^6$ ; S: 0.374 (0.003-36.8)  $\times 10^6$ ) were higher in the spring.

Mean  $\pm$  SEM serum and fecal testosterone concentrations for each species were as follows: ocelot, serum (0.314 (0.05-0.67) ng/ml) and fecal (239.32 (64.55-1406.25) ng/g); bobcat, serum (0.181 (0.063-0.660) ng/ml) and fecal (147.74 (39.8-459.56) ng/g). There was no difference between species for serum testosterone ( $p=0.45$ ) or for fecal testosterone ( $p=0.26$ ). There was not an effect of season (winter vs spring) on fecal or serum testosterone for bobcats (fecal,  $p=0.25$ ; serum,  $p=0.43$ ) or ocelots (fecal,  $p=0.25$ ; serum,  $p=0.43$ ). There was a significant and strong positive correlation between serum testosterone and total sperm per ejaculate ( $\rho=0.900$ ,  $p=0.037$ ) and total motile sperm ( $\rho=0.900$ ,  $p=0.037$ ) but no correlation between serum testosterone and sperm concentration ( $\rho=0.700$ ,  $p=0.188$ ) when collection method was EEJ. There was no correlation between serum testosterone and sperm concentration ( $\rho=-0.200$ ,  $p=0.704$ ), total sperm per ejaculate ( $\rho=-0.107$ ,  $p=0.819$ ), and total motile sperm ( $\rho=-0.036$ ;  $p=0.939$ ) for ocelots when semen was collected by UC. The correlation of fecal testosterone to sperm concentration, total sperm per ejaculate, and total motile sperm was unable to be assessed due to low sample size. There was no correlation between serum testosterone or fecal testosterone and sperm concentration ( $\rho=0.140$ ,  $p=0.664$ ;  $\rho=-0.511$ ,  $p=0.074$ ), total sperm per ejaculate ( $\rho=0.196$ ,  $p=0.542$ ;  $\rho=-0.236$ ,  $p=0.437$ ), and total motile sperm ( $\rho=-0.342$ ,  $p=0.452$ ;  $\rho=-0.485$ ;  $p=0.185$ ) for bobcats when semen was collected UC, respectively.

## Discussion

This study represents the first detailed assessment of reproductive traits in wild ocelot and bobcats living within their natural habitats. All previous research focused on evaluating wild-borne or captive-born ocelots and bobcats that were maintained under human care in zoos, with indeterminate impacts of multiple husbandry factors on measured reproductive characteristics. Of note, a total of nine male ocelots were evaluated in the current study, representing ~20% of the ocelot population thought to still survive in this region of the US [57-59]. To assess seminal characteristics, we used a newer method of semen collection (urethral catheterization) for both free-ranging ocelots and bobcats. Comparison of semen collection by urethral catheterization (UC) and electroejaculation (EEJ) revealed differences in ejaculate quality for ocelots. Overall, bobcats exhibited a low quality ejaculate following UC and differences were observed based on seasonal timing of collection. While ocelots produced a higher quality ejaculate as compared to bobcats, the overall seminal quality of this population was low compared to reports in human-managed ocelot populations [28; 60-61].

With the use of UC in ocelots, we were able to recover a high sperm concentration with a low volume of ejaculate and low pH, similar to previous studies in other feline species [25, 31, 53-55, 62]. Our primary challenge was urine contamination of UC samples, similar to previous reports [60-61]. Due to the lack of seminal fluids and the high osmolality of the catheter samples, we suspect the acidity and variable osmolality of the urine impacts sperm viability even when diluted immediately with an isotonic medium and centrifuged to remove urine in the supernatant. The addition of EEJ to the sampling protocol for ocelots allowed for recovery of higher sperm numbers with improved percent motility and progression, similar to other reports [60]. Samples collected by EEJ, while also frequently contaminated with urine, included a larger volume of seminal fluids and thus had a higher alkalinity and a lower osmolality, which may have provided a better buffer against urine contamination. For bobcats, urine contamination occurred less often (about half the time) than in ocelots using the UC method, however, EEJ was not included in the sampling protocol for bobcats so a comparison of methods could not be performed. Additionally, slightly reducing the distance of catheter insertion into the urethra (13-14 cm) from reported distances (ocelots, 15 cm; Canada lynx, 15 cm) [60, 63] did not result in less urine contamination in both species.

Urethral catheterization utilizes alpha-2-agonist medications such as medetomidine and dexmedetomidine [25], in which reported dosages of medetomidine used in previous studies yielding adequate sperm numbers in felids were 0.13-0.14 mg/kg [31] in domestic felines, which is 1.5 to 2 times higher than the dosages used in this study; and 0.05-0.11 mg/kg [53-55] in other feline species, similar to our dosages. Studies that have utilized dexmedetomidine for semen collection by UC method report dosages of 0.025 mg/kg in domestic cats [28, 34, 64-65], which is approximately four to five times less than the reported dosages of medetomidine that yielded adequate sperm numbers with no difference between the two drugs. Medetomidine is a racemic mixture of 2 enantiomers, d-MED and l-MED, in which d-MED (dexmedetomidine) is the active enantiomer [66]. Alternatively, dexmedetomidine is the pure d-MED enantiomer and has a higher binding affinity to  $\alpha_2$  receptors when compared to medetomidine [43, 67]. In other feline species, urine contamination was more likely to occur in samples collected by EEJ under the influence of medetomidine as compared to dexmedetomidine [68]; however, the addition of supplemental anesthetic medications (isoflurane and propofol) [68] and the electrical stimulus applied during EEJ could stimulate contraction of the bladder and subsequent urine contamination [47]. Although a dose affect was not shown using medetomidine in this study, it is possible that the increased affinity for  $\alpha_2$  receptors exhibited by dexmedetomidine could have an additional affect at the level of the urethral sphincter decreasing the likelihood of urine contamination, but this would need to be further explored. Additionally, increasing dosages of medetomidine to 0.13-0.14 mg/kg (i.m.) could increase sperm yield [66], however, additional caution should be taken with high dosages of  $\alpha_2$  agonist medications and their subsequent hemodynamic effects [70].

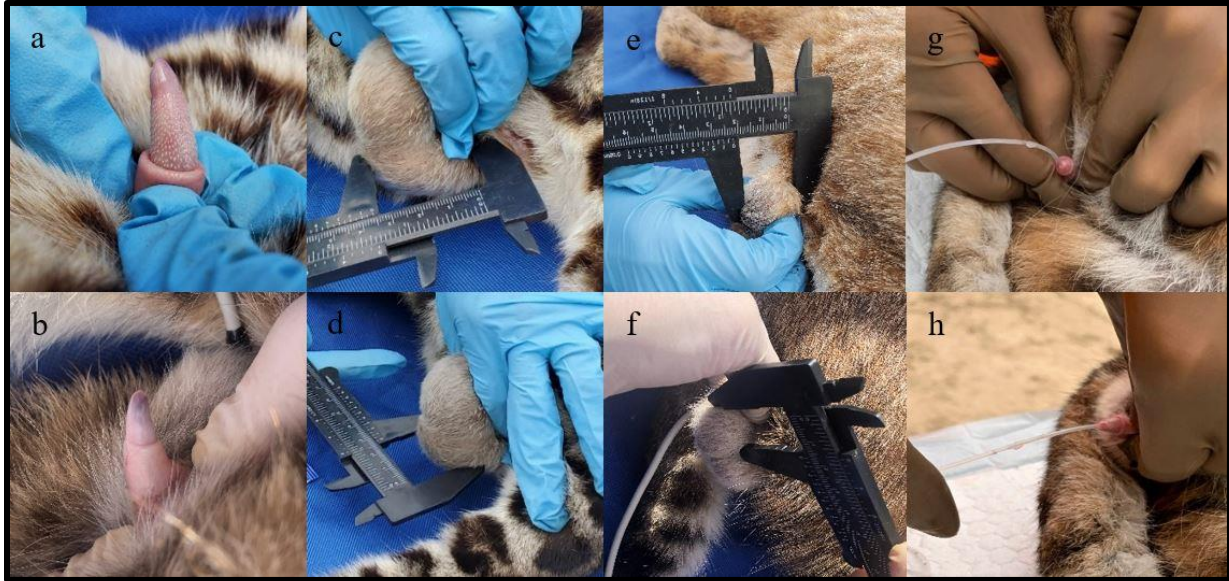In regard to physical reproductive traits, there was a large difference in testicular volume between species with ocelots having ~ 8 times the testicular volume when compared to bobcats. Although these two medium-sized felids are similar in body weight, the testicular size varied between species which is likely a species-specific difference. In canids [71-75], increased testicular size resulted in larger numbers of spermatozoa, but that was not the case when comparing three small felid species [76] or in our study within each species; however, in comparing the two species, ocelots exhibited higher numbers of sperm and a larger testicular volume than bobcats. There was no difference in serum testosterone concentrations between species, however ocelots displayed large, obvious penile spines, whereas bobcats did not. Penile

spines in felines are thought to function as stimulation for induced ovulation [35, 77] and as holdfast organs, comparable to the locking device in dogs [78-79]. As ocelots are induced ovulators with non-seasonal reproduction [76, 80-82], the presence of penile spines in this species likely functions for these previously stated purposes.

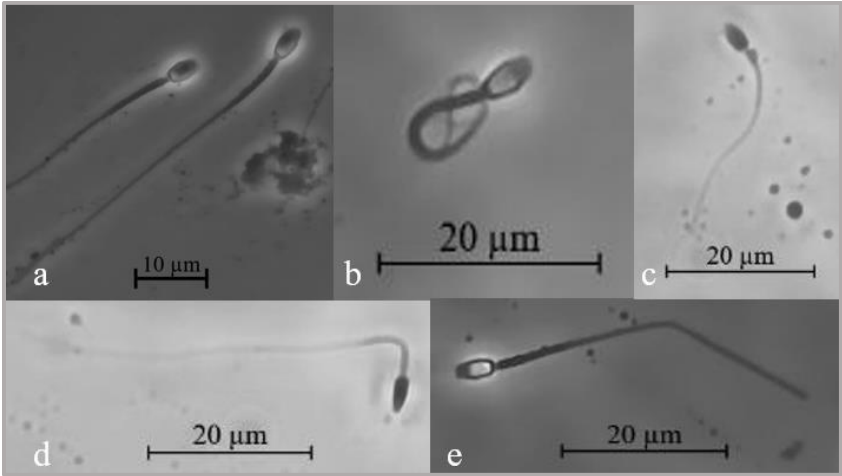
Bobcats are reported to be seasonal breeders, similar to their closely related relatives of the *Lynx* genus [84-85], but it is unknown whether they are spontaneous or induced ovulators. The absence of penile spines in bobcats appears to be species-specific [76] rather than androgen dependent [86]. In other studies [87] ovulation was induced in domestic feline females using a smooth glass rod suggesting that penile spines are not essential for ovulation induction although they may increase efficacy. Bobcats exhibited a higher volume of ejaculate in the winter months and a higher sperm concentration and total sperm per ejaculate in the spring months. Similar to other lynx species [84], bobcats appear to produce superior sperm numbers in the spring, however this could not be compared across all seasons due to the short window for trapping (November through April) each year and would need to be further examined in the summer and fall months. On the contrary, bobcats did not exhibit seasonality in their serum and fecal testosterone levels, similar to findings in human managed bobcat populations [85] and the Iberian lynx [89], in which their testosterone levels varied with age, but not season. The opposite was observed for Canada lynx [84] and Eurasian lynx [85] which showed seasonality in testosterone concentrations. The differences between lynx species suggest variation occurs at the species level, requiring caution with generalizations at the genus level for this group of felids.

Ocelots are non-seasonal breeders [76, 80-82] with reports of markedly increased fecal androgens compared to other feline species [76] and prominent penile spines. Seasonally, ocelot seminal parameters did not differ from winter to spring in this study, comparable to previous reports. Additionally, bobcats could exhibit higher values in other months of the year and this would need to be further examined.





**Figure 2.1: Testicular parameters, penile morphology, and urethral catheterization.** (a) keratinized spines on the glans penis of an ocelot (*Leopardus pardalis*); (b) lack of keratinized spines on the glans penis of a bobcat (*Lynx rufus*); width and length of a testis as measured by calipers on an ocelot (c, d) and bobcat (e, f); (g, h) urethral catheterization of a bobcat.



**Figure 2.2: Normal and abnormal sperm morphology documented in ocelots and bobcats.** (a) normal sperm morphology; primary abnormalities: (b) tightly coiled tail; and secondary abnormalities: (c) proximal droplet, (d) bent midpiece without a droplet, (e) bent tail.

Our comparison of UC and EEJ in ocelots detected a significant difference in primary sperm abnormalities. Sperm abnormalities in fresh, undiluted semen can result from defects in spermatogenesis (primary abnormalities) [89-90] or sperm transport through the excurrent duct system of the testis, after spermatogenesis (secondary abnormalities) [71, 89-90]. With EEJ and UC, the most common abnormalities were bent tails (secondary sperm abnormality) and a tightly coiled tail (primary sperm abnormality), respectively. However, when urine was present in the UC sample, the most common abnormality did not differ from EEJ collected samples, suggesting an osmotic effect with urine altering sperm morphology although the osmolality of urine relative to UC semen samples remains unknown. Accordingly, it may be the absence of seminal fluids and differing osmolarity in UC samples that increase the percentage of coiled tails using this collection method.

Human-managed ocelots collected by EEJ are reported to produce  $114.7 \pm 15.8 \times 10^6$  motile sperm per ejaculate,  $82.4 \pm 1.2$  % morphologically normal sperm and 1.71 vs 0.14  $\mu\text{g/g}$  fecal androgens [76], with similar reports in other studies [26]. When UC and EEJ was compared for human-managed ocelot populations, UC produced  $36.2 \pm 28.2 \times 10^6$  sperm per ejaculate,  $72.1 \pm 11.5$  % motility and EEJ produced  $55.6 \pm 22.7 \times 10^6$  total sperm per ejaculate and  $87.1 \pm 4.9$  % motility [60]. When sperm was collected by UC in wild ocelots, our percent motility and presence of urine contamination was similar to these previous reports [26, 60]. Although there was no significant difference between UC and EEJ statistically, there tended to be increased sperm numbers, motility, and normal morphology in EEJ collected samples. The relatively lower values for seminal quality by EEJ collection in our ocelot populations were similar to reports in Latin American Zoos [28], in which sample quality was likely impacted by sub-optimal diets and husbandry [28]. In contrast, the ocelots in this study were free-ranging, suggesting that compromised semen quality was less a result of poor diet and husbandry, but possible related to a decline in genetic diversity. Abnormal physical traits typically associated with decreased heterozygosity and inbreeding in felids were not observed in this population; however, our finding of relatively lower sperm concentration, total motile sperm, and acrosomal integrity could render sperm deficient in fertilization potential [12,14-16].

While bobcats in this study exhibited similar testicular volume, percent normal morphology, and sperm concentrations to other species of the *Lynx* genus, acrosome integrity and percent sperm motility were much lower [91]. In bobcats, our samples were recovered using UC

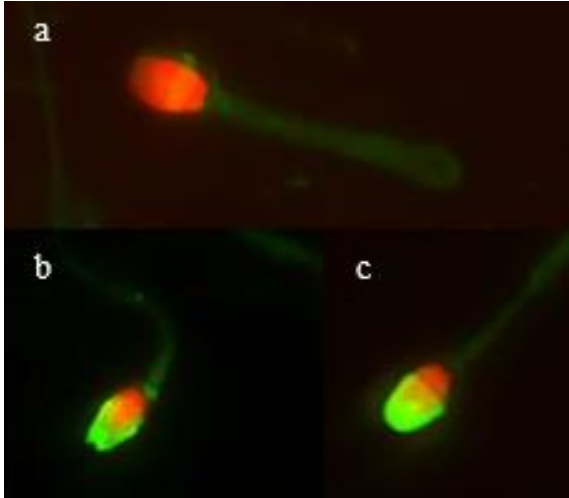
whereas in Canada lynx, UC was ineffective and electroejaculation proved to be superior for semen collection. Similarly, in wild bobcats, very low overall sperm numbers were recovered with the UC collection technique; however when EEJ was employed with human-managed populations [88], increased values for seminal volume, sperm concentration, total sperm per ejaculate, and percent motility were reported. Unilateral cryptorchidism was observed in two bobcats and a persistent penile frenulum in a single bobcat [**Figure 2.4**], which have been reported to be associated with inbreeding [14, 92-97]. Decreased bobcat genetic diversity has been documented in the Lower Rio Grande Valley [7] and, we suspect that reduced genetic diversity coupled with the low reproductive potential typical of this genus might explain the sub-optimal sperm quality seen within this population.

Although semen recovery was successful using the UC method for both species, samples collected by EEJ for ocelots had superior seminal qualities. While differences between UC vs EEJ were not statistically significant, the sample collection method could affect the capacity for cryopreservation and the use of these samples for other assisted reproductive technologies such as artificial insemination. A small decline in percent motility, forward progressive motion, acrosome status and/or morphology could negatively impact sperm transport and function within the reproductive tract and ultimately, reduce fertilization of the oocytes [35, 53-54, 98-104]. Additionally, these two cat populations are exhibiting teratospermia (>60% morphologically abnormal sperm) similar to many other non-domestic Felidae species [10-11, 13, 15] that are affected by reduced genetic variation and decreased circulating testosterone concentrations. Our findings provide the first detailed assessment of reproductive qualities in the last remaining ocelot populations in the US and raises some concern that their declining genetic diversity may be affecting their reproductive success and overall population numbers. Further, our results imply that the introduction of new genetics into this population may be of value to reverse declining heterozygosity and help stabilize this population into the future. For bobcats, our initial findings suggest that the use of EEJ, as an alternative to UC, may be warranted for a more thorough assessment of reproductive traits in free-ranging populations and in relation to their genetic diversity in this region of Texas.

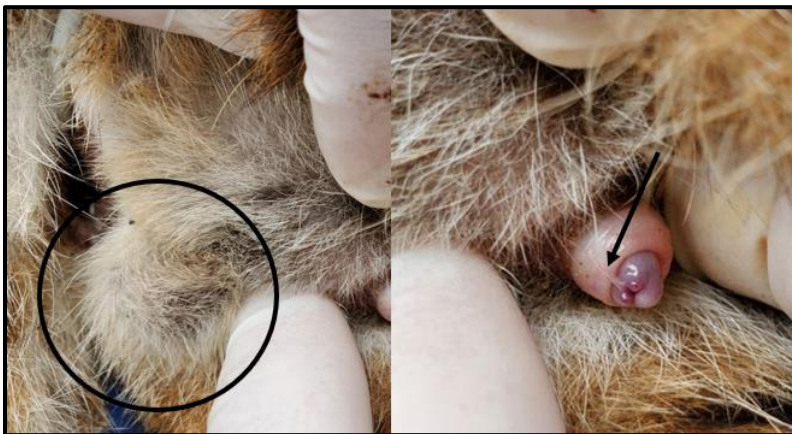**Table 2.1. Mean ( $\pm$ SEM) and median (minimum-maximum) values for seminal traits in two wild felid species.**

	<b>Ocelot UC (n=6)</b>	<b>Ocelot EEJ (n=4)</b>	<b>Bobcat UC (n=14)</b>
<b>VOL*</b>	321 (.87-968)	468 (200-922)	65.42 ( $\pm$ 22.39)
<b>CONC*</b>	124 (1-535.5)	29.5 (0-97)	16 (0.13-125.5)
<b>TSE*</b>	23.3 (0.66-269.5)	53.55 (0-152.5)	0.33 (0.003-36.8)
<b>TMS*</b>	3.8 (0-80.85)	42.85 (0-137.3)	0.03 (0.003-14.7)
<b>ACRO</b>	40.75 ( $\pm$ 13.31)	73.3 ( $\pm$ 5.0)	40.54 ( $\pm$ 4.36)
<b>MORPH</b>	40.33 ( $\pm$ 10.98)	58.1 ( $\pm$ 12.8)	23.31 ( $\pm$ 3.94)
<b>PPM</b>	50 ( $\pm$ 15.28)	83.8 ( $\pm$ 2.4)	14.8 ( $\pm$ 5.1)
<b>FPM</b>	3.33 ( $\pm$ 0.44)	3.9 ( $\pm$ 0.4)	2.4 ( $\pm$ 0.46)

UC, urethral catheterization collection technique; EEJ, electroejaculation collection technique; VOL, semen volume ( $\mu$ l); CONC, sperm concentration ( $\times 10^6$  / ml); TSE, total sperm per ejaculate ( $\times 10^6$ ); TMS, total motile sperm ( $\times 10^6$ ); ACRO, intact acrosome status (%); MORPH, normal sperm morphology (%); PPM, percent progressively motile (%); FPM, rate of forward progression motility (0-5); SEM, Standard Error of the Mean. \*values reported are median values (min-max) due to a non-normal distribution.



**Figure 2.3: Acrosomal staining and classification.** (a) Non-intact acrosome. (b) Partially intact acrosome. (c) Intact acrosome.



**Figure 2.4 : Unilateral cryptorchidism and persistent penile frenulum in a bobcat.** Black circle = unilateral cryptorchidism, presence of only the left testicle; Black arrow = persistent penile frenulum

## References

- [1] J.E. Janečka, M.E. Tewes, L.L. Laack, L.I. Grassman Jr., A.M. Haines, R. Honeycutt. Small effective population sizes of two remnant ocelot populations ( *Leopardus pardalis albescens* ) in the United States. *Conserv Genet.* 9:4 (2008) 869-878. <https://doi.org/10.1007/s10592-007-9412-1>.
- [2] J.E. Janečka, M.E. Tewes, L.L. Laack, A. Caso, L.I. Grassman Jr, A.M. Haines, D.B. Shindle , B.W. Davis, W.J. Murphy, R.L. Honeycutt. Reduced genetic diversity and isolation of remnant ocelot populations occupying a severely fragmented landscape in southern Texas. *Anim Conserv.* 14:6 (2011) 608-619. <https://doi-org.utk.idm.oclc.org/10.1111/j.1469-1795.2011.00475.x>
- [3] J.E. Janecka, M.E. Tewes, L. Laack, A. Caso, L.I. Grassman Jr., R.L. Honeycutt. Loss of Genetic Diversity among Ocelots in the United States during the 20th Century Linked to Human Induced Population Reductions. *Plos One.* 9:2 (2014) e89384. <http://dx.doi.org/10.1371/journal.pone.0089384>.
- [4] P.W. Hedrick, S.T. Kalinowski. Inbreeding Depression in Conservation Biology. *Annu Rev Ecol Syst.* 3:1 (2000) 139-162. <https://doi.org/10.1146/annurev.ecolsys.31.1.139>
- [5] D.H. Reed. Relationship between Population Size and Fitness. Relación entre Tamaño Poblacional y Adaptabilidad. *Conserv Biol.* 19:2 (2005) 563-568. <https://doi-org.utk.idm.oclc.org/10.1111/j.1523-1739.2005.00444.x>
- [6] D.H. Reed, A.C. Nicholas, G.E. Stratton. Genetic quality of individuals impacts population dynamics. *Anim Conserv.* 10:3 (2007) 275-283. <https://doi-org.utk.idm.oclc.org/10.1111/j.1469-1795.2007.00120.x>.
- [7] J.E. Janecka, M.E. Tewes, I.A. Davis, A.M. Haines, A. Caso, T.L. Blankenship, R.L. Honeycutt. Genetic differences in the response to landscape fragmentation by habitat generalist, the bobcat, and a habitat specialist, the ocelot. *Conserv Genet.* 17 (2016) 1093-1108. <https://doi.org/10.1007/s10592-016-0846-1>
- [8] S. Larivière, L.R. Walton, *Lynx rufus*. *Mammalian Species.* 563 (1997) 1-8.

- [9] M. Kelly, D. Morin, C.A. Lopez-Gonzalez, *Lynx rufus*. The IUCN Red List of Threatened Species 2016: e.T12521A50655874. <https://dx.doi.org/10.2305/IUCN.UK.2016-1.RLTS.T12521A50655874.en>. (Accessed on 06 January 2022)
- [10] D.E. Wildt, M. Bush, J.G. Howard, S.J. O'Brien, D. Meltzer, A. Van Dyk, H. Ebedes, D.J. Brand. Unique seminal quality in the South African cheetah and a comparative evaluation in the domestic cat. *Biol of reprod.* 29: 4 (1983) 1019-1025. <https://doi.org/10.1095/biolreprod29.4.1019>
- [11] D.E Wildt, S.J. O'Brien, J.G. Howard, T.M. Caro, M.E. Roelke, M. Bush. Similarity in ejaculate-endocrine characteristics in captive versus free-ranging cheetahs of two subspecies. *Biol of reprod.* 36:2 (1987a) 351. <https://doi.org/10.1095/biolreprod36.2.351>
- [12] S.J. O'Brien, D.E. Wildt, D. Goldman, C.R. Merrill, M. Bush. The cheetah is depauperate in genetic variation. *Science.* 221 (1985) 459–462. <https://doi.org/10.1126/science.221.4609.459>
- [13] D.E. Wildt, M. Bush, K.L. Goodrowe, C. Packer, A.E. Pusey, J.L. Brown, P. Joslin, S.J. O'Brien. Reproductive and genetic consequences of founding isolated lion populations. *Nature.* 329:6137 (1987b) 328. <https://dx.doi.org/10.1038%2F329328a0>
- [14] M.E. Roelke, J.S. Martenson, S.J. O'Brien. The consequences of demographic reduction and genetic depletion in the endangered Florida panther. *Curr Biol.* 3 (1993) 340-350. [https://doi.org/10.1016/0960-9822\(93\)90197-v](https://doi.org/10.1016/0960-9822(93)90197-v)
- [15] D.E. Wildt, L.G. Phillips, L.G. Simmons, P.K. Chakraborty, J.L. Brown, J.G. Howard. A comparative analysis of ejaculate and hormonal characteristics of the captive male cheetah, tiger, leopard and puma. *Biol Reprod* 38 (1988) 245-255. <https://doi.org/10.1095/biolreprod38.2.245>
- [16] J.G. Howard, J.L. Brown, M. Bush, D.E. Wildt. Teratospermic and Normospermic Domestic Cats: Ejaculate Traits, Pituitary—Gonadal Hormones, and Improvement of Spermatozoal Motility and Morphology After Swim-Up Processing. *J of Androl.* 11:3 (1990) 204-215. <https://doi-org.utk.idm.oclc.org/10.1002/j.1939-4640.1990.tb03229.x>
- [17] W.F. Swanson. Application of assisted reproduction for population management in felids: the potential and reality for conservation of small cats. *Therio.* 66 (2006) 49–58. <https://doi.org/10.1016/j.theriogenology.2006.03.024>.

- [18] E. Axné, C. Linde-Forsberg. Semen collection and assessment, and artificial insemination in the cat, in: P. Concannon et al., Recent advances in small animal reproduction, International *Veterinary Information Service*. (2002) 1-9.
- [19] D. Zambelli, S. Belluzzi. Collection and evaluations of cat seminal material, Raccolta e valutazione del materiale seminale di gatto. *Praxis Veterinaria*. 1 (1998) 20-22.
- [20] D. Zambelli, M. Cunto. Semen collection in cats: Techniques and analysis. *Therio*. 66:2 (2006) 159-165. <https://doi.org/10.1016/j.theriogenology.2006.01.054>
- [21] E.S.E. Hafez. Reproduction and breeding techniques for laboratory animals. Philadelphia, Lea & Febiger: Philadelphia, 1970.
- [22] M.P. Dooley, M.H. Pineda, J.G. Hopper, W.G. Hsu. Retrograde flow of spermatozoa into the urinary bladder of cats during electroejaculation, collection of semen with an artificial vagina, and mating. *Am J Vet Res*. 52:5 (1991) 687-91. [https://doi-org.utk.idm.oclc.org/10.1016/0093-691X\(94\)90502-A](https://doi-org.utk.idm.oclc.org/10.1016/0093-691X(94)90502-A)
- [23] N.J. Sojka, L.L. Jennings, C.E. Hamner. Artificial insemination in the cat (*Felis catus L.*), *Lab Anim Care*. 20 (1970) 198-204. PMID: 4246013.
- [24] B.S. Durrant, T. Schuerman, S. Millard. Noninvasive semen collection in the cheetah. *Proc A Mtg Am Assoc Zoo Pks Aquar*. (1985) 564-567.
- [25] D. Zambelli, F. Prait, M. Cunto, E. Iacono, B. Merlo. Quality and in vitro fertilizing ability of cryopreserved cat spermatozoa obtained by urethral catheterization after medetomidine administration. *Therio*. 69:4 (2008) 485-490. <https://doi-org.utk.idm.oclc.org/10.1016/j.theriogenology.2007.10.019>
- [26] M.A. Stoops, J.B. Bond, H.L. Bateman, M.K. Campbell, G.P. Levens, T.R. Bowsher, S.T. Ferrell, W.F. Swanson. Comparison of different sperm cryopreservation procedures on post-thaw quality and heterologous *in vitro* fertilization success in the ocelot (*Leopardus pardalis*). *Reprod Fertil Dev*. 19 (2007) 685-694. <https://doi.org/10.1071/RD06078>
- [27] W.F. Swanson, W.E. Johnson, R.C. Cambre, S.B. Citino, K.B. Quigley, D.M. Brousset, R.N. Morais, N. Moreira, S.J. O'Brien, D.E. Wildt. Reproductive Status of Endemic Felid



Species in Latin American Zoos and Implications for Ex Situ Conservation. *Zoo Biol.* 22 (2003) 421-441. <https://doi-org.utk.idm.oclc.org/10.1002/zoo.10093>

[28] W.F. Swanson, H.L. Bateman, L.M. Vansandt. Urethral catheterization and sperm vitrification for simplified semen banking in felids. *Reprod Domest Anim.* 52:2 (2016) 255-260. <https://doi.org/10.1111/rda.12863>

[29] L.M. Vansandt, H.L. Bateman, A.G. Miller, J.R. Herrick, A. Moresco, R. Gonzalez, M.E. Iwaniuk, W.F. Swanson. Cross-species efficacy of a chemically-defined, soy lecithin-based cryomedium for semen banking in imperiled wild felids. *Therio.* 159 (2021) 108-115. <https://doi-org.utk.idm.oclc.org/10.1016/j.theriogenology.2020.10.021>

[30] A.E. Crosier, L. Marker, J. Howard, B.S. Pukazhenth, J.N. Henghali, D.E. Wildt. Ejaculate traits in the Namibian cheetah (*Acinonyx jubatus*): influence of age, season and captivity. *Reprod Fertil Dev.* 19 (2007) 370-382. <https://doi.org/10.1071/rd06057>

[31] F. Göritz, K.M. Neubauer, S.V. Naidenko, J. Fickel, K. Jewgenow. Investigations on reproductive physiology in the male Eurasian lynx (*Lynx lynx*). *Therio.* 66:6 (2006) 1751-1754. <https://doi-org.utk.idm.oclc.org/10.1016/j.theriogenology.2006.02.036>

[32] D. Jayaprakash, S.B. Patil, M.N. Kumar, K.C. Majumdar, S. Shivaji. Semen Characteristics of the Captive Indian Leopard, *Panthera pardus*. *J of Androl.* 22:1 (2001) 25-33. <https://doi-org.utk.idm.oclc.org/10.1002/j.1939-4640.2001.tb02149.x>

[33] D.E. Wildt, M. Bush, J.G. Howard, S.J. O'Brien, D. Meltzer, A. Van Dyk, H. Ebedes, D.J. Brand. Unique seminal quality in the South African cheetah and a comparative evaluation in the domestic cat. *Biol reprod.* 29:4 (1983) 1019-1025. <https://doi.org/10.1095/biolreprod29.4.1019>

[34] D.E. Wildt, L.G. Phillips, L.G. Simmons, P.K. Chakraborty, J.L. Brown, J.G. Howard, A. Teare, M. Bush. A comparative analysis of ejaculate and hormonal characteristics of the captive male cheetah, tiger, leopard, and puma. *Biol reprod.* 38:2 (1988) 245. <https://doi.org/10.1095/biolreprod38.2.245>

[35] W.F. Swanson, T.L. Roth, E. Blumer, S.B. Citino, D. Kenny, D.E. Wildt. Comparative cryopreservation and functionality of spermatozoa from the normospermic jaguar (*Panthera*

*onca* ) and teratospermic cheetah ( *Acinonyx jubatus* ). *Therio.* 45:1 (1996) 241-241. ISSN :0093-691X.

[36] S.M. McDonnell. Oral imipramine and intravenous xylazine for pharmacologically-induced ex copula ejaculation in stallions. *Anim Reprod Sci.* 68 (2001) 153-159. [https://doi-org.utk.idm.oclc.org/10.1016/S0378-4320\(01\)00152-X](https://doi-org.utk.idm.oclc.org/10.1016/S0378-4320(01)00152-X)

[37] T.M.S. Calvero, F.O. Papa, R.A.M. Schmith, V.F.C. Scheeren, L.E.F. Canuto, M.L.M. Gobato, L.T. Rodrigues, C.P. Freitas-Dell'aqua. Protocols using detomidine and oxytocin induce ex copula ejaculation in stallions. *Therio.* 140 (2019) 93-98. <https://doi.org/10.1016/j.theriogenology.2019.08.024>

[38] C.E. Card, S.T. Manning, P. Bowman, T. Leibel. Pregnancies from imipramine and xylazine-induced ex copula ejaculation in a disabled stallion. *Canadian Vet J.* 38:3 (1997) 171-174. <https://www-ncbi-nlm-nih-gov.utk.idm.oclc.org/pubmed/9056069>

[39] A.H. Kuczarski, M. Alves de Barros, L.F. Souza de Lima, T.F. Motheo, H.J. Bent, G.A. Iglesias, D.A. Sonogo, R.C. Rodrigues da Paz. Urethral catheterization after pharmacological induction for semen collection in dog. *Therio.* 53 (2020) 34-38. <https://doi-org.utk.idm.oclc.org/10.1016/j.theriogenology.2020.04.035>

[40] S. Silinski, C. Walzer, F. Schwarzenberger, L. Slotta-Bachmayr, R. Stolla. Pharmacological methods of enhancing penile erection for ex-copula semen collection in standing white rhinoceros (*Ceratotherium simum simum*). European Association of Zoo and Wildlife Veterinarians (EAZWV) 4<sup>th</sup> Scientific Meeting. (2002).

[41] E.S. Hafez. Anatomy of male reproduction, in: B Hafez, ESE Hafez (Eds.). *Reprod Farm Anim.* Maryland, Lippincot Williams and Wilkins. (2013) 3-11.

[42] A. Macdonald, J.C. McGrath. The distribution of adrenoceptors and other drug receptors between the two ends of the rat vas deferens as revealed by selective agonists and antagonists. *British J of Pharmacol.* 71:2 (1980) 445-458. <https://doi.org/10.1111%2Fj.1476-5381.1980.tb10957.x>

- [43] R. Virtanen, J.M. Savola, V. Saano, L. Nyman. Characterization of the selectivity, specificity and potency of medetomidine as an alpha 2-adrenoceptor agonist. *European J of Pharmacol.* 150:1-2 (1988) 9. [https://doi-org.utk.idm.oclc.org/10.1016/0014-2999\(88\)90744-3](https://doi-org.utk.idm.oclc.org/10.1016/0014-2999(88)90744-3)
- [44] V.A. Doze, B-X. Chen, M. Maze. Dexmedetomidine Produces a Hypnotic–Anesthetic Action in Rats via Activation of Central Alpha-2 Adrenoceptors. *Anesthesiol.* 71:1 (1989) 75-79. <https://doi.org/10.1097/00000542-198907000-00014>
- [45] M.S. Kheirkhah, M. Mollapour sisakht, M. Mohammadsadegh, H.R. Moslemi. Sperm evaluation of Jungle Cat (*Felis chaus*) obtained by urethral catheterization (CT) after medetomidine administration. *Therio.* 91 (2017) 17-20. <https://doi-org.utk.idm.oclc.org/10.1016/j.theriogenology.2016.12.034>
- [46] D.H. Jeong, J.H Kim, K.J. Na. Characterization and cryopreservation of Amur leopard cats (*Prionailurus bengalensis euptilurus*) semen collected by urethral catheterization. *Therio.* 119 (2018) 91-95. <https://doi.org/10.1016/j.theriogenology.2018.06.004>
- [47] I. Lueders, I. Luther, G. Scheepers, G. van der Horst. Improved semen collection method for wild felids: urethral catheterization yields high sperm quality in African lions (*Panthera leo*). *Therio.* 78:3 (2012) 696-701. <https://doi-org.utk.idm.oclc.org/10.1016/j.theriogenology.2012.02.026>
- [48] G.R. Araujo, T.A.R. Paula, T. Deco-Souza, R.G. Morato, L.C.F. Bergo, L.C.D. Silva, D.S. Costa, C. Braud. Comparison of semen samples collected from wild and captive jaguars (*Panthera onca*) by urethral catheterization after pharmacological induction. *Anim reprod sci.* 195 (2018) 1-7. <https://doi.org/10.1016/j.anireprosci.2017.12.019>
- [49] P.N. Jorge-Neto, G.R. Araujo, T. Deco-souza, R.F. Bittencourt, A.C. Csermak Jr, C.S. Pizzutto, M.C.C. Silva, J.A. Salomão Jr, M. Madrigal-Valverde, V.P. Curvelo, M.C. Gomes , T.A.R. Paula. Pharmacological semen collection of Brazilian wild felids. *Rev Bras Reprodução Anim.* 43 (2019) 704.
- [50] J.G. Howard, D.E. Wildt. Semen Collection, Analysis and Cryopreservation in Nondomestic Mammals, In: Morrow DA, editor. Current therapy in theriogenology : diagnosis, treatment, and

prevention of reproductive diseases in small and large animals, Saunders, 2nd edition. (1986) 1047-1053.

[51] J.R. Herrick, M. Campbell, G. Levens, T. Moore, K. Benson, J. D'Agostino, G. West, D.M. Okeson, R. Coke, S.C. Portacio, K. Leiske, C. Kreider, P.J. Polumbo, W.F. Swanson. In vitro fertilization and sperm cryopreservation in the black-footed cat (*Felis nigripes*) and sand cat (*Felis margarita*). *Biol of Reprod.* 82 (2010) 552-562.

<https://doi.org/10.1095/biolreprod.109.081034>

[52] K. Thiangtum, W.F. Swanson, J.G. Howard, W. Tunwattana, D. Tongthainan, W. Wichasilpa, P. Patumrattanathan, T. Pinyopoommintr. Assessment of basic seminal characteristics, sperm cryopreservation and heterologous in vitro fertilisation in the fishing cat (*Prionailurus viverrinus*). *Reprod Fertil Dev.* 18:3 (2006) 373-82.

<https://doi.org/10.1071/rd05098>

[53] E.C. Feldman, R.W. Nelson. Canine and Feline Endocrinology and Reproduction, third ed., Elsevier, Saunders, St. Louis, (2004).

[54] J. Howard. Semen collection, analysis and cryopreservation in nondomestic mammals. *Curr Ther in Therio.* (1986) 1047-1053.

[55] M.M. Vick, H.L. Bateman, C.A. Lambo, W.F. Swanson. Improved cryopreservation of domestic cat sperm in a chemically defined medium. *Therio.* 78:9 (2012) 2120-8.

<https://doi.org/10.1016/j.theriogenology.2012.08.009>

[56] K.M. Graham, N.D. Mylniczenko, C.M. Burns, T.L. Bettinger, C.J. Wheaton. Examining factors that may influence accurate measurement of testosterone in sea turtles. *J Vet Diag Invest.* 28: 1 (2016) 12-19. DOI: 10.1177/1040638715618989

[57] J.E. Janečka, M.E. Tewes, L.L. Laack, L.L. Grassman Jr, A.M. Haines, R. Honeycutt. Small effective population sizes of two remnant ocelot populations ( *Leopardus pardalis albescens* ) in the United States. *Conserv Genet.* 9:4 (2008) 869-878. <https://doi.org/10.1007/s10592-007-9412-1>.

- [58] A.M. Haines, J.E. Janecka, M.E. Tewes, L.L. Grassman Jr, P. Morton. The importance of private lands for ocelot (*Leopardus pardalis*) conservation in the United States. *Oryx*. 40:1 (2006) 90-94. <https://doi.org/10.1017/S0030605306000044>
- [59] A.M. Haines, M.E. Tewes, L.L. Laack, W.E. Grant, J. Young. Evaluating recovery strategies for an ocelot (*Leopardus pardalis*) population in the united states. *Biol Conser.* 126:4 (2005) 512-522. <https://doi.org/10.1016/j.biocon.2005.06.032>
- [60] W.F. Swanson, L.M. Vansandt, S. Citino, R.S. Larsen, G.A. Cole, A. Moresco. Addressing the challenge of do-it-ourself (DIY) semen banking in wild felids. *Proc Ann Meet Amer Assoc Zoo Vet* (2017) 81-82.
- [61] M.A. Stoops, J.B. Bond, H.L. Bateman, M.K. Campbell, G.P. Levens, T.R. Bowsher, S.T. Ferrell, W.F. Swanson. Comparison of different sperm cryopreservation procedures on post-thaw quality and heterologous in vitro fertilization success in the ocelot (*Leopardus pardalis*). *Reprod Fert Dev.* 19 (2007) 685-694. <https://doi.org/10.1071/rd06078>
- [62] D. Zambelli, R. Raccagni, M. Cunto, G. Andreani, G. Isani. Sperm evaluation and biochemical characterization of cat seminal plasma collected by electroejaculation and urethral catheterization. *Therio.* 74 (2010) 8:1396-402.  
<https://doi.org/10.1016/j.theriogenology.2010.06.011>
- [63] W.F. Swanson. Semen banking of wild felids for zoo vets, in: Fowler's Zoo and Wildlife Medicine 2022, in press.
- [64] M.C. Pisu, P. Ponzio, C. Rovella, M. Baravalle, M.C. Veronesi. Usefulness of an injectable anaesthetic protocol for semen collection through urethral catheterization in domestic cats. *J Feline Med Surg.* 10 (2017) 1087–1090. <https://doi.org/10.1177/1098612x16679589>
- [65] M. Madrigal-Valverde, R.F. Bittencourt, A.D.L.R. Filho, V.F. Barbosa, C.A. Vieira, E.A. Romão, I.B. Barneiro, M.C. Azevedo, G.R. Araujo. Quality of domestic cat semen collected by urethral catheterization after the use of different  $\alpha$  2-adrenergic agonist. *J Feline Med Surg.* 23 (2021) 745–750. <https://doi.org/10.1177/1098612x20973183>

- [66] R. Aantaa, A. Kallio, R. Virtanen. Dexmedetomidine, a novel alpha-2-adrenergic agonist. A review of its pharmacodynamic characteristics. *Drugs of the Future. J Feline Med Surg.* 18 (1989) 49–56. <https://doi.org/10.1177/1098612x20973183>
- [67] M. Granholm, B.C. McKusick, F.C. Westerholm, J.C. Aspegrén. Evaluation of the clinical efficacy and safety of dexmedetomidine or medetomidine in cats and their reversal with atipamezole. *Vet Anaesth Analg.* 33 (2006) 214–223. <https://doi.org/10.1111/j.1467-2995.2005.00259.x>
- [68] J.C. Marrow, M. Woc-Colburn, L.A.C. Hayek, L. Marker, S. Murray. Comparison of two  $\alpha_2$ -adrenergic agonists on urine contamination of semen collected by electroejaculation in captive and semi-free-ranging cheetah (*Acinonyx jubatus*). *J Zoo Wildl Med.* 46:2 (2015) 417-420. <https://doi.org/10.1638/2014-0211r2.1>
- [69] M. Cunto, D.G. Kuster, C. Bini, C. Cartolano, M. Pietra, D. Zambelli. Influence of different protocols of urethral catheterization after pharmacological induction (Ur.Ca.P.I.) on semen quality in the domestic cat. *Reprod Dom Anim.* 50 (2015) 999–1002. <https://doi.org/10.1111/rda.12626>
- [70] N. Romagnoli, D. Zambelli, M. Cunto, c. Lambertini, D. Ventrella, M.B. Toaldo,.Non-invasive evaluation of the haemodynamic effects of high-dose medetomidine in healthy cats for semen collection. *J Feline Med Surg.* 18 (2016) 337–343. <https://doi.org/10.1177%2F1098612X15583345>
- [71] W.V. Holt, Epididymal origin of a coiled-tail sperm defect in a boar. *J Reprod Fertil.* 64:2 (1982) 485-489. <https://doi.org/10.1530/jrf.0.0640485>
- [72] S.D Johnston, K.M.V. Root, P.S. Olson. Semen collection, evaluation, and preservation. In *Canine and Feline Theriogenology*, 1<sup>st</sup> ed. Philadelphia, Pa., London: Saunders. (2001) 287-306.
- [73] S. Johnston. New canine semen evaluation techniques for the small animal practitioner. In: *Proceedings of the Annual Meeting. Soc for Therio.* (1989) 320-32.
- [74] S. Seager. Semen collection and evaluation in the dog In Morrow DA (ed): *Current Therapy in Theriogenology*, ed 2, (1986) 539-544.

- [75] J.L. Freshman. Semen collection and evaluation. *Clin Tech Small Anim Pract.* 17:3 (2002) 104-107. <https://doi.org/10.1053/svms.2002.34326>
- [76] R.N. Morais, R.G. Mucciolo, M.L.F. Gomes, O. Lacerda, W. Moraes, N. Moreira, L.H. Graham, W.F. Swanson, J.L. Brown. Seasonal analysis of semen characteristics, serum testosterone and fecal androgens in the ocelot (*Leopardus pardalis*), margay (*L. wiedii*) and tigrina (*L. tigrinus*). *Therio.* 57:8 (2002) 2027-2041. [https://doi.org/10.1016/s0093-691x\(02\)00707-0](https://doi.org/10.1016/s0093-691x(02)00707-0)
- [77] E.C. Feldman, R.W. Nelson. Canine and Feline Endocrinology and Reproduction. 3rd edition. St. Louis: St. Louis: Elsevier: Saunders. (2004)
- [78] A. Nuhn. Lehrbuch der vergleichenden Anatomie, part 1. Caerl Winter, Heidelberg. 1886.
- [79] E. Retterer, A. Lelièvre. Effects de la castration sur le chat. *C R Soc Biol.* 73 (1912) 184-186.
- [80] N. Moreira, E.L.A. Monteiro-Filho, W. Moraes, W.F. Swanson, L.H. Graham, O.L. Pasquali, M.L.F. Gomes, R.N. Morais, D.E. Wildt, J.L. Brown. Reproductive steroid hormones and ovarian activity in felids of the *Leopardus* genus. *Zoo Biol.* 20 (2001) 103-116. <https://doi.org/10.1002/zoo.1010>
- [81] E. Mondolfi. Notes on the biology and status of the small wild cats in Venezuela. In: Miller SD, Everett DD (Eds.). *Cats of the world: biology, conservation and management*. Washington, D.C.: National Wildlife Federation. (1986) 85-124.
- [82] R. Eaton. Breeding biology and propagation of the ocelot (*Leopardus [Felis] pardalis*), *Zoologische Garten.* 1 (1977) 72-81.
- [83] L.L. Laack, M.E. Tewes, A.M. Haines, J.H. Rappole. Reproductive life history of ocelots *Leopardus pardalis* in southern Texas. *Acta Theriologica.* 50:4 (2005) 505-514. <https://doi.org/10.1007/BF03192643>
- [84] K.V. Fanson, N.C. Wielebnowski, T.M. Shenk, W.J. Jakubas, J.R. Squires, J.R. Lucas. Patterns of testicular activity in captive and wild Canada lynx (*Lynx canadensis*). *Gen and Comp Endocrin.* 169:3 (2010) 210-216. <https://doi.org/10.1016/j.ygcen.2010.09.001>

- [85] M.N. Erofeeva, E.V. Pavlova, A.L. Antonevich, S.V. Naidenko. Seasonal changes in activity of males' reproductive system in Eurasian lynx. *Russian J Theriol.* 13:1 (2014) 9-16. <http://dx.doi.org/10.15298/rusjtheriol.13.1.02>
- [86] L.R. Aronson, M.L. Cooper. Penile spines of the domestic cat: their endocrine-behavior relations. *The Anatomical Record.* 157 (1967) 71-8.
- [87] W.W. Greulich. Artificially induced ovulation in the cat (*felis domestica*). *The Anatomical Record.* 58:3 (1934) 217-224. <https://doi-org.utk.idm.oclc.org/10.1002/ar.1090580302>
- [88] A. Gañán, R. González, A. Sestelo, J.J. Garde, I. Sánchez, J.M. Aguilar, M. Gomendio, E.R.S. Roldan. Male reproductive traits, semen cryopreservation, and heterologous in vitro fertilization in the bobcat (*Lynx rufus*). *Therio.* 74 (2009) 341-352. <https://doi.org/10.1016/j.theriogenology.2009.03.002>
- [89] N. Gañan, A. Sestelo, J.J. Garde, F. Martinez, A. Vargas, I. Sánchez, M.J. Pérez-Aspa, J.V. López-Bao, F. Palomares, M. Gomendio, E.R.S. Roldan. Reproductive traits in captive and free-ranging males of the critically endangered Iberian lynx (*Lynx pardinus*). *Soc for Reprod and Fertil.* (2010) <http://dx.doi.org/10.1530/REP-09-0259>
- [90] S.W.J. Seager. Artificial insemination in dogs. In: Burke TJ (ed): Small Animal Reproduction and Infertility. (1986) 207-217.
- [91] R. Payan-Carreira, S. Miranda, W. Nizanski. Artificial insemination in dogs. In: Milad Manafi (ed): Artificial Insemination in Farm Animals. (2011).
- [92] R. González, A. Moresco, A. Miller, H. Bateman, L. Vansandt, D. Dembiec, A. Ista, W.F. Swanson. Assessment of semen traits in servals (*Leptailurus serval*) and Canada lynx (*Lynx canadensis*). *Reprod Fert Dev.* 31 (2018) 1:176-177. <https://doi.org/10.1071/RDv31n1Ab101>
- [93] S.E. Romagnoli. Canine cryptorchidism. *Vet Clin N Am Small Anim Pratt.* (1991) 535-544.
- [94] Burns M, Fraser MN (Eds): Genetics of the Dog. Edinburgh: Oliver and Boyd; (1964).
- [95] J.H. Claxton, N.T.M. Yeates. The inheritance of cryptorchidism in a small, crossbred flock of sheep. *J Hered.* 63 (1972) 141-144. <https://doi.org/10.1093/oxfordjournals.jhered.a108254>



- [96] H.C. McPhee, S.S. Buckley. Inheritance of cryptorchidism in Swine. *J Hered.* 25 (1934) 295-303. <https://doi.org/10.1093/oxfordjournals.jhered.a103951>
- [97] S.J. Kogan. *Clinical Pediatric Urology*, 2nd edn. New York: Saunders. (1985)
- [98] M.A. Barone, M.E. Roelke, J. Howard, J.L. Brown, A.E. Anderson, D.E. Wildt. Reproductive fitness of the male Florida panther: Comparative studies of *Felis concolor* from Florida, Texas, Colorado, Chile, and North American Zoos. *J Mammal.* (1993) <https://doi.org/10.2307/1382247>
- [99] D.R.P. Tulsiani, A. Abou-Haila. Biological Processes that Prepare Mammalian Spermatozoa to Interact with an Egg and Fertilize It. *Scientifica* (2012). <https://doi.org/10.6064%2F2012%2F607427>
- [100] J.G. Howard, A.M. Donoghue, L.A. Johnston, D.E. Wildt. Zona pellucida filtration of structurally abnormal spermatozoa and reduced fertilization in teratospermic cats. *Biol of reprod.* 49:1 (1993) 131. <https://doi.org/10.1095/biolreprod49.1.131>
- [101] J.G. Howard, M. Bush, D.E. Wildt. Teratospermia in Domestic Cats Compromises Penetration of Zona-Free Hamster Ova and Cat Zonae Pellucidae. *J of Androl.* 12:1 (1991) 36-45. <https://doi.org/10.1002/j.1939-4640.1991.tb00211.x>
- [102] H. Krzanowska. The passage of abnormal spermatozoa through the utero-tubal junction of the mouse. *J Reprod Fertil.* 38 (1974) 81-90. <https://doi.org/10.1530/jrf.0.0380081>
- [103] A. Nestor, M.A. Handel. The transport of morphologically abnormal sperm in the female reproductive tract of mice. *Gamete Res.* 10 (1984) 119-125. <https://doi.org/10.1002/mrd.1120100204>
- [104] R.G. Saacke, J.H. Bame, D.S. Karabinus, K.J. Mullins, S. Whitman. Transport of abnormal spermatozoa in the artificially insemination cow based upon accessory spermatozoa in the zona pellucida. *Proc Inr Congr Anim Reprod Artif Insemin.* 3 (1988) 292.

## Appendix 2

**Table 2-A. Seminal traits for individual ocelots collected by urethral catheterization and/or electroejaculation.**

	WT (KG)	TTVOL	VOL	CONC	TSE	TMS	ACRO	MORPH	PPM	RFP
Urethral Catheterization										
<b>E19M</b>	13.4	20.9	148	535.5	79.3	55.5	72	59.8	70	4
<b>E22M^</b>	11	20.3	408	3.67	9	7.2	44	35	80	1
<b>Y27M^</b>	13.8	21.4	79	294.9	23.3	14	77	21.8	60	2.5
<b>Y28M^</b>	5.5	1.85	0							
<b>E13M^</b>	12.5	21.7	968	124	120	0	33	73	0	0
<b>E24M^</b>	9.8	8.1	663	1	0.7	0	7	15	0	0
<b>OM341^</b>	11.4	22.3	321	7.5	9.5	3.8	26	14	40	0.5
<b>LO02M</b>	5.7	0.95	43							
Electroejaculation										
<b>E22M^</b>	9.3	22.7	922	97	99.5	79.6	76	27	80	2
<b>E13M</b>	12.5	21.7	250	8	7.6	6.1	60.5	69	80	3
<b>E24M</b>	9.8	8.1	200							
<b>LO04M^</b>	9.8	13.3	431	47	13.8	11.7	71	86.5	85	4.5
<b>OM341</b>	11.4	22.3	686	51	152.5	137.3	85	50	90	4.5

TTVOL, total testicular volume (cm<sup>3</sup>); VOL, semen volume (μl); CONC, sperm concentration (x 10<sup>6</sup> / ml); TSE, total sperm per ejaculate (x 10<sup>6</sup>); TMS, total motile sperm (x 10<sup>6</sup>); ACRO, intact acrosome status (%); MORPH, normal sperm morphology (%); PPM, percent progressively motile (%); RFP, rate of forward progression (0-5); ^urine contamination

**Table 2-B. Seminal traits for individual bobcats collected by urethral catheterization.**

	WT (KG)	TTVOL	VOL	CONC	TSE	TMS	ACRO	MORPH	PPM	RFP
<b>EB31M*</b>	10	2.46								
<b>EB33M</b>	9.09	2.44	25	5.5	0.137	0.04	42	28.5	30	3
<b>EB34M^</b>	8.4	1.97	10	42.5	0.425	0.004	14.5	38.5	1	3
<b>EB35M^</b>	8	1.48	1000				17	50		
<b>EB36M</b>	8.1	2.21	54.4	56.5	3.08	0.03	21	5.3	1	4
<b>EB37M</b>	11.8	5.16	36.8	40	1.47	0.59	31	19.5	40	4
<b>EB38M^</b>	11.8	3.8	200							
<b>EB39M^</b>	9.09	1.08	191							
<b>EB42M</b>	9.78	2.64	60	58.5	3.51	0.35	64	27.5	10	3
<b>EB44M^</b>	6.93	2.95	1000				24	27.5		
<b>EB45M</b>	6.81	2.04	14	23	0.32	0.003	60	28.8	1	3
<b>YB7M^</b>	10.23	1.01	1000				15	19		
<b>YB9M^</b>	9.99	4.25	33.6	125.5	4.22		18	9.5		
<b>YB10M^</b>	9.27	3.91	1000				28.5	9		
<b>EB48M</b>	8.24	2.86	73	1	0.73		47	37		
<b>EB50M^</b>	7.96	1.85	40	2.12	0.25	0.03	38	19	10	1.5
<b>EB51M^</b>	6.9	0.54	50	0.125	0.003					
<b>EB53M</b>	9.44	2.29	15	122.5	36.8	14.7	70	29	40	1
<b>EB54M</b>	9.16	1.56	14	9	0.126	0.01	53	31	10	3
<b>LB01M^</b>	8	5.15	320	1	0.067		33	12.5		
<b>LB02M*</b>	8.7	0.47	0							
<b>LB03M^</b>	9.66	5.25	170	2	0.34		35	25		

TTVOL, total testicular volume (cm<sup>3</sup>); VOL, semen volume (μl); CONC, sperm concentration (x 10<sup>6</sup> / ml); TSE, total sperm per ejaculate (x 10<sup>6</sup>); TMS, total motile sperm (x 10<sup>6</sup>); ACRO, intact acrosome status (%); MORPH, normal sperm morphology (%); PPM, percent progressively motile (%); RFP, rate of forward progression (0-5); \*unilateral cryptorchid; ^urine contamination

**Chapter III: Assessment of ultra-rapid freezing as a simplified, field-friendly technique for long-term storage of spermatozoa in ocelots (*Leopardus pardalis*) and bobcats (*Lynx rufus*) in southern Texas**

## Abstract

Recent studies of small populations of wild felids have shown a loss of genetic variability over time, specifically in southern Texas, where ocelot (*Leopardus pardalis*) populations are increasingly becoming genetically similar. Assisted reproductive technologies (ARTs) can be used to address behavioral or physical incompatibilities between genetically suitable breeding pairs, connect regional populations by transporting frozen gametes, preserve genetic diversity within liquid nitrogen tanks, and link wild and human-managed populations without removing cats from the wild. Traditionally, semen has been cryopreserved by slow freezing in plastic straws before storage in liquid nitrogen. Recently, a technique was developed for pipetting semen directly into liquid nitrogen for ultra-rapid freezing (URF) to create sperm pellets, decreasing the time and effort needed to preserve samples for storage. The goal of this study was to compare the effectiveness of URF with traditional straw freezing for field usage. Semen was collected by UC and EEJ and preserved using both cryopreservation methods. Post-thaw, sperm samples were assessed for progressive motility over time, acrosomal integrity, and heterologous in-vitro fertilization using domestic cat oocytes. From 2019 through 2022, semen was collected from 12 adult male felids (n=6 ocelots; n=6 bobcats (*Lynx rufus*)). For ocelots (O) and bobcats (B), there was a significant effect of time on acrosomal integrity, percent motility, and forward progressive motility (O,  $p < 0.001$ ; B,  $p < 0.001$ ; respectively). While there were no differences in oocyte cleavage rate or sperm quality ( $p > 0.05$ ) post-thaw with either cryopreservation method, sperm quality was consistently greater using a different combination of semen collection and cryopreservation methods for both species (ocelots: EEJ with STRAW and bobcats: UC with URF or STRAW). Further examination of EEJ in bobcats and fertilization success of frozen-thawed sperm samples in vivo should be explored to support these findings. Although additional modifications for species variability need to be explored, these initial results suggest the UC-URF approach may be suitable for field use with some cat species, allowing wildlife veterinarians to routinely bank semen samples from wild felids for broader application of ART.

## Introduction

Recent studies of small populations of wild felids in southern Texas have shown loss of genetic variability over time [1-3]. Genetic drift and inbreeding depression to compromise the fitness of a population and further reduce their viability [4-6]. Assisted reproductive

technologies (ARTs) may mitigate the decline in genetic diversity and its consequences by addressing behavioral and physical incompatibilities among breeding pairs, connecting distant populations by transporting reproductive materials such as semen and embryos, preserve genetic diversity using liquid nitrogen tanks, and link wild and human-managed populations without requiring removal of cats from the wild [7]. Maintenance of adequate genetic variation in ex situ (captive) and/or in situ (wild) populations could be facilitated by the storage of frozen gametes and embryos in liquid nitrogen tanks, permitting easier transport for genetic exchange between distant locations and promoting long-term preservation to counter genetic drift and catastrophic loss [8-10]. Species and individuals differ in the ability of their sperm to survive cryopreservation and the investigation of these techniques on a species-level basis is necessary [11-12].

Previous cryopreservation studies in other feline species have used either sperm pelleting on indentations in dry ice [13-17] or straw freezing over liquid nitrogen vapor [14, 18-21]. One nulliparous female ocelot treated with exogenous gonadotropins and inseminated with frozen-thawed spermatozoa cryopreserved in straws, conceived and gave birth to a healthy kitten 78 days later [13]. However, an increase in total sperm used for artificial insemination (AI) was needed to compensate for the acrosome damage as compared to freshly collected inseminates used for AI procedures [13]. Compared with fresh ejaculates, frozen-thawed spermatozoa cryopreserved in straws had similar values for progressive motility status, but decreased percentages of normal sperm morphology and lower percentages of intact acrosomes [22]. Cryopreservation information in bobcats (*Lynx rufus*) is limited, with one report of successful cryopreservation of bobcat sperm using TEST (20% egg yolk and 4% glycerol) medium with a traditional straw freezing protocol used in other felids [22, 23, 37]. They also observed that frozen-thawed bobcat sperm could fertilize in-vitro matured oocytes from domestic cats, similar to other feline species, however, fertilization rates were significantly different dependent on season (November (17%) and April (46%)) [23]. Although a reduction in percentage of intact acrosomes and post thaw motility was noted, this was similar to other medium-sized cats [23]. To our knowledge, the use of these semen cryopreservation techniques with free-ranging ocelots or bobcats have never been attempted or reported previously.

A newer sperm cryopreservation approach, ultra-rapid freezing (URF), offers advantages of simplicity and minimal equipment needs, requiring only URF- specific medium and liquid

nitrogen [24-26]. A comparative study in domestic cats involving catheter-recovered sperm samples frozen by URF or conventional straw freezing reported no difference in post-thaw motility and acrosome status of urethral catheterization (UC)- URF samples over time as compared to straw frozen samples [26]. Preliminary in-vitro fertilization (IVF) results indicate that UC-URF sperm was capable of fertilizing oocytes in vitro and fertilization success with URF sperm for all inseminated oocytes (30%) did not differ from that observed with straw frozen samples (57%) [26]. However, based on mature oocytes (M2 cell or cleaving), fertilization success with URF sperm (35%) was slightly lower than that of sperm frozen in straws (65%) [26]. With laparoscopic oviductal artificial insemination (LO-AI), sperm function and motility over time are not as critical as with intravaginal or intrauterine AI. High pregnancy rates (70-80%) have been obtained in domestic cats using LO-AI with low sperm numbers (~ 1 million motile/oviduct) for insemination, including semen that was frozen using standard straw cryopreservation methods [27-29]. Additionally, LO-AI has been used to produce kittens with not only straw cryopreserved semen, but semen collected with an artificial vagina and cryopreserved by URF in domestic cats [30].

As ocelot (*Leopardus pardalis*) numbers in the wild continue to decline, assisted reproductive techniques, such as sperm cryopreservation, could prove useful to store genetic material for future use in conservation initiatives. While bobcat populations are not currently in decline [31], they could one day face the same obstacles that many feline species have encountered over the last decade and act as a model for closely related, endangered species, such as the Iberian lynx (*Lynx pardinus*) and the Eurasian lynx (*Lynx lynx*) [32-33]. Assessing reproductive techniques while the bobcat population is at a stable size could prove useful for future conservation initiatives, should they arise. The objectives of our study were to compare the effectiveness of URF with traditional straw freezing (STRAW) by assessing post-thaw sperm motility, rate of forward progression, percentage of intact acrosomes, and heterologous in-vitro fertilization capabilities in samples frozen using two techniques. If proven effective, the use of URF cryopreservation would provide a simplified and rapid field technique for sperm cryostorage from free-ranging ocelots and bobcats.

## Materials and Methods

### *Animals*

Adult male wild cats (n=12), representing 2 species from 2 genera (*Leopardus*: ocelot, n=6; *Lynx*: bobcat, n=6) were used in this study. Wild felids were captured using modified Tomahawk traps (Tomahawk Live Trap Co., Tomahawk, Wisconsin, USA) on private ranches in Willacy and Kenedy counties in Southern Texas. A hardware box extension was added to the trap to contain a live pigeon or small chicken that were provided feed and water ad libitum. For heterologous in vitro fertilization (IVF) procedures, ovaries from domestic cats undergoing ovariectomy were donated from local shelters. All animal use was approved by and in accordance with the policies of the Institutional Animal Care and Use Committee at the Texas A and M University– Kingsville (TAMUK), Caesar Kleberg Wildlife Research Institute (CKWRI), the University of Tennessee- Knoxville and the Center for Conservation and Research of Endangered Wildlife (CREW) at the Cincinnati Zoo and the study was permitted by the United States Fish and Wildlife Service (USFWS).

### *Media*

Feline-optimized culture medium (FOCM) was prepared from stock solutions as described by Herrick et al. [34]. Modifications to FOCM for in vitro maturation (FOCM-IVM), fertilization (FOCM-IVF) and culture (FOCM-IVC) were made according to Herrick et al. [35]. All IVM, IVF and IVC media were equilibrated in 6% CO<sub>2</sub> at 38.6°C for 12-18 hours before use. Soy-lecithin with 0.2 M sucrose cryopreservation medium was prepared from stock solutions as described by Vick et al. [36] and stored in a -40 °C freezer until use for ultra-rapid freezing. Soy with 4% glycerol cryopreservation medium was prepared from stock solutions as described by Vick et al. [36] and stored in a -40 °C freezer until use for straw freezing.

### *Semen Collection and Cryopreservation*

Males were immobilized and maintained at a light anesthetic plane for semen collection procedures. The anesthetic protocol consisted of an injectable combination regimen of ketamine hydrochloride (target dosage: Ocelot- 4 to 8 mg/kg bodyweight; Bobcat- 2.5 to 5 mg/kg bodyweight; Wedgewood Pharmacy: Wildlife Pharmaceuticals, Inc. and ZooPharm, Swedesboro NJ) and medetomidine (target dosage: Ocelot- 0.05 mg/kg bodyweight; Bobcat- 0.06 mg/kg



bodyweight; Wedgewood Pharmacy: Wildlife Pharmaceuticals, Inc. and ZooPharm, Swedesboro NJ) given intramuscularly (i.m.) via pole syringe followed by partial reversal with atipamezole i.m. (target dosage: 5 mg of atipamezole for every 1 mg of medetomidine given; Wedgewood Pharmacy: Wildlife Pharmaceuticals, Inc. and ZooPharm, Swedesboro NJ). Fasting prior to the anesthetic event was not possible due to the cats' free-ranging nature. During immobilization, eyes were lubricated and covered to minimize stimuli and stress. Body temperature, heart rate, respiratory rate, pulse oximetry, jaw tone, and capillary refill time were monitored throughout the procedure.

Approximately 25-40 minutes post anesthesia injection, the penis was extruded with manual manipulation and sterile gloves. Debris on the penis and in the preputial cavity was removed with a water-soaked gauze. Semen was collected by urethral catheterization (UC) : a 3.5 (1.2 mm) or 5 (1.7 mm) French in diameter urinary catheter was advanced approximately 15 cm (ocelots) or 13-15 cm (bobcats) into the urethra, left in place for 30 seconds and slowly removed. If collection of an ejaculate was unsuccessful or not viable by UC, one to three series of electroejaculation (EEJ) (2-5 V; 10 stimulations per series) using a standardized technique [37] with slight modifications [21, 35] was performed for ocelots.

Semen samples were assessed using a standardized technique [37] with slight modifications. For samples collected by UC, the sample was placed into an Eppendorf vial with a one ml syringe and a small amount of air. Seminal volume (VOL) of each sample was measured using a micro pipettor and assessed initially for the presence of spermatozoa. For spermic samples, motility (percent progressively motile, PPM; 0-100%) and rate of forward progressive motility (RFP; scale of 0-5, with 0 being non-motile and 5 being rapid forward progression) were evaluated microscopically using raw aliquots from each catheter sample [38]. A subset of raw semen (1  $\mu$ l) was fixed in 49  $\mu$ l of 0.3% glutaraldehyde and assessed with phase microscopy at 400X magnification (100-200 sperm/sample) to determine percent of spermatozoa with normal morphology (MORPH). A subset of raw semen was placed into water at a 1:400 dilution to determine sperm concentration (CONC) using a hemocytometer method. Total sperm per ejaculate (TSE) was calculated by multiplying the VOL and CONC.

An aliquot (8  $\mu$ l) was spread onto two microscope slides (4  $\mu$ l each), dried at room temperature, stained with fluorescein isothiocyanate-peanut agglutinin (Sigma Aldrich Corporation), and assessed with fluorescent microscopy (100-200 sperm/sample) to determine

percent of intact acrosomes (ACRO) [36]. The remaining volume was spilt into two aliquots and each diluted 1:5 for respective treatments in their respective medium (URF, soy-lecithin (SOY) with 0.2 M sucrose; STRAW, FOCM-Hepes). Sperm concentration of each treatment was determined in the same fashion as described above (URFCONC, STRCONC). The diluted URF sample was cryopreserved using a micropipettor, pipetting one, ~20  $\mu$ l drop at a time directly into liquid nitrogen to create pellets. This process was repeated for the entirety of the volume, the pellets placed into a labeled cryovial and stored in liquid nitrogen. The diluted STRAW sample was centrifuged at 600xg for 8 minutes and the resulting sperm pellets were resuspended in straw-freezing medium (SOY with 4% glycerol) to  $50 \times 10^6$  motile sperm/ml and loaded into 0.25 mL straws (30-100  $\mu$ l/straw). Straws were heat sealed, transferred into a sealable plastic bag, submerged in room temperature water (100 ml) within a glass container, and cooled to 4 °C over a minimum of 2 hours in an electric, plug-in cooler initially until a refrigerator could be accessed. Straws were then frozen using a modified two-step protocol [21, 39]. Briefly, two metal racks were placed in a polystyrene foam container partially filled with liquid nitrogen (LN<sub>2</sub>). Cooled straws were placed on the top rack (7.5 cm above the LN<sub>2</sub> surface) for one minute and then transferred to the bottom rack (2.5 cm above the LN<sub>2</sub> surface) for one minute before plunging directly into liquid nitrogen for storage (1-6 months) until once sample for each treatment was assessed post-thaw.

When urine was confirmed within the sample by pH, color, and/or sperm in shock under microscopic examination, the sample was immediately diluted with 1000  $\mu$ l of FOCM-Hepes and centrifuged for 8 minutes at 600xg. The supernatants were removed, and the remaining sperm pellet diluted with 100-1000  $\mu$ l FOCM-Hepes media and motility (percent progressively motile, PPM; 0-100%) and rate of forward progressive motility (RFP; scale of 0-5, with 0 being non-motile and 5 being rapid forward progression) were evaluated microscopically. Then, 2 slides were made for acrosome assessment using 4  $\mu$ l of the same mixture as previously described and 3  $\mu$ l of sample was fixed in 49  $\mu$ l of 0.3% glutaraldehyde PBS for morphology assessments. After 5 minutes post dilution with FOCM-Hepes, the motility was re-assessed and if motility remained at or above 30%, the straw freezing protocol was continued.

For samples collected by EEJ, seminal volume (VOL) of each recovered sample was measured using a micro pipettor and assessed initially for the presence of spermatozoa. For spermic samples, motility (percent progressively motile, PPM; 0-100%) and rate of forward

progressive motility (RFP; scale of 0-5, with 0 being non-motile and 5 being rapid forward progression) were evaluated microscopically using raw aliquots from each collection series [37]. A subset of raw semen (2.5  $\mu$ l) was fixed in 49  $\mu$ l of 0.3% glutaraldehyde and assessed with phase microscopy (100-200 sperm/sample) to determine percent of spermatozoa with normal morphology (MORPH). Semen was then diluted 1:1-1:3 with FOCM-Hepes. All samples containing motile sperm were pooled and sperm concentration (CONC) was determined using a hemocytometer method. Total sperm per ejaculate (TSE) was calculated by multiplying VOL and CONC. If urine contamination occurred during a collection set, the sample was immediately diluted in FOCM-Hepes, centrifugated for 8 minutes at 600xg, and the supernatant removed. The sample was re-suspended with FOCM-Hepes and assessed for recovery of sperm motility and forward progressive motility for assessment of inclusion in the pooled sample. An aliquot (8  $\mu$ l) was spread onto two microscope slides (4  $\mu$ l each), dried at room temperature, stained with fluorescein isothiocyanate-peanut agglutinin (Sigma Aldrich Corporation), and assessed with fluorescent microscopy (100-200 sperm/sample) to determine percent of intact acrosomes (ACRO) [36]. The remaining diluted semen was centrifugated at 600xg for 8 minutes and resuspended in straw-freezing medium (SOY with 4% glycerol) to  $50 \times 10^6$  motile sperm/ml and all methods for straw freezing were continued as described previously.

#### *Post-Thaw Analysis*

Post-thaw methods were conducted using a standardized technique [37] with slight modifications. Domestic cat reproductive tracts were recovered immediately post-spay at a local spay-neuter clinic, stored in vials of chilled PBS and transported to the laboratory within 1-3 hours post-recovery. Ovaries were macerated in a petri dish containing FOCM-Hepes using a sterile scalpel blade to release oocytes. Recovered cumulus oocyte complexes (COCs) were graded with the following scale [40] presented in **Figure 3.1**. Grades 1 and 2 were pipetted through the wash dish into 3 drops simultaneously and then transferred into an IVM drop (10-15 COCs at most per drop) and the number of oocytes and grades in each drop recorded. The IVM dish was placed into the incubator and COCs left to mature for 24-26 hours. For heterologous IVF, grade 1 and 2 COCs exhibiting expanded layers of cumulus cells and an oocyte with uniformly dark cytoplasm [40] were randomly but equally divided between treatment groups (n=10-20 COCs/experimental unit). COCs were washed three times in FOCM-IVF, and then

placed in 95  $\mu$ l microdrops of FOCM-IVF (10-15 oocytes per drop) maintained at 38.6 °C in 6% CO<sub>2</sub> under mineral oil (Sigma-Aldrich Corporation).

Sperm straws were thawed in the air for 10 seconds (sec) and then placed directly into a 38°C water bath for 30 sec. The contents of each straw were emptied into a 1.5-ml microcentrifuge tube, slowly diluted with 300  $\mu$ l FOCM-Hepes, and centrifuged at 300xg for 8 minutes. The resulting sperm pellets were resuspended in 30  $\mu$ l of FOCM-IVF, and immediately evaluated for sperm motility (0 hour) and concentration (CONC). Sperm concentration was adjusted to 5-10 x 10<sup>6</sup> motile sperm/ml and aliquots were added to pre-equilibrated IVF microdrops (5  $\mu$ l sperm into 95  $\mu$ l drop, final sperm concentration ~ 2.5-5 x 10<sup>6</sup> motile sperm/ml) and motility microdrops (5  $\mu$ l sperm into 20  $\mu$ l drops volume, final sperm concentration 1-2 x 10<sup>6</sup> motile sperm/ml) under oil.

In a cryobucket filled with liquid nitrogen, one pellet of ultra-rapid frozen spermatozoa was removed from the cryovial under the LN<sub>2</sub> surface. A glass test tube containing 100  $\mu$ l FOCM-HEPES was warmed in a water bath to 38° C. The semen pellet was then transferred into the warmed glass test tube and gently mixed by hand for approximately 30 sec. The liquid was transferred to a microcentrifuge tube, slowly diluted with 200  $\mu$ l FOCM-HEPES, and centrifugated at 300xg for 8 minutes. All methods for analysis at this point were identical to the straw samples.

Sperm and oocytes were co-incubated in IVF microdrops for 12-18 hours before cumulus cells were removed in the presence of 0.5 mg/ml hyaluronidase (Sigma-Aldrich Corporation) by shaking vigorously with a vortex mixer. Oocytes were then washed with FOCM-IVC three times before allocating to 95  $\mu$ l drops of the same medium. At 48-h post-insemination, oocytes were evaluated for cleavage and developmental stage and then fixed separately as cleaving embryos or non-cleaving oocytes in FOCM containing 1% neutral-buffered formalin (Fisher Chemical, Fair Lawn, NJ, USA). Hoechst 33342 (Sigma-Aldrich) staining was used to determine oocyte stage or embryo status [**Figure 3.2**]: degenerate (D), germinal vesicle (GV), meiosis I (MI), meiosis II (MII), pronuclear (PN), number of blastomeres (BN), and number of accessory sperm (AS) bound to the zona pellucida of embryos (E) and mature oocytes. Oocytes at the meiosis II stage or pronuclear stage were classified as mature, and the presence of distinct blastomeres was considered indicative of fertilization. Fertilization percentage (FP) was calculated based on the number of mature oocytes.

Motility dishes were maintained in the incubator for 24 hours and 2.5  $\mu$ l aliquots were assessed at 1, 3, 6, and 24 hours of incubation for sperm motility (PPM and RFP). Sperm aliquots (4  $\mu$ l each) were also used to assess percentage of intact acrosomes post-thaw at 0 hours and 6 hours of culture. Acrosome slides were dried at room temperature, stained with fluorescein isothiocyanate-peanut agglutinin (Sigma Aldrich Corporation), and assessed with fluorescent microscopy (100-200 sperm/sample) to determine percent of intact acrosomes (ACRO) [36]. Acrosome status was classified as intact, partially intact or not intact and assessed using fluorescence (excitation 465-495/emission >515) on a Zeiss Axioskop Fluorescent microscope equipped with AxioCam ERc5s. Oocytes and embryos stained with Hoechst were visualized using fluorescence (excitation  $375 \pm 28$  nm; emission > 435 nm). Images were obtained and processed using Zen 3.1 (blue edition; Carl Zeiss Microscopy GmbH, Germany).

### *Statistical Analyses*

Normality was assessed using the Shapiro-Wilk test at a 95% confidence interval. If a normal distribution was reported, the mean values  $\pm$  SEM were reported in the results. If there was a non-normal distribution, the median (minimum-maximum) values were reported in the results. The effect of treatment, time, and treatment by time on post-thaw parameters was assessed using mixed model analysis of variance (ANOVA) with animal as a random factor. Descriptive analysis of number of sperm bound to mature oocytes per animal was reported as mean values  $\pm$  SEM. All analyses were performed in SPSS 28 with an  $\alpha= 0.05$ .

## **Results**

From 2019 through 2022 (a total of 3 field seasons), semen was collected from 12 adult male felids (n=6 ocelots; n=6 bobcats). Mean ( $\pm$ SEM) and/or median (minimum- maximum) values for pre-freeze seminal traits in ocelots and bobcats assessed in this study are presented in **Table 3.1**. For bobcats (B) and ocelots (O), there was a significant effect of post-thaw time on acrosome integrity (B,  $p<0.001$ ; O,  $p<0.001$ ), percent motility (B,  $p<0.001$ ; O,  $p<0.001$ ), and forward progressive motility (B,  $p<0.001$ ; O,  $p<0.001$ ) [**Figure 3.3**] with all parameters declining over time. There was no significant effect of treatment (URF vs STRAW) or treatment by time for either species. **Table 3.2** shows the mean fertilization percentage at 48 hours post-insemination for both treatments (URF vs STRAW) and the mean ( $\pm$  SEM) of number of sperm

bound to mature oocytes. For ocelots, there was only one male for which both freezing techniques were applied after urethral catheterization with the straw sample showing a greater fertilization percentage (URF, 29.4%; STRAW, 61.5%). For bobcats, fertilization percentages were similar between the two cryopreservation techniques. When straw cryopreservation was compared for samples recovered with the two collection techniques (UC vs EEJ), fertilization percentages were greater for UC.

## Discussion

To our knowledge, this is the first attempt to collect and preserve semen samples from free-ranging ocelots and bobcats. Our approach used the same cryodiluents, collection methods, and cryopreservation techniques previously reported for ocelots and bobcats in human-managed populations, but with our specific methodology adapted for field usage. Post-thaw, time had the greatest effect on sperm quality with the largest declines occurring from pre-freeze to immediate post-thaw and to 6 hours post-thaw. These findings may increase our level of concern for sperm viability and longevity within the reproductive tract after artificial insemination procedures. In vivo, sperm are stored within the isthmus of the oviduct [41], requiring a period of incubation for capacitation (gaining competence to fertilize an oocyte) [42], and then are released close to the time of ovulation to complete fertilization [43-44].

Over time, significant declines also were noted in post-thaw acrosomal integrity, percent motility, and forward progressive motility [**Figure 3.3**]. Sperm motility and acrosomal integrity are essential for sperm fertilization [44-47] with declines following cryopreservation in other studies [48] associated with decreasing in-vitro fertilization (IVF) success [46]. In other non-domestic feline species, such as the cheetah, these factors proved to be most impactful on oocyte penetration and fertilization percentages over time with IVF [17].

One sperm variable, rate of forward progression, is arguably even more important than the percentage of motility as 10% or 50% of sperm could be moving, but if not in a forward direction, likely will not contact the oocyte. In addition, acrosomal integrity is imperative for the process of capacitation in order for fertilization to occur and the creation of an embryo to be successful. Once binding of the sperm to the oocyte takes place, acrosomal exocytosis (the acrosome reaction) will commence, allowing the sperm to penetrate the zona pellucida (outer layer of the oocyte), fuse with the vitelline membrane, and trigger embryonic development [42].

Although artificial insemination procedures can be timed relative to ovulation, declines in motility, progressive motility, and acrosomal integrity could further hinder success decreasing sperm longevity and viability. These declines in seminal quality have the potential to reduce the likelihood of successful sperm capacitation, the sperms' ability to locate the oocyte, and the acrosomal reaction needed for fertilization.

Although differences in sperm quality were not significant between the two cryopreservation methods, straw freezing tended to produce superior post-thaw parameters, as shown in **Figure 3.3**, in ocelots, regardless of collection technique (UC vs EEJ). For the comparison of collection method (UC vs EEJ) in ocelots, straw samples produced a greater percentage of oocyte cleavage with semen collected by UC [**Table 3.2**]. One potential reason for this difference is the inclusion of only viable, non-urine contaminated samples for the UC method, because urine contaminated UC samples were too compromised for cryopreservation. Consistent urine contamination of our catheter collected samples increased our concern for other aspects of the project and our larger ocelot conservation initiative as subsequent capture of a specific individual is not guaranteed, making each collection crucial to ocelot conservation. Therefore, we added electroejaculation into our sampling protocol as a second method for sperm collection within the final season decreasing our available number of attempts for EEJ application and overall collection numbers using this technique. For EEJ samples that were contaminated with urine, salvaging methods ( i.e., immediate dilution and centrifugation) allowed recovery of some viable sperm for cryopreservation, but possible with subtle damage. This finding suggests that UC samples without urine contamination can be effectively frozen by the traditional straw method, with superior results compared to urine-damaged EEJ samples. However, regardless of urine contamination, the EEJ collection method with subsequent straw freezing, remains the most consistent method to obtain superior post-thaw viability and in-vitro fertilization success in ocelots, in which urine contamination during semen collection is a common occurrence. Further assessment of the EEJ collection method with subsequent URF cryopreservation may be warranted to improve potential for field usage.

In contrast to ocelots, bobcat semen samples frozen by URF had consistently greater post-thaw seminal values as compared to straw samples, but fertilization percentages were similar between the two cryopreservation methods. Previous studies of zoo-based bobcats examined post-thaw traits in bobcat semen collected by EEJ and frozen in TEST (egg yolk

based) medium using straw cryopreservation [23]. They observed that cryopreserved bobcat sperm could fertilize domestic cat oocytes with a cleavage rate of 46% [23]. The fertilization rate, with the cryopreservation medium used in this study, was similar to that of previous studies using the same cryodiluent in other felid species [37]. However, compared to egg yolk-based media, cryomedium containing soy lecithin is often preferable, since non-animal based proteins avoid the greater risk of bacterial contamination, and reduce regulatory barriers for international transport and use. Based on our initial results, additional studies in bobcats should include assessment of EEJ and straw freezing using the SOY-based cryodiluent and further investigation of EEJ combined with URF. We did not include electroejaculation as a collection technique in our study due to the stable nature of the species and further reproductive technologies, such as artificial insemination procedures, not being including in the scope of this project for bobcats.

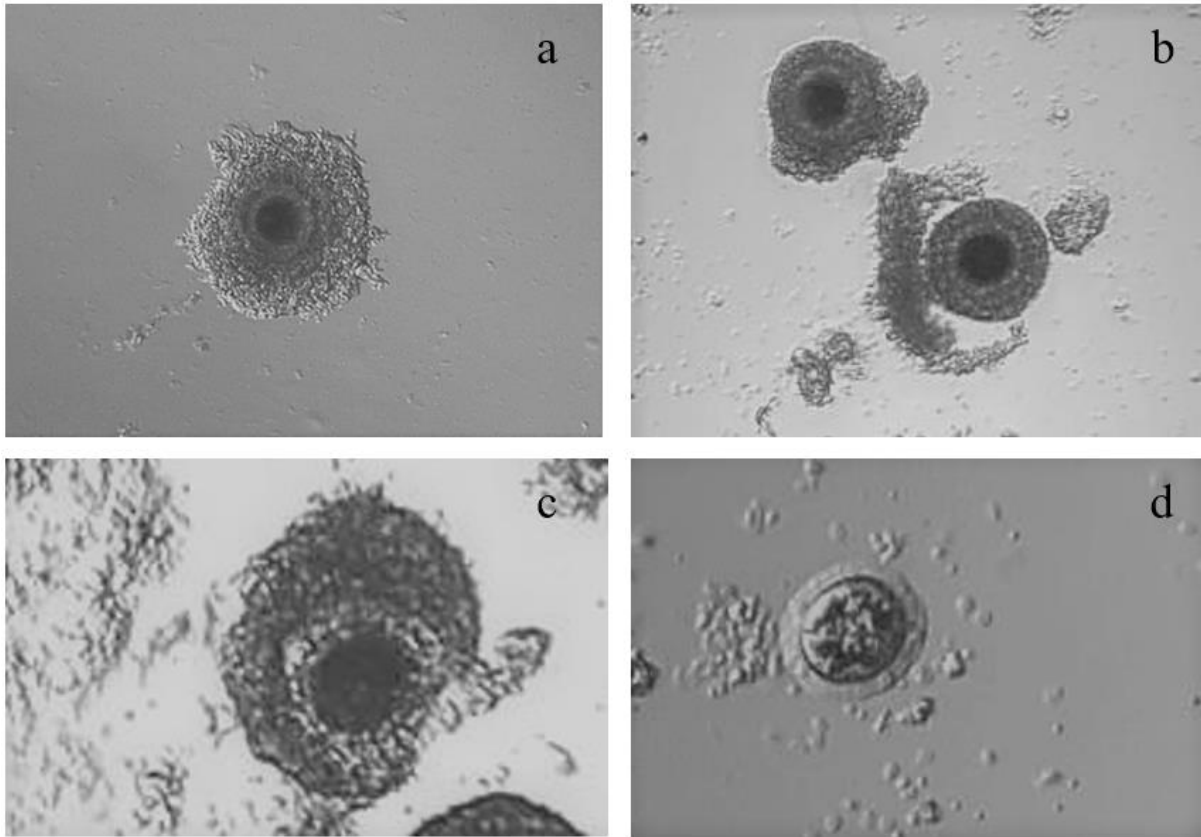
Declines in quality of frozen-thawed semen is a common occurrence in domestic cats, with reports of up to 50% loss of acrosomal integrity [19] and 30% loss of motility [46]. Reasons for sperm quality decline may be related to ice crystal formation with the rupture of cellular membranes during rapid cooling [49], damage to the internal mitochondrial structure [50], and premature acrosomal reaction and capacitation shortening the life of sperm and reducing fertility [47]. Although we have documented similar declines in acrosomal integrity and motility in ocelots and bobcats, including CASA systems or alternative in-vitro assays, such as homologous zona pellucida (ZP) adhesion and/or homologous or heterologous (intraspecific) ZP penetration, could further evaluate various motility parameters and be useful for identifying capacitated conditions [47, 51]. For both species there were a higher number of accessory sperm bound to the zona pellucida for samples frozen by straw cryopreservation. Although fertilization percentages were not much different between the two freezing methods in most cases, the slightly higher fertilization percentages with straw samples suggest that greater acrosomal damage may have occurred with the URF method with fewer acrosome remaining intact post-thaw over time. Further assessment of capacitated conditions and acrosomal function could increase our understanding of these differences.

Although we demonstrated that frozen-thawed ocelot and bobcat sperm could fertilize domestic cat oocytes in-vitro, it is unknown whether a similar result would hold true in vivo. Many studies have investigated IVF success using domestic cat oocytes to test functionality of frozen-thawed sperm samples from non-domestic feline species, showing a lack of hindrance to

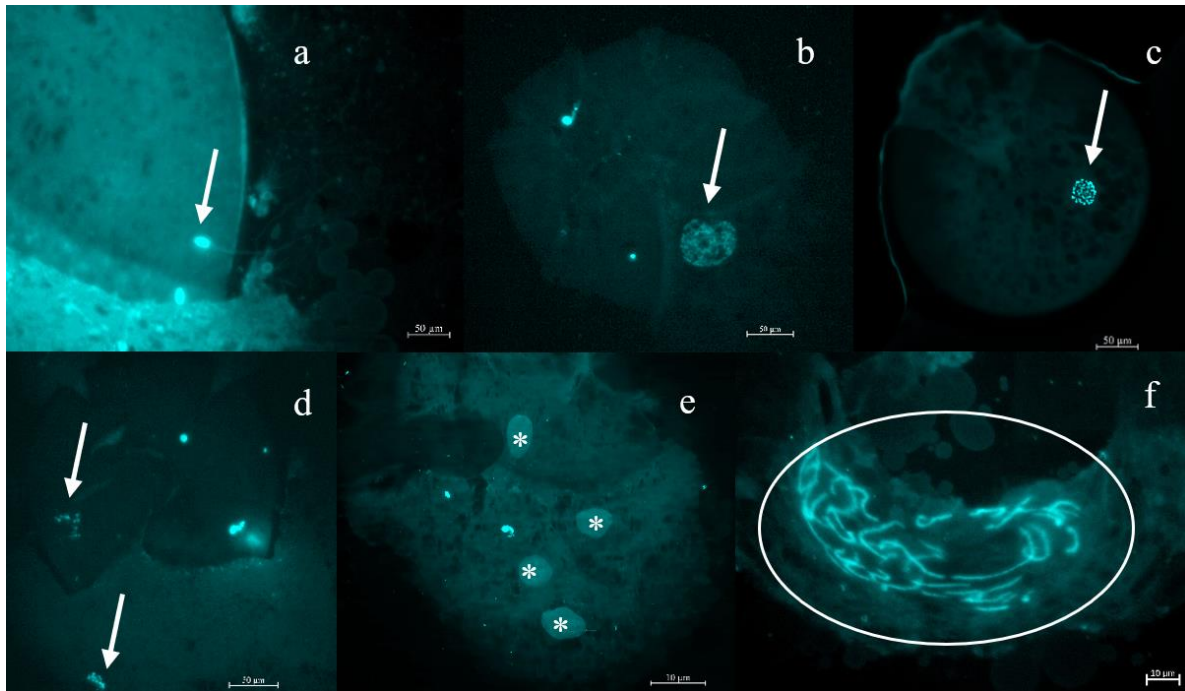


cross-species fertilization [7, 21, 35, 52-54], and allowing this method to be valuable for assessing initial fertilization capabilities. Moreover, this technique provides oocytes that are more readily available, as the collection of conspecific oocytes from wild felids for testing presents multiple obstacles (i.e., small population sizes, endangered intractable species, complicated oocyte recovery procedures, wastage of valuable genetic resources, etc.). This method further relies on the use of incubators and media formulations to create an ideal environment for oocyte maturation, gamete support, and embryo formation introducing many levels in which success could be affected by system errors, such as incubator malfunction, incorrect media formulations, and low quality oocytes from aging domestic felines. While our initial cleavage rates using heterologous in-vitro fertilization methods indicate the capability of these sperm samples to successfully fertilize oocytes, absolute confirmation of post-thaw sperm function would require examination of fertilization and subsequent pregnancies in vivo using semen samples cryopreserved with both methods.

For free-ranging populations, management of genetic diversity by translocation can be politically complicated with increasing concern for introduction of naïve pathogens to a population and/or naïve individuals to a new environment. Although the cleavage rate for URF and STRAW cryopreserved semen samples were similar for both species, EEJ-STRAW collection and cryopreservation combination performed most consistently for ocelots despite urine contamination. Time had a significant effect of sperm quality and viability post-thaw indicating the need for semen of higher pre-freeze quality to mitigate damage sustained during cryopreservation. Additionally, this information recommends the use of electroejaculation for semen collection and subsequent straw cryopreservation for free-ranging ocelots to provide the greatest chance for successful collection and storage of genetic diversity. For bobcats, UC-URF provided an adequate collection and cryopreservation method, but further combinations and techniques should be further explored. These techniques allow for semen banking of free-ranging felids and provides a means of preserving genetic diversity without the need to rely solely on the movement of individuals between distant populations.



**Figure 3.1: Classification of cumulus oocyte complexes (COCs).** Grade 1 (a) = dark, uniform ooplasm with spherical eccentric nucleus, 5+ layers of tight cumulus cells surrounding the entire oocyte, complete intact zona pellucida; Grade 2 (b) = dark uniform ooplasm, lesser amounts of cumulus (<5 layers) surrounding the oocyte, and intact zona pellucida; Grade 3 (c) = clear or clear patches in the ooplasm, very little cumulus, tear(s) in ZP; Grade 4 (d) = severe mosaic transparency in ooplasm, sparse complement of cumulus or denuded.



**Figure 3.2: Classification of oocytes and embryos.** (a) Sperm binding to the zona pellucida. (b) Germinal Vesicle (GV). (c) Meiosis I cell (MI). (d) Meiosis II cell (MII). (e) 4-cell Embryo (E). (f) Pronuclear cell (PN). White arrows signify important cell structure for each cell type; \*, denotes 4 nuclei of the 4-cell embryo; white circle, cellular material splitting denoting a pronuclear cell.

**Table 3.1: Mean ( $\pm$ SEM) values for pre-freeze seminal traits in samples processed for cryopreservation.**

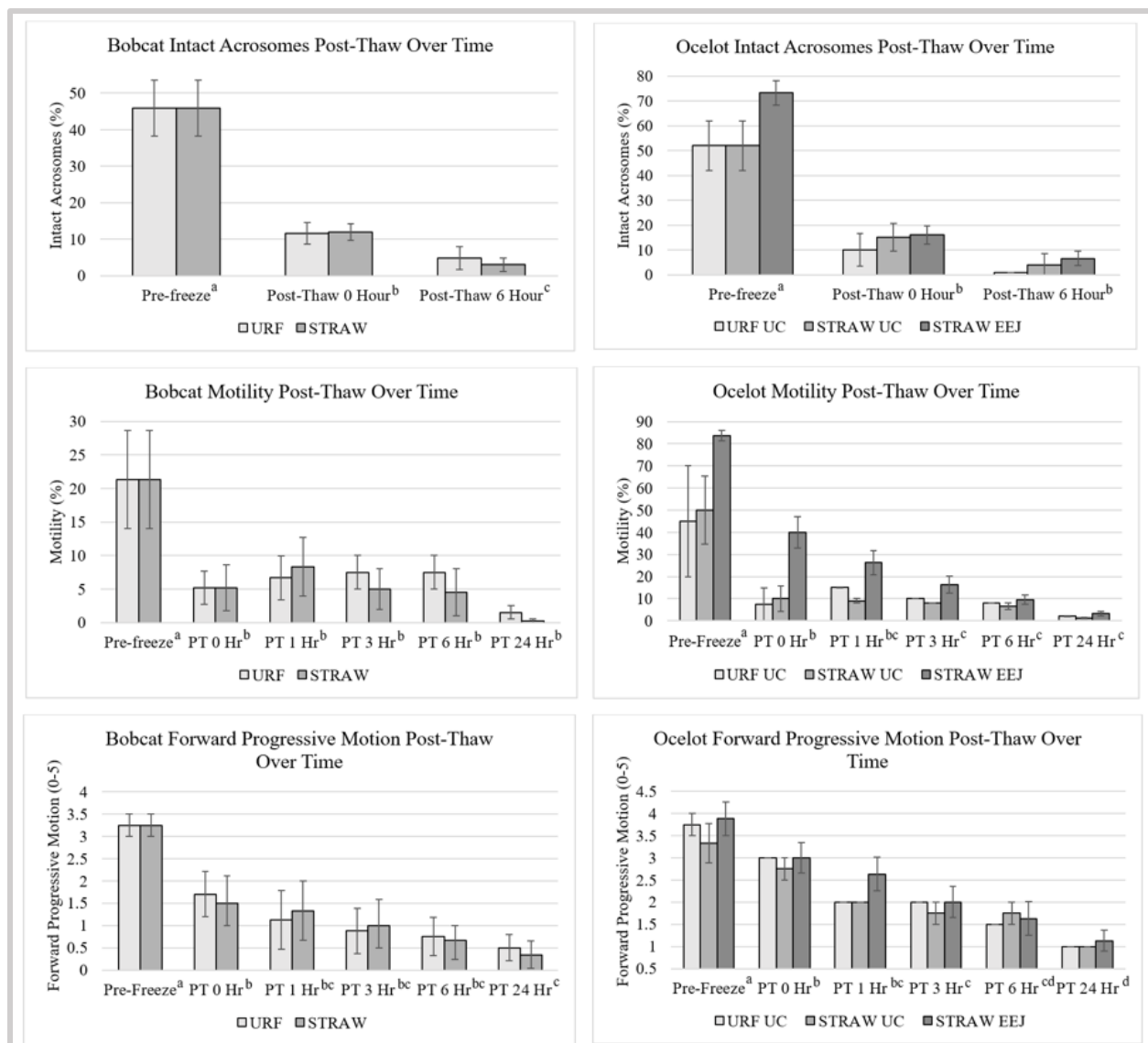
	Ocelot UC (n= 3)	Ocelot EEJ (n=4)	Bobcat UC (n= 6)
<b>VOL</b>	113.5 ( $\pm$ 34.5)	468 (200-922)*	30.9 (14-60)*
<b>CONC</b>	415.2 ( $\pm$ 120.3)	29.5 (0-97)*	48.25 (5.5-122.5)*
<b>TSE</b>	79.25 (23.3-269.5)*	53.55 (0-152.5)*	2.28 (0.137-36.8)*
<b>TMS</b>	55.12 (14-80.85)*	42.85 (0-137.3)*	0.195 (0.003-14.7)*
<b>ACRO</b>	52 ( $\pm$ 10.1)	73.3 ( $\pm$ 5.0)	45.83 ( $\pm$ 7.7)
<b>MORPH</b>	40.3 ( $\pm$ 11)	58.1 ( $\pm$ 12.8)	23.08 ( $\pm$ 3.86)
<b>PPM</b>	50 ( $\pm$ 15.3)	83.8 ( $\pm$ 2.4)	21.3 ( $\pm$ 7.3)
<b>RFP</b>	3.3 ( $\pm$ 0.44)	3.9 ( $\pm$ 0.4)	3.25 ( $\pm$ 0.25)

UC, urethral catheterization collection technique; EEJ, electroejaculation collection technique; VOL, semen volume ( $\mu$ l); CONC, sperm concentration ( $\times 10^6$  / ml); TSE, total sperm per ejaculate ( $\times 10^6$ ); TMS, total motile sperm ( $\times 10^6$ ); ACRO, intact acrosome status (%); MORPH, normal sperm morphology (%); PPM, percent progressively motile (%); RFP, rate of forward progression (0-5); SEM, Standard Error of the Mean; \*values reported are median values (min-max) due to a non-normal distribution.

**Table 3.2: Cleavage percentage at 48 hours post-insemination of domestic cat oocytes (mature only) with non-domestic cat sperm cryopreserved by ultra-rapid freezing or straw freezing.**

	UC-URF n=1	UC-STRAW n=2	EEJ STRAW n=4
<b>Ocelots</b>			
1	29.4 (17; SB 1.88 $\pm$ 0.36)	61.5 (13; SB 2.38 $\pm$ 0.86)	
2		61.5 (13; SB 2.15 $\pm$ 0.48)	
2			31.3 (16; SB 1.56 $\pm$ 0.38)
4			33.3 (12; SB 0.92 $\pm$ 0.34)
5			15.4 (13; 0.78 $\pm$ 0.26)
6			27.3 (11; SB 1.0 $\pm$ 0.18)
<b>Bobcats</b>	n=3	n=2	
7	100 (8; SB 1.25 $\pm$ 0.25)		
8	45.5 (11; SB 0.91 $\pm$ 0.83)	54.5 (11; SB 1.27 $\pm$ 0.43)	
9	8.3 (12; SB 0.17 $\pm$ 0.11)	16.7 (18; SB 0.56 $\pm$ 0.26)	

Data are reported as the percent of mature oocytes that cleaved (total mature oocytes per treatment). Collection methods: UC= urethral catheterization, EEJ= electroejaculation; Cryopreservation methods: URF= ultra-rapid freezing, STRAW= straw freezing. SB= sperm bound to zona pellucida for mature oocytes (mean  $\pm$  SEM)



**Figure 3.3: Percentage of intact acrosomes, percent progressive motility, and forward progressive motion over time for bobcats and ocelots comparing two semen cryopreservation techniques.** URF: ultra-rapid freezing; STRAW: straw freezing; UC: urethral catheterization collection method; EEJ: electroejaculation collection method; PT: post-thaw; Hr: hours. Standard error bars are represented. Lower case superscripts denote differences ( $p < 0.05$ ) among time points. Treatment (URF vs STRAW) did not differ and therefore, time points were assessed collectively.

## References

- [1] J.E. Janečka, M.E. Tewes, L.L. Laack, L.I. Grassman, A.M. Haines, R.L. Honeycutt. Small effective population sizes of two remnant ocelot populations (*Leopardus pardalis albescens*) in the United States. *Conserv Genet.* 9:4 (2008) 869-878. <https://doi.org/10.1007/s10592-007-9412-1>
- [2] J.E. Janečka, M.E. Tewes, L.L. Laack, L.I. Grassman, A.M. Haines, D.B. Shindle, B.W. Davis, W.J. Murphy, R.L. Honeycutt. Reduced genetic diversity and isolation of remnant ocelot populations occupying a severely fragmented landscape in southern Texas. *Anim Conserv.* 14:6 (2011) 608-619. <https://doi.org/10.1111/j.1469-1795.2011.00475.x>
- [3] J.E. Janečka, M.E. Tewes, L.L. Laack, A. Caso, L.I. Grassman, R.L. Honeycutt. Loss of Genetic Diversity among Ocelots in the United States during the 20th Century Linked to Human Induced Population Reductions. *Plos One.* 9:2 (2014) e89384. <https://doi.org/10.1371/journal.pone.0089384>
- [4] P.W. Hedrick, S.T. Kalinowski. Inbreeding Depression in Conservation Biology. *Annu Rev Ecol Syst.* 31:1 (2002) 139-162. <https://doi.org/10.1146/annurev.ecolsys.31.1.139>
- [5] D.H. Reed. Relationship between Population Size and Fitness. *Conserv Biol.* 19:2 (2005) 563-568. <https://www.jstor.org/stable/3591269>
- [6] D.H. Reed, A.C. Nicholas, G.E. Stratton. Genetic quality of individuals impacts population dynamics. *Anim Conserv.* 10:3 (2007) 275-283. <https://doi.org/10.1111/j.1469-1795.2007.00120.x>
- [7] W.F. Swanson. Application of assisted reproduction for population management in felids: the potential and reality for conservation of small cats. *Therio.* 66 (2006) 49-58. [10.1016/j.theriogenology.2006.03.024](https://doi.org/10.1016/j.theriogenology.2006.03.024)
- [8] D.E. Wildt, W.F. Rall, J.K. Critser, S.L. Monfort, U.S. Seal. Genome resource banks: Living collections for biodiversity conservation. *BioScience.* 47:10 (1997) 689-698.

- [9] D.E. Wildt, T.L. Roth. Assisted reproduction for managing and conserving threatened felids. *International Zoo Yearbook*. 35:1 (1997) 164-172. <https://doi.org/10.1111/j.1748-1090.1997.tb01207.x>
- [10] W.V. Holt, A.R. Pickard, J.C. Rodger, D.E. Wildt. Reproductive Science and Integrated Conservation. The Zoological Society of London, The Press Syndicate of the University of Cambridge. (2003). <https://assets.cambridge.org/97805218/12153/sample/9780521812153ws.pdf>
- [11] I. Yu, N. Songsasen, R.A. Godke, S.P. Leibo. Differences among dogs in response of their spermatozoa to cryopreservation using various cooling and warming rates. *Cryobiol.* 44 (200) 62-78. [https://doi.org/10.1016/s0011-2240\(02\)00005-6](https://doi.org/10.1016/s0011-2240(02)00005-6)
- [12] S.P. Leibo, N. Songsasen. Cryopreservation of gametes and embryos of non-domestic species. *Therio.* 57 (2002) 303-26. [https://doi.org/10.1016/s0093-691x\(01\)00673-2](https://doi.org/10.1016/s0093-691x(01)00673-2)
- [13] W.F. Swanson, J.G. Howard, T.L. Roth, J.L. Brown, T. Alvarado, M. Burton, D. Starnes, D.E. Wildt. Responsiveness of ovaries to exogenous gonadotrophins and laparoscopic artificial insemination with frozen–thawed spermatozoa in ocelots (*Felis pardalis*). *J Reprod Fertil.* 106:1 (1996a) 87-94. [10.1530/jrf.0.1060087](https://doi.org/10.1530/jrf.0.1060087)
- [14] W.F. Swanson, T.L. Roth, E. Blumer, S.B. Citino, D. Kenny, D.E. Wildt. Comparative cryopreservation and functionality of spermatozoa from the normospermic jaguar (*Panthera onca*) and teratospermic cheetah (*Acinonyx jubatus*). *Therio.* 45:1 (1996b) 241. [10.1016/0093-691X\(96\)84714-5](https://doi.org/10.1016/0093-691X(96)84714-5)
- [15] C.C. Platz, D.E. Wildt, S.W. Seager. Pregnancy in the domestic cat after artificial insemination with previously frozen spermatozoa. *J Reprod Fertil.* 52:2 (1978) 279-282. [10.1530/jrf.0.0520279](https://doi.org/10.1530/jrf.0.0520279)
- [16] A.M. Donoghue, L.A. Johnston, D.L. Armstrong, L.G. Simmons, T. Gross, R.L. Tilson, D.E. Wildt. Ability of thawed tiger (*Panthera tigris*) spermatozoa to fertilize conspecific eggs and bind and penetrate domestic cat eggs in vitro. *J Reprod Fertil.* 96 (1992a) 555-564. [10.1530/jrf.0.0960555](https://doi.org/10.1530/jrf.0.0960555)
- [17] A.M. Donoghue, J.G. Howard, A.P. Byers, K.L. Goodrowe, M. Bush, E. Blumer, J. Lukas, J. Stover, K. Snodgrass, D.E. Wildt. Correlation of sperm viability with gamete interaction and

fertilization in vitro in the cheetah (*Acinonyx jubatus*). *Biol Reprod.* 46 (1992b) 1047-1056.

[10.1095/biolreprod46.6.1047](https://doi.org/10.1095/biolreprod46.6.1047)

[18] D. Zambelli, B. Caneppele, C. Castagnetti, S. Belluzzi. Cryopreservation of Cat Semen in Straws: Comparison of Five Different Freezing Rates. *Reprod Dom Anim.* 37:5 (2002) 310-313.

<https://doi.org/10.1046/j.1439-0531.2002.00365.x>

[19] M.A. Hay, K.L. Goodrowe. Comparative cryopreservation and capacitation of spermatozoa from epididymides and vasa deferentia of the domestic cat. *J Reprod Fertil.* 47 (1993) 297-305.

PMID: 8229940.

[20] A.P. Byers, A.G. Hunter, U.S. Seal, G.A. Binczik, E.F. Grahan, N.J. Reindl, R.L. Tilson. In vitro induction of capacitation of fresh and frozen spermatozoa of the Siberian tiger (*Panthera tigris*). *J Reprod Fertil.* 86:2 (1989) 599-607.

[10.1530/jrf.0.0860599](https://doi.org/10.1530/jrf.0.0860599)

[21] K. Thiangtum, W.F. Swanson, J.G. Howard, W. Tunwattana, D. Tongthainan, W. Wichasilpa, P. Patumrattanathan, T. Pinyopoommintr. Assessment of basic seminal characteristics, sperm cryopreservation and heterologous in vitro fertilisation in the fishing cat (*Prionailurus viverrinus*). *Reprod Fertil Dev.* 18:3 (2006) 373-82.

<https://doi.org/10.1071/rd05098>

[22] M.A. Stoops, J.B. Bond, H.L. Bateman, M.K. Campbell, G.P. Levens, T.R. Bowsher, S.T. Ferrell, W.F. Swanson. Comparison of different sperm cryopreservation procedures on post-thaw quality and heterologous in vitro fertilization success in the ocelot (*Leopardus pardalis*). *Reprod Fertil Dev.* 19:5 (2007) 685-94.

<https://doi.org/10.1071/rd06078>

[23] A. Gañán, R. González, A. Sestelo, J.J. Garde, I. Sánchez, J.M. Aguilar, M. Gomendio, E.R.S. Roldan. Male reproductive traits, semen cryopreservation, and heterologous in vitro fertilization in the bobcat (*Lynx rufus*). *Therio.* 74 (2009) 341-352.

<https://doi.org/10.1016/j.theriogenology.2009.03.002>

[24] M.P. Rosato, N. Iaffaldano. Cryopreservation of rabbit semen: Comparing the effects of different cryoprotectants, cryoprotectant-free vitrification, and the use of albumin plus osmoprotectants on sperm survival and fertility after standard vapor freezing and vitrification. *Therio.* 79:3 (2013) 508-516.

<https://doi.org/10.1016/j.theriogenology.2012.11.008>



- [25] E. Isachenko, V. Isachenko, J.M. Weiss, R. Kreienberg, I.I. Katkov, M. Schulz, A.G.-M.I. Lulat, M.J. Ridopatron, R. Sanchez. Acrosomal status and mitochondrial activity of human spermatozoa vitrified with sucrose. *Reprod.* (Cambridge, England), 136:2 (2008) 167-73. <https://doi.org/10.1530/rep-07-0463>.
- [26] W.F. Swanson, H.L. Bateman, L.M. Vansandt. Urethral catheterization and sperm vitrification for simplified semen banking in felids. *Reprod Domest Anim.* 52:2 (2017) 255-260. <https://doi.org/10.1111/rda.12863>
- [27] V.A. Conforti, H.L. Bateman, M.W. Schook, J. Newsom, L.A. Lyons, R.A. Grahn, J.A. Deddens, W.F. Swanson. Laparoscopic oviductal artificial insemination improves pregnancy success in exogenous gonadotropin-treated domestic cats as a model for endangered felids. *Biol Reprod.* 89:1 (2013) 4. <https://doi.org/10.1095/biolreprod.112.105353>
- [28] W.F. Swanson. Laparoscopic Oviductal Embryo Transfer and Artificial Insemination in Felids – Challenges, Strategies and Successes. *Reprod Domest Anim.* 47:6 (2012) 136-140. <https://doi.org/10.1111/rda.12069>
- [29] W.F. Swanson, J. Newsom, L.A. Lyons, R.A. Grahn, H.L. Bateman. Ovarian Down-Regulation with Oral Progestin for Fixed-Time Laparoscopic Oviductal Artificial Insemination with Freshly-Collected and Frozen-Thawed Spermatozoa in Domestic Cats. *Reprod Fertil Dev.* 26:1 (2013) 143. <http://dx.doi.org/10.1071/RDv26n1Ab58>.
- [30] J.D. Johnson, H.L. Bateman, J. Newsom, L.M. Vansandt, W.F. Swanson. Semen vitrification in felids- a simplified cryopreservation method for field use. In ‘Proceeding of the Annual Conference American Association of Zoo Veterinarians.’ American Association of Zoo Veterinarians: Portland, OR, USA. (2015) 124-125.
- [31] M. Kelly, D. Morin, C.A. Lopez-Gonzalez. *Lynx rufus*. The IUCN Red List of Threatened Species 2016: e.T12521A50655874. <https://dx.doi.org/10.2305/IUCN.UK.2016-1.RLTS.T12521A50655874.en>. (Accessed on 06 January 2022)
- [32] D.E. Wildt, M.C. Schiewe, P.M. Schmidt, K.L. Goodrowe, J.G. Howard, L.G. Phillips, S.J. O’Brien, M. Bush. Developing animals models system for embryo techniques in rare and

endangered wildlife. *Therio.* 25: (1986) 33-51. [https://dx.doi.org/10.1016%2F0093-691X\(86\)90182-2](https://dx.doi.org/10.1016%2F0093-691X(86)90182-2)

[33] B. Pukazhenth, P. Comizzoli, A.J. Travis, D.E. Wildt. Applications of emerging technologies to the study and conservation of threatened and endangered species. *Reprod Fert Dev.* 18 (2006) 77-90. <https://doi.org/10.1071/rd05117>

[34] J.R. Herrick, J.B. Bond, G.M. Magarey, H.L. Bateman, R.L. Krisher, S.A. Dunford, W.F. Swanson. Development of a feline optimized culture medium: effects of ions, carbohydrates, essential amino acids, vitamins and serum on the development and metabolism of IVF-derived feline embryos relative to embryos grown in vivo. *Biol Reprod.* 76 (2007) 858-870. <https://doi.org/10.1095/biolreprod.106.058065>

[35] J.R. Herrick, M. Campbell, G. Levens, T. Moore, K. Benson, J. D'Agostino, G. West, D.M. Okeson, R. Coke, S.C. Portacio, K. Leiske, C. Kreider, P.J. Polumbo, W.F. Swanson. In vitro fertilization and sperm cryopreservation in the black-footed cat (*Felis nigripes*) and sand cat (*Felis margarita*). *Biol of Reprod.* 82 (2010) 552-562. <https://doi.org/10.1095/biolreprod.109.081034>

[36] M.M. Vick, H.L. Bateman, C.A. Lambo, W.F. Swanson. Improved cryopreservation of domestic cat sperm in a chemically defined medium. *Therio.* 78:9 (2012) 2120-8. <https://doi.org/10.1016/j.theriogenology.2012.08.009>

[37] L.M. Vansandt, H.L. Bateman, A.G. Miller, J.R. Herrick, A. Moresco, R. González, M.E. Iwaniuk, W.F. Swanson. Cross-species efficacy of a chemically-defined, soy lethicin-based cryomedium for semen banking in imperiled wild felids. *Therio.* 159 (2021) 108-115. <https://doi-org.utk.idm.oclc.org/10.1016/j.theriogenology.2020.10.021>

[38] J.G. Howard, D.E. Wildt. Semen Collection, Analysis and Cryopreservation in Nondomestic Mammals, In: Morrow DA, editor. Current therapy in theriogenology : diagnosis, treatment, and prevention of reproductive diseases in small and large animals, Saunders; 2nd edition, (1986) 1047-1053.

[39] A.E. Crosier, B.S. Pukazhenth, J.N. Henghali, J. Howard, A.J. Dickman, L. Marker, D.E. Wildt. Cryopreservation of spermatozoa from wild-born Namibian cheetahs (*Acinonyx jubatus*)

and influence of glycerol on cryosurvival. *Cryobiol.* 52 (2006) 169-181.

<https://doi.org/10.1016/j.cryobiol.2005.10.011>

[40] T. Wood, D. Wildt. Effect of the quality of the cumulus–oocyte complex in the domestic cat on the ability of oocytes to mature, fertilize and develop into blastocysts in vitro. *Reprod.* 110:2 (1997) 355-360. <https://doi.org/10.1530/jrf.0.1100355>

[41] S.S. Suarez. Regulation of sperm transport in the mammalian oviduct, In: C. Gabno (Ed.), *Spermatology*. Cache Review Progress, Vienna. (1999).

[42] R. Yanagimachi. Mammalian fertilisation, In: E. Knobil, J.D. Neill (Eds.), *The Physiology of Reproduction*. Raven Press, NY. (1994) 189-317.

[43] C.D. Thaler, R.A. Cardullo. The initial molecular interaction between mouse sperm and the zona pellucida is a complex binding event. *J Biol Chem.* 271 (1996) 23289-23297.

<https://doi.org/10.1074/jbc.271.38.23289>

[44] E. Töpfer-Petersen, A.M. Petrounkina, M. Ekhlesi-Hundrieser. Oocyte-sperm interactions. *Anim Reprod Sci.* 60–61 (2000) 653– 662. [https://doi.org/10.1016/s0378-4320\(00\)00128-7](https://doi.org/10.1016/s0378-4320(00)00128-7)

[45] J.G. Howard. Semen collection and analysis in carnivores. In: Fowler ME, editor. *Zoo and Wild Animal Medicine*, Vol. 3. WB Saunders Co. (1993) 390–398.

[46] T. Lengwinat, S. Blottner. In vitro fertilization of follicular oocytes of domestic cat using fresh and cryopreserved epididymal spermatozoa. *Anim Reprod Sci.* 35 (1994) 291–301.

[https://doi.org/10.1016/0378-4320\(94\)90044-2](https://doi.org/10.1016/0378-4320(94)90044-2)

[47] G.C. Luvoni, E. Kalchschmidt, G. Marinoni. Conservation of feline semen. Part II: cold-induced damages on spermatozoal fertilizing ability. *J Feline Med Surg.* 5 (2003) 257–263.

[https://doi.org/10.1016/s1098-612x\(03\)00030-5](https://doi.org/10.1016/s1098-612x(03)00030-5)

[48] W.F. Swanson, D.E. Wildt. Strategies and progress in reproductive research involving small cat species. *Int Zoo Yrbk.* 35 (1997) 152–9. <https://doi.org/10.1111/j.1748-1090.1997.tb01205.x>

[49] B. Pukazhenthil, R. Spindler, D.E. Wildt, J.G. Howard. Sensitivity of domestic cat (*Felis catus*) sperm from normospermic versus teratospermic donors to cold-induced acrosomal damage. *Biol of Reprod.* 51 (1999) 135-141. <https://doi.org/10.1095/biolreprod61.1.135>

- [50] P.F. Watson. The preservation of semen in mammals, In: C.A. Finn (Ed.) Oxford Reviews of Reproductive Biology Vol. 1. Oxford: Oxford University Press. (1979) 283-351.
- [51] J.J. Stachecki, K.A. Ginsburg, R.E. Leach, D.R. Armandt. Computer-assisted semen analysis (CASA) of epididymal sperm form the domestic cat. *J of Androl.* 15 (1993) 60-65. PMID: 8473238.
- [52] N. Gañán, R. González, J.J. Garde, F. Martínez, A. Vargas, M. Gomendio, E.R. Roldan. Assessment of semen quality, sperm cryopreservation and heterologous IVF in the critically endangered Iberian lynx (*Lynx pardinus*). *Reprod Fertil Dev.* 21:7 (2009) 848-59.  
<https://doi.org/10.1071/rd08226>
- [53] D.L. Baudi, K. Jewgenow, B.S. Pukazhenth, K.M. Spercoski, A.S. Santos, A.L. Reghelin, M.V. Candido, M.L. Javorouski, G. Müller, R.N. Morais. Influence of cooling rate on the ability of frozen-thawed sperm to bind to heterologous zona pellucida, as assessed by competitive in vitro binding assays in the ocelot (*Leopardus pardalis*) and tigrina (*Leopardus tigrinus*). *Therio.* 69:2(2008) 204-11. <https://doi.org/10.1016/j.theriogenology.2007.09.013>
- [54] P. Thuwanut, K. Chatdarong, A.S. Bergqvist, L. Söderquist, K. Thiangtum, D. Tongthainan, E. Axner. The effects of antioxidants on semen traits and in vitro fertilizing ability of sperm from the flat-headed cat (*Prionailurus planiceps*). *Therio.* 76:1 (2011) 115-125.  
<https://doi.org/10.1016/j.theriogenology.2011.01.024>

**Chapter IV: Laparoscopic Oviductal Artificial Insemination with Frozen  
Semen for Conservation Management of Ocelots in Southern Texas**

## **Abstract**

Free-ranging ocelot populations in the US have declined to less than 80 cats remaining in southern Texas. Consequently, increased inbreeding depression may negatively impact their fertility, reduce breeding success and cause regional extinction. In conjunction with novel methods of semen collection and cryopreservation, application of laparoscopic oviductal artificial insemination (LO-AI) with frozen semen, which was successfully used with zoo-housed ocelots, is described herein as a new conservation tool for wild ocelot populations. In the present study, the goal was to assess the feasibility of LO-AI, using frozen semen sourced from wild Texas ocelots, to produce pregnancies in zoo-based females. Semen recovered from wild ocelots (n=4) via urethral catheterization and/or electroejaculation during anesthesia or post-mortem after vehicular trauma, was cryopreserved by ultra-rapid freezing and/or traditional straw freezing. Ovarian activity and ovulation of zoo-housed ocelots (n=5) were synchronized for LO-AI using oral progestin treatment (30 days), followed by a 7 to 9-day withdrawal period and administration of gonadotropin (eCG/pLH). At laparoscopy (~38 hours post-gonadotropin administration), frozen-thawed semen was deposited into oviducts of each ovulatory female, and fecal progestin analysis was used to assess pregnancy status. All five females ovulated in response to gonadotropin treatment, averaging  $3.4 \pm 1.36$  corpora lutea for each female, and were inseminated with an average of  $4.97 \pm 1.79 \times 10^6$  motile frozen-thawed sperm. Despite successful ovulation induction, no females became pregnant, likely due in part to sub-optimal pre-freeze sperm traits and a decline in post-thaw seminal quality caused by cryopreservation-based damage. The use of freshly-collected sperm for LO-AI procedures could increase conception rates, but is comprised by many challenges associated with working with free-ranging ocelot populations. These findings suggest that further evaluation of LO-AI, using greater quality sperm samples, is warranted to eventually allow introduction of novel genetics into Texas ocelot populations to support their conservation and recovery.

## **Introduction**

Artificial insemination (AI) is a common technique for assisted reproduction in many domestic species for the production of new breeds, and farm animals using fresh and frozen - thawed semen to propagate these species for human consumption. Additionally, AI can assist individuals that cannot breed naturally due to behavioral, physical or physiological barriers, and

can improve genetic distribution and diversity by transporting frozen genetic materials (semen, embryos, etc.) to geographically distant institutions and countries, and preserve valuable genetics within liquid nitrogen tanks [1]. These techniques have proven successful in domestic cats, whose population numbers in the hundreds of millions globally. Most of their non-domestic relatives, however, are facing declines that could threaten their existence in the wild in the future [1]. Accredited zoos in North America manage many of these non-domestic feline species, with the goal of conserving their genetic diversity [2]. However, limitations on population size and holding space likely inhibit attaining this goal with natural breeding as the sole strategy [3]. Many studies have examined the reproductive physiology of domestic and non-domestic feline species and have explored assisted reproductive technologies that can be applied to endangered felids using the domestic cat as a model. To do so requires understanding the reproductive physiology of each wild cat species, and then, use this knowledge to effectively apply artificial insemination for the propagation of their endangered populations.

One critical factor affecting the success or failure of assisted reproduction is the ovulatory mechanisms typical of each species. Ovulation can be divided into two types: induced and spontaneous. In many induced ovulators, genital somatosensory stimulation during coitus produces a preovulatory release of gonadotropin releasing hormone (GnRH) and a resulting release of luteinizing hormone (LH) from the anterior pituitary induces ovulation [4-10]. In non-domestic felids, studies have investigated the incidence of spontaneous and/or induced ovulation [11] with many cat species showing evidence of spontaneous ovulations in captive settings [11-19]. However, the ocelot (*Leopardus pardalis*) has strictly demonstrated induced ovulation as well as cyclicity year-round [19]. Detection of ovulation via ultrasonography can be challenging [20], presenting challenges for non-invasive confirmation of ovulation to allow artificial insemination procedures to take place. Laparoscopic examination, although invasive, is more definitive, allowing visualization of corpora haemorrhagica (CH) and lutea (CL) to confirm ovulation [21-22]. In wild felids, the basic anatomy is similar to domestic cats, with variations in tract dimensions and only slight changes in morphology [1, 23-24].

For timing of AI procedures, precise synchronization of the estrous cycle and ovulation induction is essential for ensuring the placement of semen into the reproductive tract at the proper time. Oral progestins, such as altrenogest, have been shown to suppress ovarian estrogen production and prevent spontaneous ovulations, with recovery of ovarian activity after

withdrawal of the product in domestic cats [1, 25]. Similar results have been observed in many non-domestic feline species [26-27], including ocelots [28-29]. Treatment with oral progestin and then subsequent withdrawal can allow synchronization for the induction of estrus and ovulation. Treatment with exogenous gonadotropins (i.e., equine chorionic gonadotropin, eCG) is the most common method to induce estrus in cats [1] with eCG being preferred over others due to its persistence in the circulation (4-5 days) reducing the number of necessary injections [1, 30]. Although human chorionic gonadotropin (hCG) is highly effective at inducing ovulation, the development of secondary follicles and corpora lutea (CL) after ovulation can disrupt the hormonal environment causing abnormal implantations and retarded fetal development [31-32]. Another product, porcine luteinizing hormone (pLH) is also effective at inducing ovulation in feline species without these undesirable effects [30, 32, 33-34]. Using this regimen (eCG-pLH), high pregnancy rates (~70%) with normal litter sizes have been produced in domestic cats with AI [31,33, 35-36] and several non-domestic felid species [1].

The first successful AI in domestic cats was reported in the early 1970s using freshly collected semen deposited into the vagina on a natural estrous cycle after the administration of hCG [37] with conception rates reaching 50%. However, this technique required high numbers of sperm (5-10 million) which limited its practical use [1]. Additionally, these basic approaches met other physical obstacles, such as narrow openings, tight transition points, and other anatomical barriers that prevented passage of AI catheters [1, 24, 38-40]. Over time, other methods were developed in domestic cats, such as: laparoscopic uterine artificial insemination (LUAI) with fresh sperm following the treatment combination of eCG-hCG [41], deposition of fresh or frozen-thawed sperm into the uterine horn or oviducts via midline laparotomy following hCG treatment of naturally estrous females [42-44], vaginal AI with frozen-thawed semen [45], and transcervical AI [46-47]. A limiting factor of these methods included the need for relatively high numbers of sperm for LUAI (8-10 million motile sperm per AI) [1, 41], uterine deposition via midline laparotomy (4-10 million sperm per AI) [42-44], vaginal AI (50-100 million motile sperm per female) [1, 45], and transcervical AI (50-100 million motile sperm per female) [46-47]. Although high pregnancy rates were produced with the midline laparotomy (ML) and LUAI (~50%), the need for high sperm numbers and the surgical intervention required for the ML approach limits the applicability to non-domestic feline species [1, 42-44].



The first non-domestic cats were produced via laparoscopic or transcervical uterine AI in the 1980s, resulting in the birth of a puma (*Puma concolor*) [48], leopard (*Panthera onca*) [49], and from vaginal AI, a tiger (*Panthera tigris*) [50]. Additional pregnancies have been produced combining semen collected via urethral catheterization and transcervical AI into naturally estrual females following ovulation induction with a GnRH agonist [51], however, high numbers of quality sperm were required as described in domestic cats [1]. Laparoscopic uterine AI (LU-AI) increased success in cheetahs [52] and ocelots [53] after treatment with combinations of eCG-hCG or eCG-pLH for ovarian stimulation [35], resulting in 3 LU-AI ocelot pregnancies [53]. However, the need for large numbers of sperm continued to be a limitation when using frozen-thawed semen with only 5 pregnancies (3 cheetah, 1 leopard cat, and 1 ocelot) produced with LU-AI [1, 35]. The development of laparoscopic oviductal artificial insemination (LO-AI) in domestic cats [24, 31] presented an approach that could overcome the anatomical and physiological barriers and the need for high sperm numbers [1]. Additionally, this approach can mitigate the lack of post-coital reactions seen in natural breeding that promotes transport via muscular contractions [54], bypassing the need for sperm transport through the reproductive tract (including the cervix and uterotubal junction) [1, 54] to the ampulla, the site of fertilization [55]. This procedure enables the use of small numbers of sperm, allowing for multiple LO-AI procedures to be performed with a single male's ejaculate and decreasing the requirement for high quality spermatozoa to gain access to and fertilize oocytes within the ampulla [1].

For AI, the timing of the procedure relative to ovulation is critical for oocyte maturity and viability at the time of semen deposition [1]. For frozen-thawed sperm, the short life span (6-12 hours) may impair fertility if the AI is performed hours after or before ovulation [1]. Fixed-time LO-AI procedures using oral progestin, followed by an eCG-pLH combination, demonstrated high pregnancy rates (>70%) with low sperm numbers (1 million motile sperm per oviduct) in domestic cats when using frozen-thawed sperm [56] and sperm frozen by ultra-rapid freezing methods [57]. In non-domestic felids, LO-AI has produced 12 pregnancies in 6 species (ocelot, Pallas' cat (*Otocolobus manul*), sand cat (*Felis margarita*), fishing cat (*Prionailurus viverrinus*), tiger, clouded leopard (*Neofelis nebulosa*)). Used in combination with oral progestin suppression, LO-AU has resulted in 5 pregnancies in 4 species (ocelot, sand cat, Pallas' cat, fishing cat), including 3 pregnancies being produced by frozen-thawed semen [24, 28-29, 58-59]. Although the LO-AI technique allows the deposition of sperm into the oviductal lumen, declines in sperm

motility still can compromise oocyte fertilization or storage, making the timing of LO-AI and synchronization of ovulation prior to the procedure more pressing [36]. In ocelots, the fixed-timed LO- AI procedure requires treatment with of oral progestin (0.044 mg/kg PO) once daily for 30 days for ovarian suppression, a 7-day withdrawal period, followed by injections of eCG (400 IU i.m.) and pLH (3000 IU i.m.) given 82 hours apart [25, 28-29, 35, 56] to stimulate follicular growth and ovulation, respectively. LO-AI is then conducted ~38 hours post pLH injection.

In naturally estrual felids that are successfully mated, progesterone concentrations rise in circulation due to the activity of corpora lutea on the ovaries [60], remain elevated during the pregnancy and then begin to decline to baseline just prior to or shortly after parturition [61-62]. Progesterone metabolites (progestin) have been demonstrated in the feces of many cat species and have shown to mimic progesterone profiles in the circulation [63]. In non-domestic felids, fecal progestin concentrations are similar during pregnant and nonpregnant luteal phases, just like in domestic cats [11]. However, non-pregnant luteal phases are characterized by a shorter duration of fecal progestin elevation (approximately 1/3 to 1/2 of the gestation period) than pregnancy [15, 17, 60, 64-65]. For example, in tigers, the non-pregnant-luteal-phase (NPLP) is reported to last ~ 35 days, whereas fecal progestins during pregnancy remain elevated much longer (108 days until parturition) [66]. Therefore, diagnosis of pregnancy can be performed by analyzing fecal progestin levels beyond the duration of the non-luteal phase (~day 40-50 in most cats).

The objective of this research was to assess the efficacy of frozen-thawed sperm from wild Texas ocelots cryopreserved by two methods: traditional straw freezing (STRAW) versus ultra-rapid freezing (URF) in producing viable pregnancies in human-managed ocelots following LO-AI. This information will provide insight into assisted reproductive technologies that can be utilized for the management and conservation of ocelots, not only in human care, but in free-ranging populations in the future.

## **Materials and Methods**

### *Semen Collection and Cryopreservation*

Adult, free-ranging male ocelots (n=4) were captured using modified Tomahawk traps (Tomahawk Live Trap Co., Tomahawk , Wisconsin, USA) on private ranches in Willacy and

Kenedy counties in southern Texas. All animal use was approved by and in accordance with the policies of the Institutional Animal Care and Use Committee at the Texas A and M University–Kingsville (TAMUK), Caesar Kleberg Wildlife Research Institute (CKWRI), the University of Tennessee- Knoxville and the Center for Conservation and Research of Endangered Wildlife (CREW) at the Cincinnati Zoo and the study was permitted by the United States Fish and Wildlife Service (USFWS).

Males were immobilized and maintained at a light anesthetic plane with a combination of ketamine hydrochloride (target dose: 4 to 8 mg/kg bodyweight; Wedgewood Pharmacy: Wildlife Pharmaceuticals, Inc. and ZooPharm, Swedesboro NJ) and medetomidine (target dose: 0.05 mg/kg bodyweight; Wedgewood Pharmacy: Wildlife Pharmaceuticals, Inc. and ZooPharm, Swedesboro NJ) given intramuscularly (i.m.) and followed by partial reversal with atipamezole i.m. (target dose: 5 mg of atipamezole for every 1 mg of medetomidine given; Wedgewood Pharmacy: Wildlife Pharmaceuticals, Inc. and ZooPharm, Swedesboro NJ). Approximately 25-40 minutes post-anesthetic injection, the penis was extruded with manual manipulation and sterile gloves, debris removed with a water-soaked gauze, and semen was collected in 1 of 3 ways: (1) urethral catheterization (UC): a 5 French (1.7 mm) diameter urinary catheter was advanced approximately 15 cm into the urethra, left in place for 30 seconds, and slowly removed; (2) one to three series of electroejaculation (EEJ) (2-5 V; 10 stimulations per series) using a standardized technique [67] with mild modifications [68-69]; or (3) post-mortem by a series of flushing, stripping, and mincing the tissue of the epididymides and vas deferens to remove any remaining sperm. Spermatozoa were then assessed for percent motility, forward progressive motility, acrosomal integrity, concentration, and morphology prior to cryopreservation. Samples were then diluted in their respective cryodiluent for cryopreservation: (1) ultra-rapid freezing (URF), soy-lecithin 0.2 M sucrose and (2) straw freezing, FOCM-Hepes. Briefly, URF samples were cryopreserved using a micro pipettor, pipetting one, ~20 µl drop at a time directly into liquid nitrogen to create pellets for the entirety of the volume and the pellets placed into a labeled cryovial to be stored in liquid nitrogen. Straw samples were centrifuged at 600xg for 8 minutes and the resulting sperm pellets were resuspended in straw-freezing medium (SOY with 4% glycerol) to  $50 \times 10^6$  motile sperm/ml and loaded into 0.25 mL straws (30-100 µl/straw). Straws were heat sealed, transferred into a sealable plastic bag, submerged in room temperature water (100 ml) within a glass container, and cooled to 4°C over a minimum of 2

hours in an electric cooler until a refrigerator was reached. Straws were then frozen using a modified two-step protocol [68, 70] and stored in liquid nitrogen.

#### *Ovarian Synchronization Protocol* [31, 53]

Oral synthetic progestin (altrenogest; Regu-Mate®; 2.2 mg/ml; Merck and Co., Inc., Rahway, NJ) was fed once daily for 30 consecutive days at a set dosage (0.044 mg/kg BW). After 7 days of progestin withdrawal, females were treated with exogenous gonadotropins (400 IU of equine chorionic gonadotropin (eCG); 1200 IU/ml; ProspecBio; East Brunswick, NJ) administered i.m. followed by pLH (3000 IU of porcine luteinizing hormone (pLH); 10000 IU/ml ; Sioux Biochemical; Sioux Center, IA) i.m. 82 hours later. At 39-42 hours after pLH, the laparoscopic oviductal artificial insemination (LO-AI) procedure was performed.

#### *Sperm Thawing and Processing*

Sperm straws were thawed in the air for 10 seconds and then placed into a 38°C water bath for 30 seconds. The contents of each straw were emptied into a 1.5-ml microcentrifuge tube, slowly diluted with FOCM-Hepes medium (100-200 µl), and all straw samples were combined into one Eppendorf tube. An initial post-thaw motility was assessed under light microscopy at 400X. Separate aliquots were spread across a slide for acrosome assessment, and diluted (1:400) in water for a hemocytometer-based count. The remaining sample was centrifugated for 8 minutes at 300xg. The supernatant was removed, and each pellet measured to resuspend to 15-20 µl total volume, as necessary, for insemination. The entire volume of each diluted pellet was placed onto a sterile petri dish and aspirated into a sterile AI needle. Post-AI motility was assessed by flushing the AI needle with FOCM-Hepes medium and examining the sample under light microscopy at 400X magnification. For pellet thawing (URF), each pellet was dropped into a glass test tube with warm FOCM-Hepes (100 µl), mixed gently for 30 seconds, and then all procedures were identical to the straw thawing process.

#### *Laparoscopic Oviductal Artificial Insemination (LO-AI) (Figure 1)* [1, 31, 41, 53, 71]

The female ocelots (n=5) were anesthetized to a surgical plane of anesthesia using a protocol selected by the housing institution. The hair was clipped from the ventral abdomen (from xiphoid to pubis), and the surgical field was aseptically prepared. A Verres needle was placed in the right caudal abdomen approximately 1-inch caudolateral to the umbilicus by tenting

the skin and using manual force to enter the abdomen. A hand pump was used to insufflate the abdominal cavity with un-filtered room air to a uniform tautness. An ~ 1 cm incision was made ~ 2-3 cm cranial to the umbilicus and the surgical table was titled at a 20-30° angle with the head in a ventral position to the abdomen. The skin caudal to the incision was grasped and the trocar-cannula assembly was inserted at a 60° angle to the ventral abdomen with a sharp thrusting motion. The trocar was removed, the laparoscope inserted and attached by a fiberoptic cable to a light source. The laparoscope (10 mm diameter) was used to visualize the ovaries, oviduct, and/or uterus for various procedures, using the Verres needle to manipulate abdominal contents as necessary. Both ovaries were examined for follicles, corpora hemorrhagica, corpora lutea, corpora albicantia, and cysts [Figure 4.1]. The uterine horns were assessed for tone, symmetry and size [Figure 4.1]. The oviducts were examined for distinctness and presence of adequate fimbrial tissue for grasping [Figure 4.1]. The camera was attached to the end of the scope, the Verres needle removed, and the accessory trocar placed in the same location into the abdomen for placement of the grasping forceps. The oviductal tissue picked up using the grasping forceps to roll the bursa laterally and expose the oviduct. An 18-gauge (18 g, 3.2 cm length; Terumo Medical Corporation, Elkton, MD, USA) catheter was placed into the abdomen lateral and caudal to the ovary on the left side. The needle was removed from the catheter and a blunted, artificial insemination needle (22 g, 6.8 cm length), derived from the stylet within an i.v. catheter (20 g, 5.0 cm length; Sherwood Medical Co.), was attached to a 1-ml syringe and placed through the catheter. The AI needle was inserted into the ampulla via the oviductal opening and the sperm was administered as the insemination needle was retracted from the oviduct [Figure 4.1]. The same procedure was completed on the right side. Surgical closure of each skin incision included 1–2 simple interrupted sutures using 3-0 Monocryl and a small amount of tissue adhesive for skin apposition, and the female was allowed to recover. An incisional block or splash block was applied using 1-2 mL of lidocaine or bupivacaine if preferred by the housing institution.

#### *Pregnancy Diagnosis by Fecal Progestins*

Fecal samples were collected three days per week for two months prior to AI and then continued for 85 days after AI. Fecal samples were placed into labeled (name, studbook number, institution name, date) plastic bags and immediately frozen (-20°C) for storage until processing.

Samples were lyophilized via a freeze dryer (Labconoco Corp., Kansas City, MO, USA) in their plastic bags, pulverized into a fine powder, and then weighed ( $250 \pm 5$  mg) into labeled 15 ml polypropylene conical tubes. Each sample was then extracted by adding 2.5 ml of 90% ethanol (or a 1:10 w:v) overnight on a mechanical rocker ( $\geq 12$  h). Extracted samples were then centrifuged (1000g, 15 min, Eppendorf, Enfield, CT, USA), supernatants were removed and samples stored in 2.0 ml cryovials at  $-20$  °C until analysis. Procedures for enzyme immunoassays (EIAs) were modified from those used by Herrick et al. (2010) [69] and Bateman et al. (2009) [72]. Arbor Assays progesterone mini-kit (ISWE003, Arbor Assays, Ann Arbor, MI, USA) was used to determine progestogens (this kit included both antibody and HRP). This assay has been previously used in the CREW endocrine laboratory and validated for use in ocelots. Cross reactivities for antiprogestosterone were progesterone 100%,  $3\beta$ -hydroxy-progesterone 172%,  $3\alpha$ -hydroxy-progesterone 188%,  $11\beta$ -hydroxy-progesterone 2.7%,  $11\alpha$ -hydroxy-progesterone 147%,  $5\alpha$ -dihydroprogesterone 7.0%, pregnenolone 5.9%, corticosterone  $<0.1\%$ , and androstenedione  $<0.1\%$  (Arbor Assays Progesterone Mini-Kit insert #ISWE003). Aliquots of sample were diluted in EIA buffer (45.2 mM  $\text{NaH}_2\text{PO}_4$ , 61.0 mM  $\text{Na}_2\text{HPO}_4$ , 148 mM NaCl, 0.1% BSA, 0.0001% Proclin 150, 863.5 mM Tween 20) ranging from 1:200-1:6400; samples and standards were analyzed in duplicate. The assay was incubated for 2 hours with HRP-conjugate. The plates were then run through a plate washer (AquaMax 2000, Molecular Devices, San Jose, CA, USA) with wash buffer (85.9 mM  $\text{Na}_2\text{HPO}_4 \cdot 7\text{H}_2\text{O}$ , 13.9 mM  $\text{NaH}_2\text{PO}_4 \cdot \text{H}_2\text{O}$ , 150.06 mM NaCl, 12.73 mM EDTA, 0.09% Proclin 150, 1.06% Tween 20). Then 3,3',5,5'-tetramethylbenzidine (TMB, Moss Inc., Pasadena, MD, USA) was added to each well. After ~30 minutes of development, a solution of 3% hydrochloric acid (HCl) was added to each well to stop the reaction. The plate was then evaluated for optical density on a plate reader (VersaMax Absorbance microplate reader, Molecular Devices, San Jose, CA, USA) at 450 nm.

### *Statistical Analyses*

Number of corpora lutea and number of motile sperm ( $\times 10^6$ ) were reported as mean values  $\pm$  SEM. All analyses were performed in SPSS 28 with an  $\alpha = 0.05$ . The enzyme immunoassays (EIAs) were used to assess patterns in progestogens that would indicate whether they were higher than baseline post-AI, remained baseline, or returned to baseline after an average ocelot non-pregnant luteal phase (we used 60 days post-AI). Plates were not held to a

high scrutiny of controls (internal QC, inter and intra-assay CVs, dilution fails, etc.) due to only needing to observe the high or low concentration of samples post-AI.

## Results

From 2019 to 2022, semen was collected and cryopreserved from 4 wild male ocelots for this study. Pre-freeze seminal traits are presented in **Table 4.1**. From 2020 to 2022, five LO-AI procedures have been conducted with generic ocelots ranging in age from three to seven years that were housed in North American zoos. Each female ovulated in response to gonadotropin treatment, averaging  $3.4 \pm 1.36$  corpora lutea/female, and were inseminated with an average of  $4.97 \pm 1.79 \times 10^6$  motile frozen-thawed sperm. Ovulatory response and semen post-thaw parameters are presented in **Table 4.2** and fecal progesterone profiles for each female are presented in **Figure 4.3**. Average luteal phase length was  $38.5 \pm 3.5$  days with a range of 30 to 46 days. Fecal progesterone assessment was not available for female 5. No females became pregnant following LO-AI in this study.

## Discussion

This study represents the first attempt to use frozen semen from wild ocelots for artificial insemination procedures. In non-domestic felids, LO-AI has been successful in six species thus far [24, 28, 59], including four ocelot pregnancies resulting in the birth of four offspring to date [29, 58] with females housed in zoological institutions. Since 1995, a total of nine pregnancies have been produced using uterine AI (n=3) and oviductal AI (n=6) in ocelots using a combination of fresh and/or frozen semen [W. Swanson, personal communication, August 8, 2022; 1, 24, 29, 53, 58]. Of these procedures in ocelots, fresh semen was utilized post electroejaculation of male cats for two inseminations conducted using the fixed-time LO-AI approach described in this study, resulting in two successful pregnancies with two full-term offspring [29]. In other wild felids, the use of frozen-thawed spermatozoa stored in semen straws produced two successful pregnancies in Pallas cats [28] and sand cats [unpublished data].

The primary advantage of the LO-AI approach is the reduction of sperm numbers required for conception (~1 million motile or less for freshly-collected semen and ~2-8 million motile for frozen-thawed semen) [31, 36, unpublished data]. The combination of ovarian suppression with subsequent exogenous gonadotropin administration to stimulate follicular

development and ovulation resulted in similar pregnancy percentages with fresh and frozen-thawed semen in domestic cats [56]. Furthermore, this approach allows the use of sperm of less than optimal quality, as seen commonly with wild felid species [76] and/or associated with cryopreservation damage [1, 36, 77], by permitting sperm deposition at the site or close to the site of fertilization [55].

In previous studies, ocelots have been reported to produce  $\sim 90$  to  $130 \times 10^6$  total sperm per ejaculate which would equate to the completion of  $\sim 45$  oviductal inseminations per ejaculate. Theoretically, this LO-AI approach would substantially increase the distribution of a genetically valuable male's spermatozoa beyond the estimated 10 uterine inseminations that could be performed with the same sample [2, 24, 41-42]. While our previous studies report similar sperm numbers for free-ranging ocelots, the available number of motile, high quality sperm has been limited by sub-optimal seminal quality and the reduced chances of subsequent capture. These obstacles make it imperative to conservatively disperse male genetics and use their sperm samples judiciously to enable their widest potential for reproduction.

The first three procedures performed during this study were likely unsuccessful due to substandard pre-freeze seminal traits as compared to human-managed ocelot populations [73-75], combined with a further decline in seminal quality after thawing. This was our first attempt utilizing urethral catheterization for semen collection combined with ultra-rapid freezing (sperm pelleting) for free-ranging ocelots. Although this method is reported successful with in-vitro fertilization procedures with domestic cats, the combination of UC collection with URF has never been assessed in vivo [57, 73]; accordingly, this was the first attempt to evaluate these methods in vivo for any felid species. The two additional LO-AI procedures were performed with semen collected by electroejaculation and stored via straw cryopreservation technique, with the sperm showing superior motility and forward progression both pre-freeze and post-thaw. While these sperm samples appeared to be of higher quality compared to the catheter collected and URF stored samples, the failure to produce pregnancies was likely related, once again, to lower pre-freeze semen quality, possibly associated with reduced genetic variation in this ocelot population. The average luteal phase was  $\sim 38$  days during this study for 4 female ocelots in which data was available, falling within the estimated luteal phase of ocelots, 1/2 to 1/3 (27 to 55 days) of the typical gestation (79-85 days) [78]. One female (female #3, Fig. 4.2) demonstrated multiple days of progesterone rise after an initial drop at Day 31 post-AI, suggestive of possible



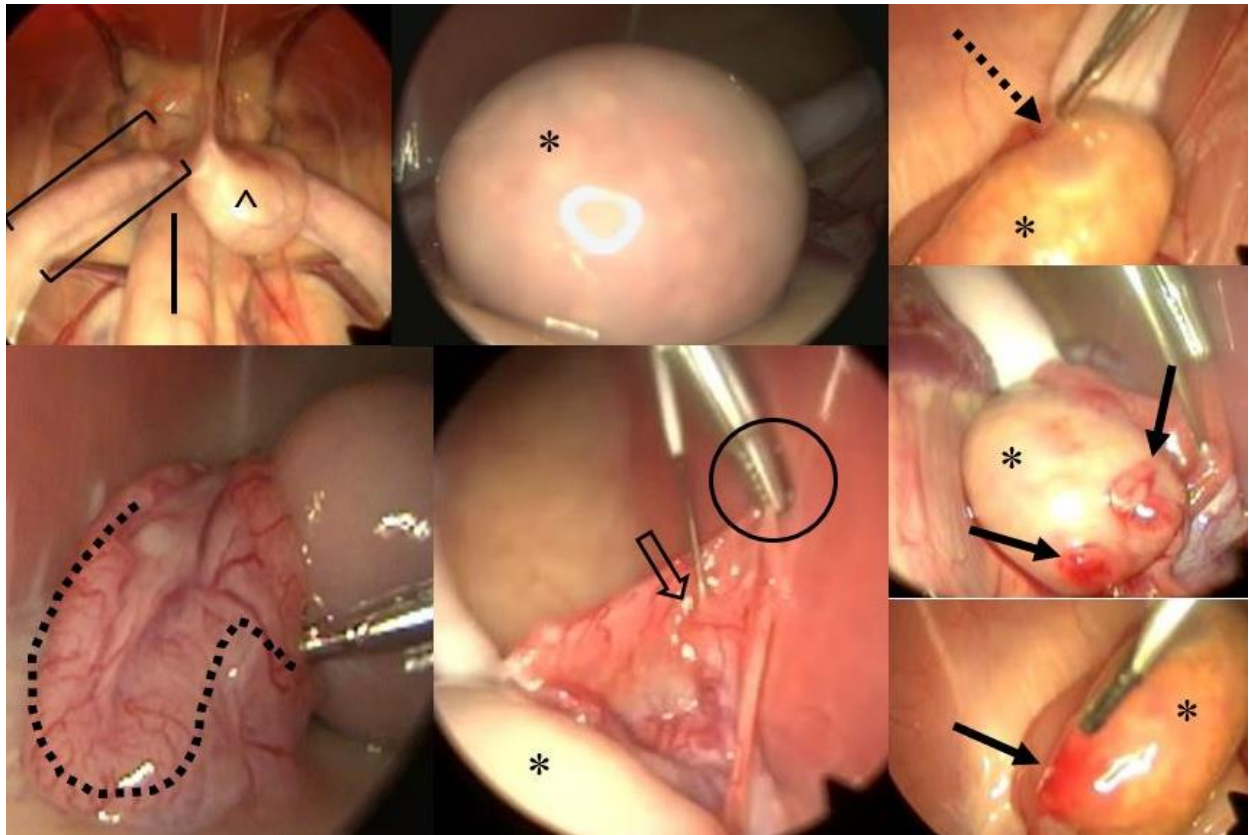
pregnancy. However, progesterone values subsequently fell below baseline around day 55 and no kittens were born.

Prior to LO-AI procedures, our post-thaw evaluation of sperm samples used throughout this study showed some functionality with fertilization of domestic cat oocytes *in vitro*. However, the high concentration of sperm numbers within insemination drops, close proximity of sperm to the oocytes, and the controlled environment in which these IVF procedures are performed, cannot perfectly mimic what is occurring *in vivo*. A combination of less than optimal semen quality and further damage to cryopreserved sperm may require the use of higher sperm numbers when conducting LO-AI procedures with frozen-thawed sperm samples. Conversely, the deposition of a large number of deceased sperm could cause an increase in inflammation within the oviduct [1] or block viable sperm from binding to oocytes, necessitating the removal of dead sperm or the use of less, higher quality sperm for insemination procedures [1]. One option for consideration is the use of swim up processing and removal of glycerol by using an Accudenz gradient, which improved acrosomal integrity and sperm motility post-thaw in cheetahs [79].

Although LO-AI helps to overcome barriers to sperm transport to the oviduct, the timing of AI and the longevity of sperm samples still could hinder success. If AI takes place prior to ovulation, frozen-thawed sperm may not be viable at the time of ovulation; and if AI takes place after ovulation, oocyte quality could decline, decreasing the chances for successful fertilization [1]. While use of non-frozen semen for AI would reduce the risk of pre-ovulatory insemination, collection of fresh semen from free-ranging felids and subsequent AI with human-managed females would be extremely difficult logistically. First and foremost is the need to time AI to a natural estrous cycle or synchronize ovarian activity and induce ovulation for a fixed time procedure. Because the capture of free-ranging males is sporadic and unpredictable, it is highly unlikely that a successful semen collection could be performed in synchrony with the proper reproductive status of a captive female. Finally, the long distances between the geographic locations of free-ranging males and zoo-housed females complicates any transport of freshly collected semen from the field to the AI facility.

Further research is required to improve LO-AI efficacy, including assessing different combinations of collection and cryopreservation (EEJ and STRAW vs URF; UC and STRAW vs URF) to optimize pre- and post-thaw sperm quality. Additionally, investigating the use of LO-AI

in naturally estrus ocelots, induced to ovulate with GnRH agonists, could provide another means to perform these procedures with zoo-housed females. If LO-AI with freshly collected semen proves to be essential, one possible solution may be to temporally house free-ranging males at a regional zoological facility that manages multiple ocelot females that can be synchronized for AIs. If these procedures prove successful, the use of freshly collected semen samples from free-ranging felids would likely increase our success. This use of AI to support endangered species conservation would not be without precedent. AI has already proved to be a valuable tool for genetic management in another U.S. endangered species, the black-footed ferret (*Mustela nigripes*) [41]. Within this species, application of assisted reproductive techniques has helped to address challenges arising with the scarcity of founders available for recovery [80]. Similarly, ocelot populations are being challenged by human-induced population declines that are compromising genetic sustainability. The incorporation of assisted reproductive technologies, such as LO-AI, if consistently successful, could substantially benefit ocelot conservation and recovery in the US.



**Figure 4.1: Laparoscopic oviductal artificial insemination procedure.** Reproductive tract examination, confirmation of ovulation, and artificial insemination into the oviduct of human-managed ocelots. \*= ovary; ^= bladder; black arrow= corpora lutea; brackets= uterine horn; straight black line= colon; dotted line= oviduct; dashed arrow= ovarian follicle; open arrow= oviductal opening and entrance of AI needle (silver needle); black open circle= grasping the fimbriae of the ovary and opening the oviduct

**Table 4.1: Pre-freeze and post-thaw seminal traits of Texas ocelots.** Pre-freeze (post-thaw) seminal parameters for Texas ocelots included in this study.

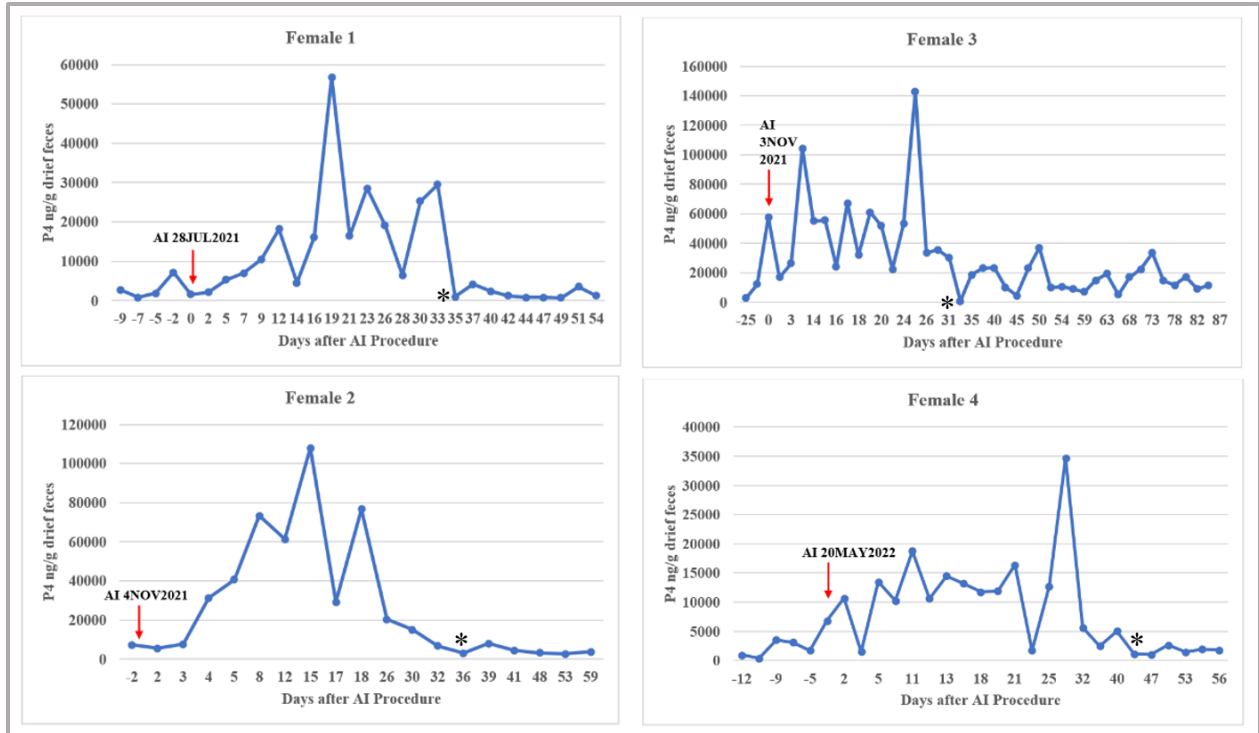
ID	MOT	FPM	ACRO	MORPH	IVF STRAW	IVF URF
(A)E19M	70 (20*/20**)	4.0 (3.0/2.5)	72 (36*/18**)	59.75	61.5	29.4
(B)OM341	- (10)	- (2.0)	- (45)	-	-	57.1
(C)OM283	60 (40)	3.0 (3.0)	78 (41)	25.5	-	-
(D)E22M	80 (40)	3.0 (3.0)	61 (32)	27	31.25	-

MOT= percent motility; FPM= forward progressive motility; ACRO= percentage of intact acrosomes; MORPH= percent normal morphology; IVF URF= in-vitro fertilization percentage out of mature oocytes for ultra-rapid freezing method; IVF STRAW= in-vitro fertilization percentage out of mature oocytes for straw freezing method; \*URF post-thaw parameters; \*\*STRAW post-thaw parameters

**Table 4.2: Laparoscopic oviductal artificial insemination (LO-AI) procedures and outcomes.** Response to ovarian synchronization protocol, post-thaw semen parameters, and pregnancy status for zoo managed ocelot females.

Female ID	Corpora Lutea (LO/RO)	Follicles (LO/RO)	Motile frozen-thawed sperm (x10 <sup>6</sup> ) LOv	Motile frozen-thawed sperm (x10 <sup>6</sup> ) ROv	Post-thaw MOT (%) / FPM (0-5) LOv	Post-thaw MOT (%) / FPM (0-5) ROv	Pregnancy?/ Gestation
1	4/4	2/0	5.2 (PM/STRAW/C)	5.2 (PM/STRAW/C)	40/3.0	40/3.0	NO/-
2	1/4	1/2	2.58 (UC/URF/B)	4.94 (UC/URF/A)	10/2.0	20/3.0	NO/-
3	1/0	1/1	1.75 (UC/STRAW/A)	-	20/2.5	-	NO/-
4	0/1	0/0	-	4.42 (EEJ/STRAW/D)	-	40/3.5	NO/-
5	0/2	0/0	-	0.78 (EEJ/STRAW/D)	-	35/3.0	NO/-

LO= left ovary; RO= right ovary; LOv- left oviduct; ROv= right oviduct; MOT= percentage of progressive motility; FPM= forward progressive motion; sperm collection techniques: PM= post-mortem, UC= urethral catheterization, EEJ= electroejaculation; cryopreservation techniques: URF= ultra-rapid freezing, STRAW= straw freezing. Male ID letter is reported in parentheses after cryopreservation technique.



**Figure 4.2: Fecal progesterone profiles of female ocelots.** Female number corresponds with the number in Table 2. AI, date of laparoscopic oviductal artificial insemination; \*, progesterone falls below baseline.

## References

- [1] W.F. Swanson. Practical application of laparoscopic oviductal artificial insemination for the propagation of domestic cats and wild felids. *Reprod Fertil Dev.* 31 (2019) 27-39.  
<https://doi.org/10.1071/rd18350>
- [2] W.F. Swanson, M.A. Stoops, G.M. Magarey, J. Herrick. Sperm cryopreservation in endangered felids: developing linkage of *in situ-ex situ* populations. In ‘Spermatology’. (Eds E. Roldan and L. Gomenido). Nottingham University Press: Nottingham. (2007) 417-432. PMID: 17644981
- [3] W.F. Swanson. Application of assisted reproduction for population management in felids: the potential and reality for conservation of small cats. *Therio.* 66 (2006) 49-58.  
<https://doi.org/10.1016/j.theriogenology.2006.03.024>
- [4] D.H. Banks, H. Stabenfeldt. Luteinizing hormone release in the cat in response to coitus on consecutive days of estrus. *Biol Reprod.* 26 (1982) 603-11.  
<https://doi.org/10.1095/biolreprod26.4.603>
- [5] V.M. Shille, C. Munro, S.W. Farmer, H. Papkoff. Ovarian and endocrine responses in the cat after coitus. *J Reprod Fertil.* 69 (1983) 29-39. <https://doi.org/10.1530/jrf.0.0690029>
- [6] J. Bakker, M.J. Baum. Neuroendocrine regulation of GnRH release in induced ovulators. *Frontiers in Neuroendocrinology.* 21 (2000) 220-262. <https://doi.org/10.1006/frne.2000.0198>
- [7] P. Concannon, B. Hodgson, D. Lein. Reflex LH release in estrous cats following single and multiple copulations. *Biol Reprod.* 23 (1980) 111–117.  
<https://doi.org/10.1095/biolreprod23.1.111>
- [8] L.M. Johnson, V.L. Gay. Luteinizing hormone in the cat. II. Mating-induced secretion. *Endocrinol* 109 (1981) 247–252. <https://doi.org/10.1210/endo-109-1-247>
- [9] D.E. Wildt, S.W.J. Seager, P.K. Chakraborty. Effect of copulatory stimuli on incidence of ovulation and on serum luteinizing hormone in the cat. *Endocrinol.* 107 (1980) 1212–1217.  
<https://doi.org/10.1210/endo-107-4-1212>

- [10] D.E. Wildt, S.Y.W. Chan, S.W.J. Seager, P.K. Chakraborty. Ovarian activity, circulating hormones, and sexual behavior in the cat. I. Relationships during the coitus-induced luteal phase and the estrous period without mating. *Biol Reprod.* 25 (1981) 15–28.  
<https://doi.org/10.1095/biolreprod25.1.15>
- [11] J.L. Brown. Comparative endocrinology of domestic and nondomestic felids. *Therio.* 66 (2006) 25-36. <https://doi.org/10.1016/j.theriogenology.2006.03.011>
- [12] R. Dee Schramm, M.B. Briggs, J.J. Reeves. Spontaneous and induced ovulation in the lion (*Panthera leo*). *Zoo Biol.* 13 (1994) 301-7. <https://doi.org/10.1002/zoo.1430130403>
- [13] C.E. Pope, M.C. Gomez, B.L. Dresser. *In vitro* production and transfer of cat embryos in the 21<sup>st</sup> century. *Therio.* 66 (2006) 59-71. <https://doi.org/10.1016/j.theriogenology.2006.03.014>
- [14] A.M. Schmidt, L.A. Nadal, M.J. Schmidt, N.B. Beamer. Serum concentrations of oestradiol and progesterone during the normal oestrous cycle and early pregnancy in the lion (*Panthera leo*). *J Reprod Fertil.* 57 (1979) 267-72. <https://doi.org/10.1530/jrf.0.0570267>
- [15] J.L. Brown, D.E. Wildt, L.H. Graham, A.P. Byers, S. Barrett, J.G. Howard. Comparison of natural versus chorionic gonadotropin-induced ovarian responses in the clouded leopard (*Neofelis nebulosa*) assessed by fecal steroids. *Biol Reprod.* 53 (1995) 93-102.  
<https://doi.org/10.1095/biolreprod53.1.93>
- [16] A.M. Schmidt, D.L. Hess, M.J. Schmidt, R.C. Smith, C.R. Lewis. Serum concentrations of oestradiol and progesterone, and sexual behavior during the normal oestrous cycle in the leopard (*Panthera pardus*). *J Reprod Fertil.* 82 (1988) 43–9. <https://doi.org/10.1530/jrf.0.0820043>
- [17] J.L. Brown, L.H. Graham, J. Wu, D. Collins, W.F. Swanson. Reproductive endocrine responses to photoperiod and exogenous gonadotropins in the Pallas' cat (*Otocolobus manul*). *Zoo Biol.* 21 (2002) 347-64. <https://www.jstor.org/stable/20096605>
- [18] R.B. Moreland, J.L. Brown, D.E. Wildt, J.G. Howard. Basic reproductive biology of the fishing cat (*Prionailurus viverrinus*). *Biol Reprod.* 66:1 (2002) 328 [abstract].
- [19] N. Moreira, E.L.A. Monteiro-Filho, W. Moraes, W.F. Swanson, L.H. Graham, O.L. Pasquali, M.L.F. Gomes, R.N. Morais, D.E. Wildt, J.L. Brown. Reproductive steroid hormones

and ovarian activity in felids of the *Leopardus* genus. *Zoo Biol.* 20 (2001) 103-16.

<https://doi.org/10.1002/zoo.1010>

[20] E. Malandain, D. Rault, E. Froment, S. Baudon, L. Desquilbet, D. Begon, S. Chastant-Maillard. Follicular growth monitoring in the female cat during estrus. *Therio.* 76 (2011) 1337-1346. <https://doi.org/10.1016/j.theriogenology.2011.06.002>

[21] D.E. Wildt, G.M. Kinney, S.W.J. Seager. Laparoscopy for direct observation of internal organs in the domestic cat and dog. *Am J Vet Res.* 38 (1977) 1429-1432. ISSN : 0002-9645

[22] D.E. Wildt, S.W.J. Seager. Laparoscopic determination of ovarian and uterine morphology during the reproductive cycle. In 'Current Therapy in Theriogenology' (Ed. DA Morrow). WB Saunders: Philadelphia. (1980) 828-832.

[23] R. Nickel, A. Schummer, W.O. Sack. Female genital organs of the carnivores. In 'The Viscera of the Domestic Mammals'. (2<sup>nd</sup> edition) Springer-Verlag: New York. (1979) 369-372.

[24] W.F. Swanson. Laparoscopic oviductal embryo transfer and artificial insemination in felids: challenges, strategies and successes. *Reprod Domest Anim.* 47 (2012) 136-140. <https://doi.org/10.1111/rda.12069>

[25] R.A. Stewart, K.M. Pelican, A.E. Crosier, B.A. Pukazhenth, D.E. Wildt, M.A. Ottinger, J.G. Howard. Oral progestin priming increases ovarian sensitivity to gonadotropin stimulation and improves luteal function in the cat. *Biol Reprod.* 87 (2010) 137. <https://dx.doi.org/10.1095%2Fbiolreprod.112.104190>

[26] K. Pelican, D.E. Wildt, J.G. Howard. Ovarian stimulation for assisted reproduction and reproductive control in domestic and nondomestic felids. *Therio.* 66 (2006) 37-48. <https://doi.org/10.1016/j.theriogenology.2006.03.013>

[27] A.E. Crosier, P. Comizzoli, D.C. Koester, D.E. Wildt. Circumventing the natural, frequent oestrogen waves of the female cheetah (*Acinonyx jubatus*) using oral progestin (Altrenogest). *Reprod Fertil Dev.* 29 (2016) 1486-1498. <https://doi.org/10.1071/rd16007>

[28] W.F. Swanson, H.L. Bateman, J.R. Herrick, L.A. Lyons, L.M. Vansandt. Fixed time laparoscopic oviductal artificial insemination (LO-AI) with frozen thawed semen in Pallas' cats (*Otocolobus manual*). *Reprod Fertil Dev.* 28 (2016) 190-191. [Abstract].



- [29] W.F. Swanson, L.M. Vansandt, J. Kinzer, K. Kaemmerer, M. Campbell, E. Donelan, A. Miller, H. Bateman, A. Moresco. Ovarian suppression with oral progestin facilitates successful fixed time laparoscopic oviductal artificial insemination in the fishing cat (*Prionailurus vivverinus*) and ocelot (*Leopardus pardalis*). *Proc Ann Meet Soc Study Reprod.* (2017) 237. [Abstract].
- [30] W.F. Swanson, B.A. Wolf, J.L. Brown, T. Martin-Jiminez, J.E. Riviere, T.L. Roth, D.E. Wildt DE. Pharmacokinetics and ovarian stimulatory effects of equine and human chorionic gonadotropins administered singly and in combinations in the domestic cat. *Biol of Reprod.* 57 (1997) 295-302. <https://doi.org/10.1095/biolreprod57.2.295>
- [31] V.A. Conforti, H.L. Bateman, M.M. Schook, J. Newsom, L.A. Lyons, R.A. Grahn, J.A. Deddens, W.F. Swanson. Laparoscopic oviductal artificial insemination improves pregnancy success in exogenous gonadotropin-treated domestic cats as a model for endangered felids. *Biol Reprod.* 89 (2013) 1-9. <https://doi.org/10.1095/biolreprod.112.105353>
- [32] L.H. Graham, W.F. Swanson, G.F. Birchard, J.L. Brown. Chorionic gonadotropin administration in domestic cats causes an abnormal endocrine environment which disrupts oviductal embryo transport. *Therio.* 54 (2000) 1117-31. [https://doi.org/10.1016/s0093-691x\(00\)00420-9](https://doi.org/10.1016/s0093-691x(00)00420-9)
- [33] V.A. Conforti, H.L. Bateman, M.M. Vick, L.A. Lyons, R.A. Grahn, J.W. Deddens, W.F. Swanson. Improved fertilization success using laparoscopic oviductal artificial insemination with low sperm numbers in domestic cats. *Proc Soc Study reprod*, 40 (2011) abstract no. 173.
- [34] G.M. Magarey, J.B. Bond, J.R. Herrick, M.A. Stoops, W.F. Swanson. Improved recipient synchronization protocol for embryo transfer in the domestic cat (*Felis silvestris catus*) using equine chorionic gonadotropin (eCG) and porcine luteinizing hormone (pLH). *Proc 38<sup>th</sup> Soc Study Reprod.* 91 (2005) Abstract no. 48.
- [35] J.G. Howard, D.E. Wildt. Approaches and efficacy of artificial insemination in felids and mustelids. *Therio.* 71 (2009) 130-148. <https://doi.org/10.1016/j.theriogenology.2008.09.046>
- [36] C.A. Lambo, R.Z. Grahn, L.A. Lyons, H.L. Bateman, J. Newsom, W.F. Swanson. Comparative fertility of freshly collected vs frozen-thawed semen with laparoscopic oviductal

artificial insemination in domestic cats. *Reprod Domest Anim.* 47 (2012) 284-288.

<https://doi.org/10.1111/rda.12038>

[37] N.J. Sojka, L.L. Jennings, C.E. Hamner. Artificial insemination in the cat (*Felis catus L.*). *Lab Anim Care.* 20 (1970) 198-204. PMID: 4246013

[38] M.H. Pineda, R.A. Kainer, L.C. Faulkner. Dorsal median post cervical fold in the canine vagina. *Am J Vet Res.* 34 (1973) 1487-1491. PMID: 4762716

[39] M.A. Wilson MA. Transcervical insemination techniques in the bitch. *Vet Clin North Am Small Anim Pract.* 31 (2001) 291-304. [https://doi.org/10.1016/s0195-5616\(01\)50206-5](https://doi.org/10.1016/s0195-5616(01)50206-5)

[40] W.F. Swanson, R.A. Godke. Transcervical embryo transfer in the domestic cat. *Lab Anim Sci.* 44 (1994) 288-291. PMID: 7933980

[41] J.G. Howard, M.A. Barone, A.M. Donoghue, D.E. Wildt. The effect of preovulatory anaesthesia on ovulation in laparoscopically-inseminated domestic cats. *J Reprod Fertil.* 96 (1992) 175-186. <https://doi.org/10.1530/jrf.0.0960175>

[42] T. Tsutsui, A. Tanaka, Y. Takagi, K. Nakagawa, Y. Fujimoto, M. Murai, M. Anzai, T. Hori. Unilateral intrauterine horn insemination of fresh semen in cats. *J Vet Med Sci.* 62 (2000) 1241-1245. <https://doi.org/10.1292/jvms.62.1241>

[43] T. Tsutsui, A. Tanaka, T. Hori. Intratubal insemination with fresh semen in cats. *J Reprod Feril Suppl.* 57 (2001) 347-351. PMID: 11787173

[44] M. Toyonaga, Y. Sato, A. Sasaki, A. Kaihara, T. Tsutsui. Artificial insemination with cryopreserved sperm from feline epididymides stored at 4°C. *Therio.* 76 (2011) 532-537. <https://doi.org/10.1016/j.theriogenology.2011.03.005>

[45] C.C. Platz, D.E. Wildt, S.W.J. Seager. Pregnancy in the domestic cat after artificial insemination with previously frozen spermatozoa. *J Reprod Fertil.* 52 (1978) 279-282. <https://doi.org/10.1530/jrf.0.0520279>

[46] D. Zambelli, M. Cunto. Transcervical artificial insemination in the cat. *Therio.* 64 (2005) 698-705. <https://doi.org/10.1016/j.theriogenology.2005.05.020>

- [47] K. Chatdarong, E. Axner, S. Manee-In, P. Thuwanut, C. Linde-Forsberg. Pregnancy in the domestic cat after vaginal or transcervical insemination with fresh and frozen semen. *Therio*. 68 (2007) 1326-1333. <https://doi.org/10.1016/j.theriogenology.2007.07.022>
- [48] H.D.M. Moore, R.C. Bonney, D.M. Jones. Successful induced ovulation and artificial insemination in the puma (*Felis concolor*). *Vet Rec*. 108 (1981) 282-283. <https://doi.org/10.1136/vr.108.13.282>
- [49] B. Dresser, L. Kramer, B. Reece, P.T. Russell. Induction of ovulation and successful artificial insemination in a Persian leopard (*Panthera pardus saxicolor*). *Zoo Biol*. 1 (1982) 55-57. <https://doi.org/10.1002/zoo.1430010106>
- [50] J.N. Chagas e Silva, R.M. Leitão, N.E. Lapão, T.P. da Cunha, J.P. da Silva, F.C. Paisana. Birth of a Siberian tiger (*Panthera tigris altaica*) cubs after transvaginal artificial insemination. *J Zoo Wildl Med*. 31 (2000) 566-569. [https://doi.org/10.1638/1042-7260\(2000\)031\[0566:bostpt\]2.0.co;2](https://doi.org/10.1638/1042-7260(2000)031[0566:bostpt]2.0.co;2)
- [51] A. Lueders, C. Ludwig, M. Schroeder, K. Mueller, J. Zahmel, M. Dehnhard. Successful nonsurgical artificial insemination and hormonal monitoring in an Asiatic golden cat (*Catopuma temmincki*). *J Zoo Wildl Med*. 45 (2014) 372-379. <https://doi.org/10.1638/2013-0269r.1>
- [52] J.G. Howard, T.L. Roth, A.P. Byers, W.F. Swanson, D.E. Wildt. Sensitivity to exogenous gonadotropins for ovulation induction and laparoscopic artificial insemination in the cheetah and clouded leopard. *Biol Reprod*. 56 (1997) 1059-1068. <https://doi.org/10.1095/biolreprod56.4.1059>
- [53] W.F. Swanson, J.G. Howard, T.L. Roth, J.L. Brown, T. Alvarado, M. Burton, D. Starnes, D.E. Wildt. Responsiveness of ovaries to exogenous gonadotropins and laparoscopic artificial insemination with frozen-thawed spermatozoa in ocelots (*Felis pardalis*). *J Reprod Fertil*. 106 (1996) 87-94. <https://doi.org/10.1530/jrf.0.1060087>
- [54] K. Chatdarong, C. Lohachit, C. Linde-Forsberg. Distribution of spermatozoa in the female reproductive tract of the domestic cat in relation to ovulation induced by natural mating. *Therio*. 62 (2004) 1027-1041. <https://doi.org/10.1016/j.theriogenology.2003.12.014>
- [55] P. Coy, F.A. Garcia-Vazquez, P.E. Visconti, M. Aviles. Roles of the oviduct in mammalian fertilization. *Reprod*. 144 (2012) 649-660. <https://dx.doi.org/10.1530%2FREP-12-0279>

- [56] W.F. Swanson, J. Newsom, L.A. Lyons, R.A. Grahn, H.L. Bateman. Ovarian down-regulation with oral progesterone for fixed-time laparoscopic oviductal insemination with freshly-collected and frozen-thawed semen in domestic cats. *Reprod Fertil Dev.* 26 (2014) 143.
- [57] J.D. Johnson, H.L. Bateman, J. Newsom, L.M. Vansandt, W.F. Swanson. Semen vitrification in felids- a simplified cryopreservation method for field use. In 'Proceeding of the Annual Conference American Association of Zoo Veterinarians.' American Association of Zoo Veterinarians: Portland, OR, USA. (2015) 124-125.
- [58] C.A. Lambo, H.L. Bateman, W.F. Swanson. Application of laparoscopic oviductal artificial insemination for conservation management of Brazilian ocelots and Amur tigers. *Reprod Fertil Dev.* 26 (2014) 116 [Abstract].
- [59] W. Tipkantha, P. Thuwanut, U. Maikeaw, A. Thongphakdee, S. Yapila, S. Kamolnorrath, B. Siriaronrat, P. Comizolli, K. Chatdarong. Successful laparoscopic oviductal artificial insemination in the clouded leopard (*Neofelis nebulosa*). *J Zoo Wildl Med.* 48 (2017) 804-812. <https://doi.org/10.1638/2016-0287.1>
- [60] B.C. Braun, A. Frank, M. Dehnhard, C.C. Voigt, A. Vargas, F. Goritz, K. Jewkenow. Pregnancy diagnosis in urine of Iberian lynx (*Lynx pardinus*). *Therio.* 71 (2009) 754-761. <https://doi.org/10.1016/j.theriogenology.2008.09.054>
- [61] P.M. Schmidt, P.K. Chakraborty, D.E. Wildt. Ovarian activity, circulating hormones and sexual behavior in the cat. II. Relationships during pregnancy, parturition, lactation and the postpartum estrus. *Biol Reprod.* 28:3 (1983) 657–71. <https://doi.org/10.1095/biolreprod28.3.657>
- [62] P.W. Concannon, D.H. Lein. Feline reproduction. In: Kirk RW, editor. Current veterinary therapy VII. Philadelphia/London/ Toronto: W.B. Saunders. (1983) 932–5.
- [63] J.L. Brown, S.K. Wasser, D.E. Wildt, L.H. Graham. Comparative aspects of steroid hormone metabolism and ovarian activity in felids, measured noninvasively in feces. *Biol Reprod.* 51:4 (1994) 776–86. <https://doi.org/10.1095/biolreprod51.4.776>
- [64] J.L. Brown, D.E. Wildt, N. Wielebnowski, K.L. Goodrowe, L.H. Graham, S. Wells, J.G. Howard. Reproductive activity in captive female cheetahs (*Acinonyx jubatus*) assessed by faecal steroids. *J Reprod Fertil.* 106 (1996) 337-46. <https://doi.org/10.1530/jrf.0.1060337>

[65] A.M. Schmidt, D.L. Hess, M.J. Schmidt, C.R. Lewis. Serum concentrations of oestradiol and progesterone and frequency of sexual behaviour during the normal oestrous cycle in the snow leopard (*Panthera uncia*). *J Reprod Fertil.* 98 (1993) 91-5.

<https://doi.org/10.1530/jrf.0.0980091>

[66] L.H. Graham, A.P. Byers, D.L. Armstrong, N.M. Loskutoff, W.F. Swanson, D.E. Wildt, J.L. Brown. Natural and gonadotropin-induced ovarian activity in tigers (*Panthera tigris*) assessed by fecal steroid analyses. *Gen Comp Endocrinol.* 147:3 (2006) 362-70.

<https://doi.org/10.1016/j.ygcen.2006.02.008>

[67] J.G. Howard, D.E. Wildt. Semen Collection, Analysis and Cryopreservation in Nondomestic Mammals, In: Morrow DA, editor. Current therapy in theriogenology : diagnosis, treatment, and prevention of reproductive diseases in small and large animals, Saunders; 2nd edition. (1986) 1047-1053.

[68] K. Thiangtum, W.F. Swanson, J.G. Howard, W. Tunwattana, D. Tongthainan, W. Wichasilpa, P. Patumrattanathan, T. Pinyopoommintr. Assessment of basic seminal characteristics, sperm cryopreservation and heterologous in vitro fertilisation in the fishing cat (*Prionailurus viverrinus*). *Reprod Fertil Dev.* 18:3 (2006) 373-82.

<https://doi.org/10.1071/rd05098>

[69] J.R. Herrick, J.B. Bond, M. Campbell, G. Levens, T. Moore, K. Benson, J. D'Agostino, G. West, D.M. Okeson, R. Coke, S.C. Portacio, K. Leiske, C. Kreider, P.J. Polumbo, W.F. Swanson. Fecal endocrine profiles and ejaculate traits in black-footed cats (*Felis nigripes*) and sand cats (*Felis margarita*). *Gen and Compar Endocrinol.* 165 (2010) 204-214.

<https://doi.org/10.1016/j.ygcen.2009.06.021>

[70] A.E. Crosier, B.S. Pukazhenthii, J.N. Henghali, J. Howard, A.J. Dickman, L. Marker, D.E. Wildt. Cryopreservation of spermatozoa from wild-born Namibian cheetahs (*Acinonyx jubatus*) and influence of glycerol on cryosurvival. *Cryobiol.* 52 (2006)169-181.

<https://doi.org/10.1016/j.cryobiol.2005.10.011>

[71] C. Lambo, V. Conforti, D. Goff, Z. Gyimesi, M. Campbell, A. Lewandowski, M.J. Limoges, H. Bateman, W. Swanson. Improving pregnancy success with laparoscopic artificial

insemination in Brazilian ocelots (*Leopardus pardalis mitis*). *Proc Amer Assoc Zoo Vet.* (2011) 76-78.

[72] H.L. Bateman, J. Bond, M. Campbell, M. Barrie, G. Riggs, B. Snyder, W. Swanson. Characterization of basal seminal traits and reproductive endocrine profiles in North American river otters and Asian small-clawed otters. *Zoo Biol.* 28 (2009) 107-126.

<https://doi.org/10.1002/zoo.20206>

[73] W.F. Swanson, L.M. Vansandt, S. Citino, R.S. Larsen, G.A. Cole, A. Moresco. Addressing the challenge of do-it-ourself (DIY) semen banking in wild felids, *Proc Ann Meet Amer Assoc Zoo Vet.* (2017) 81-82.

[74] M.A. Stoops, L.B. Bond, H.L. Bateman, M.K. Campbell, G.P. Levens, T.R. Bowsher, S.T. Ferrell, W.F. Swanson. Comparison of different sperm cryopreservation procedures on post-thaw quality and heterologous in vitro fertilization success in the ocelot (*Leopardus pardalis*). *Reprod Fert Dev.* 19 (2007) 685-694. <https://doi.org/10.1071/rd06078>

[75] W.F. Swanson, H.L. Bateman, L.M. Vansandt. Urethral catheterization and sperm vitrification for simplified semen banking in felids. *Reprod Domest Anim.* 52:2 (2016) 255-260.

<https://doi.org/10.1111/rda.12863>

[76] B.S. Pukazhenth, K. Neubauer, K. Jewgenow, J.G. Howard, D.E. Wildt. The impact and potential etiology of teratospermia in the domestic cat and its wild relatives. *Therio.* 66 (2006) 112-121. <https://doi.org/10.1016/j.theriogenology.2006.03.020>

[77] P.F. Watson. The causes of reduced fertility with cryopreserved semen. *Anim Reprod Sci.* 60-61 (2000) 481-492. [https://doi.org/10.1016/s0378-4320\(00\)00099-3](https://doi.org/10.1016/s0378-4320(00)00099-3)

[78] E. Mondolfi. Notes on the biology and status of the small wild cats in Venezuela. In: Miller SD, Everett DD (Eds.). *Cats of the world: biology, conservation and management.* Washington, D.C.: National Wildlife Federation. (1986) 85-124.

[79] A.E. Crosier, J.N. Henghali, J.G. Howard, B.S. Pukazhenth, K.A. Terrell, L.L Marker, D.E. Wildt. Improved quality of cryopreserved cheetah (*Acinonyx jubatus*) spermatozoa after centrifugation through Accudenz. *J Androl.* 30 (2009) 298-308.

<https://doi.org/10.2164/jandrol.108.006239>

[80] R.M. Santymire, E.V. Lonsdorf, S.M. Lynch, D.E. Wildt, P.E. Marinari, J.S. Kreeger, J.G. Howard. Inbreeding causes decreased seminal quality affecting pregnancy and litter size in the endangered black-footed ferret. *Anim Conserv.* © 2018 The Zoological Society of London. 22 (2019) 331-340. <https://doi.org/10.1111/acv.12466>

## Conclusion

The reduction in genetic variation among wild felids and more specifically ocelot and bobcat populations in southern Texas [1-5], has the potential to decrease immune and reproductive fitness affecting fertility, offspring survival, and susceptibility to various pathogens [6-10]. Although genetic decline has been documented, the impact of this decreased genetic variability on the general and reproductive health of these populations had not been examined to date. The goals of this research were to assess the general health, pathogen prevalence and/or exposure to pathogens, and reproductive health of these populations and further examine the use of assisted reproductive technologies, such as semen collection, cryopreservation and artificial insemination, to mitigate genetic decline in imperiled populations.

We reported hematologic and biochemical values for free-ranging ocelot and bobcat populations in southern Texas. Although there were some similarities to reported values from other populations of these species, some reported values were unique to this population. Additionally, no differences were observed between the sexes for either species as it pertains to reference intervals. Manual differential assessments of blood smears were completed and platelet numbers reported from hematology analyzers are different than what was observed during visual assessment of blood smears. Multiple pathogens or evidence of exposure to pathogens were prevalent in these populations with the most common among those being FIV, *Toxoplasma gondii*, and *Hepatozoon* spp. Males were more likely to test positive or test positive for exposure to most pathogens assessed in this study and this may be attributed to a difference in male behavior, such as territorial disputes, grooming habits, and group gathering, between the sexes.

Both species carried many intestinal parasites with the most common being roundworms, hookworms, and protozoa. While present in abundance in these populations, emaciation and was not noted for any individuals suggesting coexistence with these pathogens was not causing obvious physical decline. The most common ectoparasites identified were *Dermacentor variabilis* (the American dog tick) and *Pulex* spp. (fleas). Overall, bobcats had a higher presence of ectoparasites and males had a mild increase in parasite load for both species. This may be attributed to the longer hair coat of bobcats causing a physical barrier to effective ectoparasite removal, and a lack of cross-grooming behavior for males that is sometimes observed in females. While many ectoparasites and their associated vector-borne pathogens were identified within our



populations, clinical disease was not observed for any individuals suggesting an early disease process or the ability of these populations to thrive with chronic pathogen exposure and presence over time.

Over time (from 1985-present), most pathogens were detected throughout this time period without consistent increasing or decreasing trends; however, two pathogens (*Leishmania* spp. and *Ehrlichia* spp.) were only detected in recent years and were not found in any of the archived samples prior to 2019. This could suggest a recent increased exposure, increased susceptibility to *Leishmania* spp. in ocelots and *Ehrlichia* spp. in bobcats, a change in disease dynamics or vector, and/or or a lack of power as a result of a fewer animals tested in earlier years. While there were differences in blood values associated with the presence of pathogens or exposure to pathogens, none of those values fell outside of our reported blood values for this population. Additionally, physical examinations did not reveal any abnormalities suggesting subclinical infections or that individuals were fully recovered from any prior illness.

The next goal of this research was to describe the reproductive health and normative seminal traits of ocelots and bobcats in southern Texas. Urethral catheterization (UC) was effective for sperm collection and characterization of baseline seminal traits in free-ranging ocelots and bobcats with both species exhibiting teratospermia, suggested to be associated with declining genetic diversity in other species [11-14]. Additionally, ocelot populations in this region of Texas had lower seminal quality as compared to more genetically robust populations managed within North American zoos suggesting reproductive health may be reduced in this closely related population. Bobcats had superior semen quality in the spring months of our study season (March and April) as compared to winter months, similar to other species within the same genus [15], but showed low sperm numbers overall and the presence of genital abnormalities frequently seen as a result of inbreeding events [16-22]. Urine contamination was the most common challenge faced when using the UC technique, rendering our urine contaminated samples non-viable for further assessment of assisted reproductive technologies. There was not a dosage effect of medetomidine in this study for sperm release; however, use of greater dosages or conversion to dexmedetomidine in these species would yield sperm of higher quality and quantity using the UC technique. For ocelots, electroejaculation (EEJ) allowed for additional recovery of spermic samples of higher quality as compared to the UC collected samples, similar

to previous reports [23-25], and regardless of urine contamination, EEJ-recovered sperm samples maintained greater viability for cryopreservation.

While there were no differences in oocyte cleavage rate or sperm quality parameters post-thaw with either cryopreservation method for either species, post-thaw sperm quality was significantly affected over time with significant declines in acrosomal integrity, percent motility, and forward progression. These declines increase concern for sperm viability and longevity within the female reproductive tract, possibly reducing the likelihood of successful sperm capacitation, fertilization, and embryo development, which are essential factors for successful reproduction [26-31]. For bobcats, previous studies have examined straw cryopreservation of samples collected by EEJ, using egg-yolk based cryomedium [32] that increases the risk of bacterial contamination, raises regulatory concerns, and hinders international collaboration and movement of samples. During this study, soy-based medium was effective for cryopreservation of bobcat spermatozoa, with the added benefit of being free of any animal-based proteins. While fertilization in vitro was successful for both species using all methods employed in this study, the assessment of frozen-thawed semen in-vivo was only examined in ocelots.

Lastly, laparoscopic oviductal artificial insemination was used to help determine the in vivo viability of frozen-thawed sperm samples sourced from free-ranging male ocelots. This technique allows the utilization of reduced sperm numbers [33-34] and/or sperm samples of diminished quality [34, 35-37] by depositing the sperm near the site of fertilization [38]. With the first three attempts, using a combination of sperm samples collected by catheterization or post-mortem and frozen by ultra-rapid freezing or straw freezing, there were no pregnancies. Two additional procedures were conducted using a combination of sperm collected by electroejaculation and frozen by straw freezing; however, those procedures also did not result in any pregnancies. All females responded to our ovarian synchronization protocol and had normal corpora lutea and non-pregnant luteal phases suggesting the combination of oral progestin, eCG and pLH to be sufficient for use in timed-LO-AI procedures, similar to previous reports using this protocol [33, 39]. In contrast, our pre-freeze seminal traits were sub-optimal compared to human-managed ocelots [23-24, 40] and post-thaw parameters declined substantially prior to AI. We suspect this decline in seminal quality combined with cryopreservation damage decreased the likelihood of successful fertilization and pregnancies.

While no specific level or percentage of inbreeding compromising health is defined, genetic homozygosity is not necessarily detrimental if there is no consequence to immune fitness or overall health [41]. On the contrary, low genetic diversity can have a significant effect on disease susceptibility and offspring survival, ultimately affecting the overall survival of the population [10, 42-44]. Furthermore, inbreeding has been shown to affect reproductive success by producing smaller litter sizes [45-46], decreases in offspring quality [47-49], lower survival rates [46-50], and declines in semen quality [11-14, 16, 47, 51-54]. While our populations did not demonstrate declines in general health, they did exhibit possible impacts to their reproductive health.

Overall, sperm samples from free-ranging ocelots in southern Texas were of decreased quality compared to human-managed populations suggesting a decline in reproductive health of these populations possibly associated with lower genetic diversity. While bobcats exhibited low sperm numbers, similar to other species within the same genus, they also exhibited signs of inbreeding (cryptorchidism and a persistent penile frenulum) suggesting bobcats in southern Texas may be affected by small populations sizes and fragmented landscape, similar to ocelots. Use of EEJ and straw cryopreservation was the most successful combination for free-ranging ocelots in this study and allowed the recovery of viable sperm samples despite urine contamination. For bobcats, UC and ultra-rapid freezing proved to be an effective combination for collection and cryopreservation of spermatozoa in a field-setting; however, the investigation into alternative methods could prove useful for the collection of sperm samples of higher quality and for improving cryopreservation techniques. In vivo viability of wild Texas ocelot sperm samples were assessed with LO-AI, but thus far, have not produced pregnancies. This may require the use of higher sperm numbers, a lower number of higher quality sperm using selection processes [36, 54-55], and/or the combination of natural estrous females or fresh sperm for LO-AI procedures. Additionally, in-vivo viability of frozen semen would need to be further evaluated for bobcats. Many wild felid populations are challenged by population declines due to genetic restriction; accordingly, incorporation of these technologies into population management, if proven successful, could support conservation and recovery of felid species on a global scale.

## References

- [1] A.T. Cain, V.R. Tuovila, D.G. Hewitt, M.E. Tewes. Effects of a highway and mitigation projects on bobcats in Southern Texas. *Biol Conserv.* 114:2 (2003) 189–197.  
[https://doi.org/10.1016/S0006-3207\(03\)00023-5](https://doi.org/10.1016/S0006-3207(03)00023-5)
- [2] J.E. Janecka, M.E. Tewes, I.A. Davis, A.M. Haines, A. Caso, T.L. Blankenship, R.L. Honeycutt. Genetic differences in the response to landscape fragmentation by a habitat generalist, the bobcat, and a habitat specialist, the ocelot. *Conserv Genet.* 17:5 (2016) 1093–1108. <https://doi.org/10.1007/s10592-016-0846-1>
- [3] A. Paviolo, P. Crawshaw, A. Caso, T. de Oliveira, C.A. Lopez-Gonzalez, M. Kelly, C. De Angelo, E. Payan. *Leopardus pardalis* (errata version published in 2016). *The IUCN Red List of Threatened Species* (2015):e.T11509A97212355. Accessed on 06 January 2022.  
<https://dx.doi.org/10.2305/IUCN.UK.2015-4.RLTS.T11509A50653476.en>.
- [4] A.M. Haines, M.E. Tewes, L.L. Laack, W.E. Grant, J. Young. Evaluating recovery strategies for an ocelot (*Leopardus pardalis*) population in the united states. *Biol Conserv.* 126:4 (2005) 512-522. <https://doi.org/10.1016/j.biocon.2005.06.032>
- [5] J.E. Janečka, M.E. Tewes, L.L. Laack, A. Caso, L.I. Grassman Jr, A.M. Haines, D.B. Shindle, B.W. Davis, W.J. Murphy, R.L. Honeycutt. Reduced genetic diversity and isolation of remnant ocelot populations occupying a severely fragmented landscape in southern Texas. *Anim Conserv.* 14:6 (2011) 608-619. <https://doi-org.utk.idm.oclc.org/10.1111/j.1469-1795.2011.00475.x>
- [6] D. Charlesworth, J.H. Willis. The genetics of inbreeding depression. *Nature Reviews. Genet.* 10:11 (2009) 783–796. <https://doi.org/10.1038/nrg2664>
- [7] P.M. Brock, S.J. Goodman, A.J. Hall, M. Cruz, K. Acevedo-Whitehouse. Context-dependent associations between heterozygosity and immune variation in a wild carnivore. *BMC Evol Biol.* 15:241 (2015) 242–242. <https://doi.org/10.1186/s12862-015-0519-6>
- [8] D.W. Coltman, J.G. Pilkington, J.A. Smith, J.M. Pemberton. Parasite-mediated selection against Inbred Soay sheep in a free-living island population. *Evol.* 53:4 (1999) 1259-1267.

- [9] M. Hasselgren, K. Norén. Inbreeding in natural mammal populations: historical perspectives and future challenges. *Mam Rev.* 49:4 (2019) 369–383. <https://doi.org/10.1111/mam.12169>
- [10] D. Spielman, B.W. Brook, D.A. Briscoe, R. Frankham. Does Inbreeding and Loss of Genetic Diversity Decrease Disease Resistance? *Conserv Genet.* 5:4 (2004) 439–448. <https://doi.org/10.1023/B:COGE.0000041030.76598.cd>
- [11] D.E. Wildt, M. Bush, J.G. Howard, S.J. O'Brien, D. Meltzer, A. Van Dyk, H. Ebedes, D.J. Brand. Unique seminal quality in the South African cheetah and a comparative evaluation in the domestic cat. *Biol Reprod.* 29: 4 (1983) 1019-1025. <https://doi.org/10.1095/biolreprod29.4.1019>
- [12] D.E Wildt, S.J. O'Brien, J.G. Howard, T.M. Caro, M.E. Roelke, M. Bush. Similarity in ejaculate-endocrine characteristics in captive versus free-ranging cheetahs of two subspecies. *Biol Reprod.* 36:2 (1987) 351. <https://doi.org/10.1095/biolreprod36.2.351>
- [13] D.E. Wildt, M. Bush, K.L. Goodrowe, C. Packer, A.E. Pusey, J.L. Brown, P. Joslin, S.J. O'Brien. Reproductive and genetic consequences of founding isolated lion populations. *Nature.* 329:6137 (1987) 328. <https://dx.doi.org/10.1038%2F329328a0>
- [14] D.E. Wildt, L.G. Phillips, L.G. Simmons, P.K. Chakraborty, J.L. Brown, J.G. Howard. A comparative analysis of ejaculate and hormonal characteristics of the captive male cheetah, tiger, leopard and puma. *Biol Reprod.* 38 (1988) 245-255. <https://doi.org/10.1095/biolreprod38.2.245>
- [15] K.V. Fanson, N.C. Wielebnowski, T.M. Shenk, W.J. Jakubas, J.R. Squires, J.R. Lucas. Patterns of testicular activity in captive and wild Canada lynx (*Lynx canadensis*). *Gen Comp Endocrin.* 169:3 (2010) 210-216. <https://doi.org/10.1016/j.ygcen.2010.09.001>
- [16] M.E. Roelke, J.S. Martenson, S.J. O'Brien. The consequences of demographic reduction and genetic depletion in the endangered Florida panther. *Curr Biol.* 3 (1993) 340-350. [https://doi.org/10.1016/0960-9822\(93\)90197-v](https://doi.org/10.1016/0960-9822(93)90197-v)
- [17] R. González, A. Moresco, A. Miller, H. Bateman, L. Vansandt, D. Dembiec, A. Ista, W.F. Swanson. Assessment of semen traits in servals (*Leptailurus serval*) and Canada lynx (*Lynx canadensis*). *Reprod Fert Dev.* 31 (2018) 1:176-177. <https://doi.org/10.1071/RDv31n1Ab101>
- [18] S.E. Romagnoli. Canine cryptorchidism. *Vet Clin N Am Small Anim Pratt.* (1991) 535-544.

- [19] M. Burns, M.N. Fraser (Eds): Genetics of the Dog. Edinburgh: Oliver and Boyd; (1964).
- [20] J.H. Claxton, N.T.M. Yeates. The inheritance of cryptorchidism in a small, crossbred flock of sheep. *J Hered.* 63 (1972) 141-144. <https://doi.org/10.1093/oxfordjournals.jhered.a108254>
- [21] H.C. McPhee, S.S. Buckley. Inheritance of cryptorchidism in Swine. *J Hered.* 25 (1934) 295-303. <https://doi.org/10.1093/oxfordjournals.jhered.a103951>
- [22] S.J. Kogan. Clinical Pediatric Urology, 2nd edn. New York: Saunders. (1985)
- [23] M.A. Stoops, J.B. Bond, H.L. Bateman, M.K. Campbell, G.P. Levens, T.R. Bowsher, S.T. Ferrell, W.F. Swanson. Comparison of different sperm cryopreservation procedures on post-thaw quality and heterologous *in vitro* fertilization success in the ocelot (*Leopardus pardalis*). *Reprod Fertil Dev.* 19 (2007) 685-694. <https://doi.org/10.1071/RD06078>
- [24] W.F. Swanson, L.M. Vansandt, S. Citino, R.S. Larsen, G.A. Cole, A. Moresco. Addressing the challenge of do-it-ourself (DIY) semen banking in wild felids. *Proc Ann Meet Amer Assoc Zoo Vet.* (2017) 81-82
- [25] R.N. Morais, R.G. Mucciolo, M.L.F. Gomes, O. Lacerda, W. Moraes, N. Moreira, L.H. Graham, W.F. Swanson, J.L. Brown. Seasonal analysis of semen characteristics, serum testosterone and fecal androgens in the ocelot (*Leopardus pardalis*), margay (*L. wiedii*) and tigrina (*L. tigrinus*). *Therio.* 57:8 (2002) 2027-2041. [https://doi.org/10.1016/s0093-691x\(02\)00707-0](https://doi.org/10.1016/s0093-691x(02)00707-0)
- [26] R. Yanagimachi. Mammalian fertilization, In: E. Knobil, J.D. Neill (Eds.), The Physiology of Reproduction, Raven Press, NY. (1994) 189-317.
- [27] C.D. Thaler, R.A. Cardullo. The initial molecular interaction between mouse sperm and the zona pellucida is a complex binding event. *J Biol Chem.* 271 (1996) 23289-23297. <https://doi.org/10.1074/jbc.271.38.23289>
- [28] E. Töpfer-Petersen, A.M. Petrounkina, M. Ekhlesi-Hundrieser. Oocyte-sperm interactions. *Anim Reprod Sci.* 60–61 (2000) 653– 62. [https://doi.org/10.1016/s0378-4320\(00\)00128-7](https://doi.org/10.1016/s0378-4320(00)00128-7)
- [29] J.G. Howard. Semen collection and analysis in carnivores. In: Fowler ME, editor. Zoo and Wild Animal Medicine, Vol. 3. WB Saunders Co. (1993) 390–8.

- [30] T. Lengwinat, S. Blottner. In vitro fertilization of follicular oocytes of domestic cat using fresh and cryopreserved epididymal spermatozoa. *Anim Reprod Sci.* 35 (1994) 291–301. [https://doi.org/10.1016/0378-4320\(94\)90044-2](https://doi.org/10.1016/0378-4320(94)90044-2)
- [31] G.C. Luvoni, E. Kalchschmidt, G. Marinoni. Conservation of feline semen. Part II: cold-induced damages on spermatozoal fertilizing ability. *J Feline Med Surg*, 5 (2003) 257–63. [https://doi.org/10.1016/s1098-612x\(03\)00030-5](https://doi.org/10.1016/s1098-612x(03)00030-5)
- [32] N. Gañán, R. González, A. Sestelo, J.J. Garde, I. Sánchez, J.M. Aguilar, M. Gomendio, E.R.S. Roldan. Male reproductive traits, semen cryopreservation, and heterologous in vitro fertilization in the bobcat (*Lynx rufus*). *Therio.* 74 (2009) 341-352. <https://doi.org/10.1016/j.theriogenology.2009.03.002>
- [33] V.A. Conforti, H.L. Bateman, M.M. Schook, J. Newsom, L.A. Lyons, R.A. Grahn, J.A. Deddens, W.F. Swanson. Laparoscopic oviductal artificial insemination improves pregnancy success in exogenous gonadotropin-treated domestic cats as a model for endangered felids. *Biol Reprod.* 89 (2013) 1-9. <https://doi.org/10.1095/biolreprod.112.105353>
- [34] C.A. Lambo, R.Z. Grahn, L.A. Lyons, H.L. Bateman, J. Newsom, W.F. Swanson. Comparative fertility of freshly collected vs frozen-thawed semen with laparoscopic oviductal artificial insemination in domestic cats. *Reprod Domest Anim.* 47 (2012) 284-288. <https://doi.org/10.1111/rda.12038>
- [35] B.S. Pukazhenthii, K. Neubauer, K. Jewgenow, J.G. Howard, D.E. Wildt. The impact and potential etiology of teratospermia in the domestic cat and its wild relatives. *Therio.* 66 (2006) 112-121. <https://doi.org/10.1016/j.theriogenology.2006.03.020>
- [36] W.F. Swanson. Practical application of laparoscopic oviductal artificial insemination for the propagation of domestic cats and wild felids. *Reprod Fertil Dev.* 31 (2019) 27-39. <https://doi.org/10.1071/rd18350>
- [37] P.F. Watson. The causes of reduced fertility with cryopreserved semen. *Anim Reprod Sci.* 60-61 (2000) 481-492. [https://doi.org/10.1016/s0378-4320\(00\)00099-3](https://doi.org/10.1016/s0378-4320(00)00099-3)
- [38] P. Coy, F.A. Garcia-Vazquez, P.E. Visconti, M. Aviles. Roles of the oviduct in mammalian fertilization. *Reprod.* 144 (2012) 649-660. <https://dx.doi.org/10.1530%2FREP-12-0279>

- [39] W.F. Swanson, J.G. Howard, T.L. Roth, J.L. Brown, T. Alvarado, M. Burton, D. Starnes, D.E. Wildt. Responsiveness of ovaries to exogenous gonadotropins and laparoscopic artificial insemination with frozen-thawed spermatozoa in ocelots (*Felis pardalis*). *J Reprod Fertil.* 106 (1996) 87-94. <https://doi.org/10.1530/jrf.0.1060087>
- [40] W.F. Swanson, H.L. Bateman, L.M. Vansandt. Urethral catheterization and sperm vitrification for simplified semen banking in felids. *Reprod Domest Anim.* 52:2 (2016) 255-260. <https://doi.org/10.1111/rda.12863>
- [41] J.S. Bell. Pedigree Analysis, and How Breeding Decisions Affect Genes. Tufts' Canine and Feline Breeding and Genetics Conference. (2003) <https://www.vin.com/apputil/content/defaultadv1.aspx?pId=11165&meta=generic&id=3848663>
- [42] K. Belov. The role of the Major histocompatibility complex in the spread of contagious cancers. *Mamm Genome.* 22 (2011) 83–90. <https://doi.org/10.1007/s00335-010-9294-2>
- [43] J. Radwan, A. Biedrzycka, W. Babik. Does reduced MHC diversity decrease viability of vertebrate populations? *Biol Conserv.* 143 (2010) 537–544. <https://dx.doi.org/10.1016%2Fj.biocon.2009.07.026>
- [44] C. Darwin. On the Origin of Species by Means of Natural Selection; John Murray: London, UK. (1859).
- [45] O. Ala-Honkola, L. Laine, N. Pekkala, J.S. Kotiaho, T. Honkola, M. Puurtinen. Males benefit from mating with outbred females in *Drosophila littoralis*: Male choice for female genetic quality? *Ethology.* 121 (2015) 577–585. <https://doi.org/10.1111/eth.12369>
- [46] E.I.K. Vitikainen, C. Haag-Liautard, L. Sundström. Natal dispersal, mating patterns, and inbreeding in the ant. *Formica Exsecta Am Nat.* 186 (2015) 716–727. <https://doi.org/10.1086/683799>
- [47] C. Asa, P. Miller, M. Agnew, J.A.R. Rebolledo, S.L. Lindsey, M. Callahan, K. Bauman. Relationship of inbreeding with sperm quality and reproductive success in Mexican gray wolves. *Anim Conserv.* 10 (2007) 326–331. <https://doi.org/10.1111/j.1469-1795.2007.00116.x>
- [48] K. Ralls, J.D. Ballou, A. Templeton. Estimates of lethal equivalents and the cost of inbreeding in mammals. *Conserv Biol.* 2 (1988) 185–193



- [49] L. Laikre, N. Ryman. Inbreeding depression in a captive wolf (*Canis lupus*). *Conserv Biol.* 5: (1991) 33–40. <https://www.jstor.org/stable/2386336>
- [50] C.A. Walling, D.H. Nussey, A. Morris, T.H. Clutton-Brock, L.E.B. Kruuk, J.M. Pemberton. Inbreeding depression in red deer calves. *BMC Evol Biol.* 11 (2011) 318. <https://dx.doi.org/10.1186%2F1471-2148-11-318>
- [51] M.N. Erofeeva, G.S. Alekseeva, P.A. Sorokin, S.V. Naidenko. Effect of the number of mating partners and sperm quality on reproductive success in the domestic cat (*Felis catus*). *Biol Bull.* 45 (2018) 756–765. <http://dx.doi.org/10.1134/S1062359018070063>
- [52] K. Neubauer, K. Jewgenow, S. Blottner, D.E. Wildt, B.S. Pukazhenti. Quantity rather than quality in teratospermic males: A histomorphometric and flow cytometric evaluation of spermatogenesis in the domestic cat (*Felis catus*). *Biol Reprod.* 71 (2004) 1524–1571. <https://doi.org/10.1095/biolreprod.104.031062>
- [53] S.J. O'Brien, D.E. Wildt, D. Goldman, C.R. Merrill, M. Bush. The cheetah is depauperate in genetic variation. *Sci.* 221 (1985) 459–462. <https://doi.org/10.1126/science.221.4609.459>
- [54] J.G. Howard, J.L. Brown, M. Bush, D.E. Wildt. Teratospermic and normospermic domestic cats: ejaculate traits, pituitarygonadal hormones, and improvement of spermatozoal motility and morphology after swim-up processing. *J Androl.* 11 (1990) 204-215. PMID: 2384342
- [55] A.E. Crosier, J.N. Henghali, J.G. Howard, B.S. Pukazhenti, K.A. Terrell, L.L. Marker, D.E. Wildt. Improved quality of cryopreserved cheetah (*Acinonyx jubatus*) spermatozoa after centrifugation through Accudenz. *J Androl.* 30 (2009) 298-308. <https://doi.org/10.2164/jandrol.108.006239>

## **Vita**

Ashley Reeves graduated with a Bachelor of Science in Biology with specialization in pre-veterinary sciences from Mississippi State University in 2014. She worked as a veterinary surgical and technical assistant before pursuing her Doctor of Veterinary Medicine (DVM) degree in 2015 at the University of Tennessee College of Veterinary Medicine where she completed her degree in 2019. While at the University of Tennessee, she began her dual-degree, DVM-PhD program in 2017 and continued to pursue this degree from 2019 to 2022.